

Lingua Villosa Nigra Associada ao Uso de Cigarro Electrónico



Lingua Villosa Nigra Associated with the Use of Electronic Cigarette

Helder FARINHA¹, Vera MARTINS¹
Acta Med Port 2014 xxx-xxx;27(x):xxx-xxx

Keywords: Smoking; Tobacco Products; Tongue, Hairy.

Palavras-chave: Hábito de Fumar; Língua Pilosa; Produtos do Tabaco.

A 66-year old female patient presented to her family physician an asymptomatic black discoloration of the tongue she noted that day (Fig. 1). There was no other sign associated. The case was presented to another family physician and the diagnosis of *lingua villosa nigra*¹⁻⁵ was established. This patient was a hard smoker and coffee drinker, with hypertension and history of depression. She had stopped tobacco smoking and initiated electronic cigarette a few weeks before. After that, when she stopped using the electronic cigarette and started tobacco cigarette, the lesions started disappearing spontaneously in less than one week (Fig. 2). The lesions worsened when she began using electronic cigarette again.

Lingua villosa nigra is a benign condition associated with some antibiotics, bad oral hygiene, age, smoking, alcohol and coffee drinking, cancer or HIV patients.¹⁻⁴ Chromogenic pathogens (e.g., *C. albicans*) are sometimes implicated.^{1-3,5} We did not found any previously relationship with electronic cigarette reported.

REFERENCES

1. Yan P, Mistry N, Au S. Dermacase. Can you identify this condition? Black hairy tongue. *Can Fam Physician*. 2010;56:439-41.
2. Dimitrios S, Maria-Aikaterini P, Alexandre F, Nikolaus S. *Lingua villosa nigra*. *Intern Med*. 2012;51:1453
3. Vañó-Galván D, Jaén P. Black hairy tongue. *Cleve Clin J Med*. 2008;75:847-8.
4. Perrin E, Ota KS. Tongue lesion with sensation of fullness in the mouth. *Am Fam Physician*. 2011;83:839-40.
5. Ramsakal A, Mangat L. *Lingua villosa nigra*. *N Engl J Med*. 2007;357:2388.

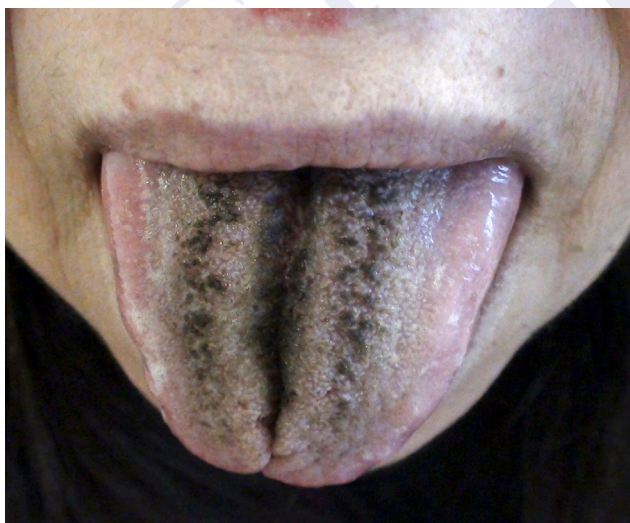

Figure 1 - *Lingua villosa nigra*

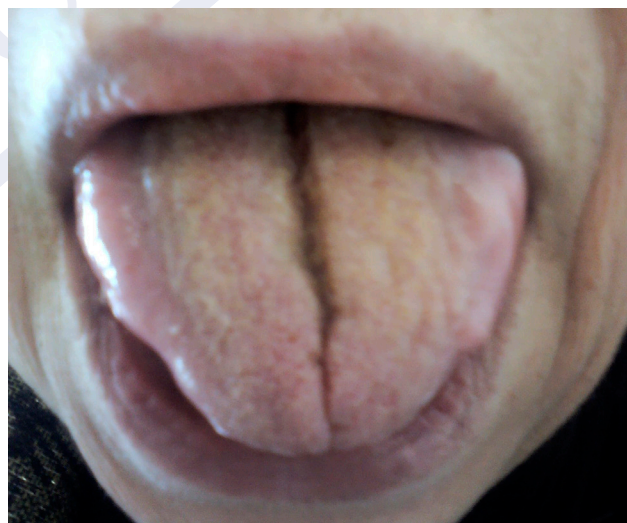


Figure 2 - Disappearance of *lingua villosa nigra* after electronic cigarette discontinuation