

## DATA CONFIDENTIALITY

The authors declare having followed the protocols in use at their working center regarding patients' data publication.

## PATIENT CONSENT

Obtained.

## REFERENCES

1. Corbett EL, Watt CJ, Walker N, Maher D, Williams BG, Raviglione MC, et al. The growing burden of tuberculosis: global trends and interactions with the HIV epidemic. *Arch Intern Med*. 2003;163:1009-21.
2. Koenig SP, Riviere C, Leger P, Joseph P, Severe P, Parker K, et al. High mortality among patients with AIDS who received a diagnosis of tuberculosis in the first 3 months of antiretroviral therapy. *Clin Infect Dis*. 2009;48:829-31.
3. Etard JF, Ndiaye I, Thierry-Mieg M, Guèye N, Guèye P, Lanièce I, et al. Mortality and causes of death in adults receiving highly active antiretroviral therapy in Senegal: a 7- year cohort study. *AIDS*. 2006;20:1181-9.
4. Direção Geral da Saúde. Programa Nacional para a Infecção VIH, SIDA e Tuberculose 2017. [consulted 2017 Dec 16]. Available from: <http://www.dgs.pt/portal-da-estatistica-da-saude/diretorio-de-informacao/diretorio-de-informacao/por-serie-845551-pdf.aspx?v=11736b14-73e6-4b34-a8e8-d22502108547>.
5. Zhang J, Fan YK, Wang P, Chen QQ, Wang G, Xu AE, et al. Cutaneous tuberculosis in China: a multicenter retrospective study of cases diagnosed between 1957 and 2013. *J Eur Acad Dermatol Venereol*. *J Eur Acad Dermatol Venereol*. 2018;32:632-8.
6. Kivanc-Altunay I, Baysal Z, Ekmekçi TR, Koslu A. Incidence of cutaneous tuberculosis in patients with organ tuberculosis. *Int J Dermatol*. 2003;42:197-200.
7. van Zyl L, du Plessis J, Viljoen J. Cutaneous tuberculosis overview and current treatment regimens. *Tuberculosis*. 2015;95:629-38.
8. Beyt BE Jr, Orbais DW, Santa Cruz DJ, Kobayashi GS, Eisen AZ, Medoff G. Cutaneous mycobacteriosis: analysis of 34 cases with a new classification of the disease. *Medicine*. 1981;60:95-109.
9. Hill MK, Sanders CV. Cutaneous tuberculosis. *Microbiol Spectr*. 2017;5.
10. Ilgazli A, Boyaci H, Basyigit I, Yildiz F. Extrapulmonary tuberculosis: clinical and epidemiologic spectrum of 636 cases. *Med Res Arch*. 2004;35:435-41.
11. Concha RM, Fich SF, Rabagliati BR, Pinto SC, Rubio LR, Navea DÓ, et al. Cutaneous tuberculosis: two cases and review. *Rev Chilena Infectol*. 2011;28:262-8.
12. Kim GW, Park HJ, Kim HS, Kim SH, Ko HC, Kim BS, et al. Delayed diagnosis of scrofuloderma misdiagnosed as a bacterial abscess. *Ann Dermatol*. 2012;24:70-3.
13. Ramos-e-Silva M, Castro MC. Mycobacterial infections. In: Bologna JL, Schaffer JV, Cerroni L. *Dermatology*. Elsevier; 2018. p. 1296-318.
14. Hsiao PF, Tzen CY, Chen HC, Su HY. Polymerase chain reaction based detection of *Mycobacterium tuberculosis* in tissues showing granulomatous inflammation without demonstrable acid-fast bacilli. *Int J Dermatol*. 2003;42:281-6.
15. Bento J, Silva AS, Rodrigues F, Duarte R. Diagnostic tools in tuberculosis. *Acta Med Port*. 2011;24:145-54.

## A Rare Case of Granulomatous Pneumonitis Due to Intravesical BCG for Bladder Cancer

### Um Caso Raro de Pneumonite Granulomatosa Secundária a Instilação Intravesical de BCG no Contexto de Neoplasia da Bexiga



Vera CLÉRIGO<sup>1</sup>, Ana CASTRO<sup>2</sup>, Teresa MOURATO<sup>2</sup>, Conceição GOMES<sup>2</sup>  
*Acta Med Port* 2019 Apr;32(4):316-320 • <https://doi.org/10.20344/amp.10250>

## ABSTRACT

Granulomatous pneumonitis is a rare complication of bacillus Calmette-Guerin immunotherapy following intravesical administration of bacillus Calmette-Guerin. The authors present an unusual case of a 67-year-old man who developed mild and non-specific symptoms, following intravesical bacillus Calmette-Guerin instillations. Examinations revealed features of miliary tuberculosis and granuloma suggestive of mycobacterial infection. Anti-tuberculosis treatment resulted in a remarkable improvement in his symptoms and gradually upgrading of radiological appearance. The symptoms were less severe than some others described but this case provides evidence that, even in some cases, specific treatment may be necessary. We highlight the importance of recognizing miliary *Mycobacterium bovis* as a probable complication of bacillus Calmette-Guerin immunotherapy. The clinical disease course can be mild, despite extensive bilateral miliary nodules on primary presentation.

Keywords: BCG Vaccine; Granuloma/chemically induced; Pneumonia/chemically induced; Urinary Bladder Neoplasms/drug therapy

## RESUMO

A pneumonite granulomatosa é uma complicação rara da imunoterapia com *bacillus* Calmette-Guerin após administração intravesical de *bacillus* Calmette-Guerin. Os autores apresentam um caso incomum de um homem de 67 anos de idade que desenvolveu sintomas ligeiros e inespecíficos, após instilações de *bacillus* Calmette-Guerin intravesical. Os exames revelaram características da

1. Pulmonology – Thorax Department. Centro Hospitalar Lisboa Norte. Lisboa, Portugal.

2. Pulmonary Diagnosis Center Dr. Ribeiro Sanches. Lisboa, Portugal.

✉ Autor correspondente: Vera Clérigo. [vclerigo21@gmail.com](mailto:vclerigo21@gmail.com)

Recebido: 15 de janeiro de 2018 - Aceite: 17 de agosto de 2018 | Copyright © Ordem dos Médicos 2019



tuberculose miliar e granuloma sugestivo de infeção por micobactérias. O tratamento antibacilar resultou numa melhoria notável na sua sintomatologia e na melhoria progressiva das alterações radiológicas. Os sintomas foram de menor gravidade comparativamente a outros casos relatados na literatura, mas este caso fornece evidências de que, mesmo em algumas situações, um tratamento específico pode ser necessário. Destacamos a importância de reconhecer o *Mycobacterium bovis* disseminado como uma provável complicação da imunoterapia a *bacillus* Calmette-Guerin. O curso clínico da doença pode ser ligeiro, apesar da extensa disseminação miliar bilateral na apresentação primária.

**Palavras-chave:** Granuloma/induzido quimicamente; Neoplasias da Bexiga Urinária/tratamento; Pneumonia/induzida quimicamente; Vacina BCG

## INTRODUCTION

Urinary bladder cancer is the most frequent urinary system malignancy, being ninth in worldwide cancer incidence.<sup>1</sup> Intravesical administration of bacillus Calmette-Guérin (BCG), a live attenuated strain of *Mycobacterium bovis*, is the cornerstone of adjunctive therapy for superficial bladder cancer.<sup>2</sup>

BCG immunotherapy is typically well tolerated due to low virulence in immunocompetent patients,<sup>3</sup> although local and systemic complications may occur. Severe adverse symptoms are uncommon. Additionally, disseminated BCG infections that present as granulomatous pneumonitis or hepatitis are quite rare.

We report a case of an immunocompetent adult patient with a history of urinary bladder cancer that presented with disseminated BCG pneumonitis, after intravesical BCG immunotherapy, with mild and non-specific symptoms, even though having a thoracic computed tomography (CT) scan with extensive bilateral miliary nodules on his primary

appearance.

## CASE REPORT

A 67-year-old male was diagnosed with urinary bladder carcinoma, and was placed on intravesical BCG immunotherapy. Six days after the sixth BCG instillation therapy, the patient exhibited a continuous low-grade fever, with an isolated peak of high-grade fever. He was treated with a short-term course of ciprofloxacin without improvement due to suspicion of complicated urinary tract infection. Due to the persistence of symptoms for a month, the patient was referred to the regional Pulmonology Diagnosis Center. A physical examination indicated fine inspiratory crackles in both lungs. Laboratory data were as follows: white blood cell count, 5100/ $\mu$ L (neutrophils, 53.4%; lymphocytes, 33.0%); haemoglobin, 12.8 g/dL; platelet count,  $23.4 \times 10^4$ / $\mu$ L; C-reactive protein (PCR), 0.8 mg/dL. Chest radiography revealed bilateral diffuse reticulonodular infiltrates.

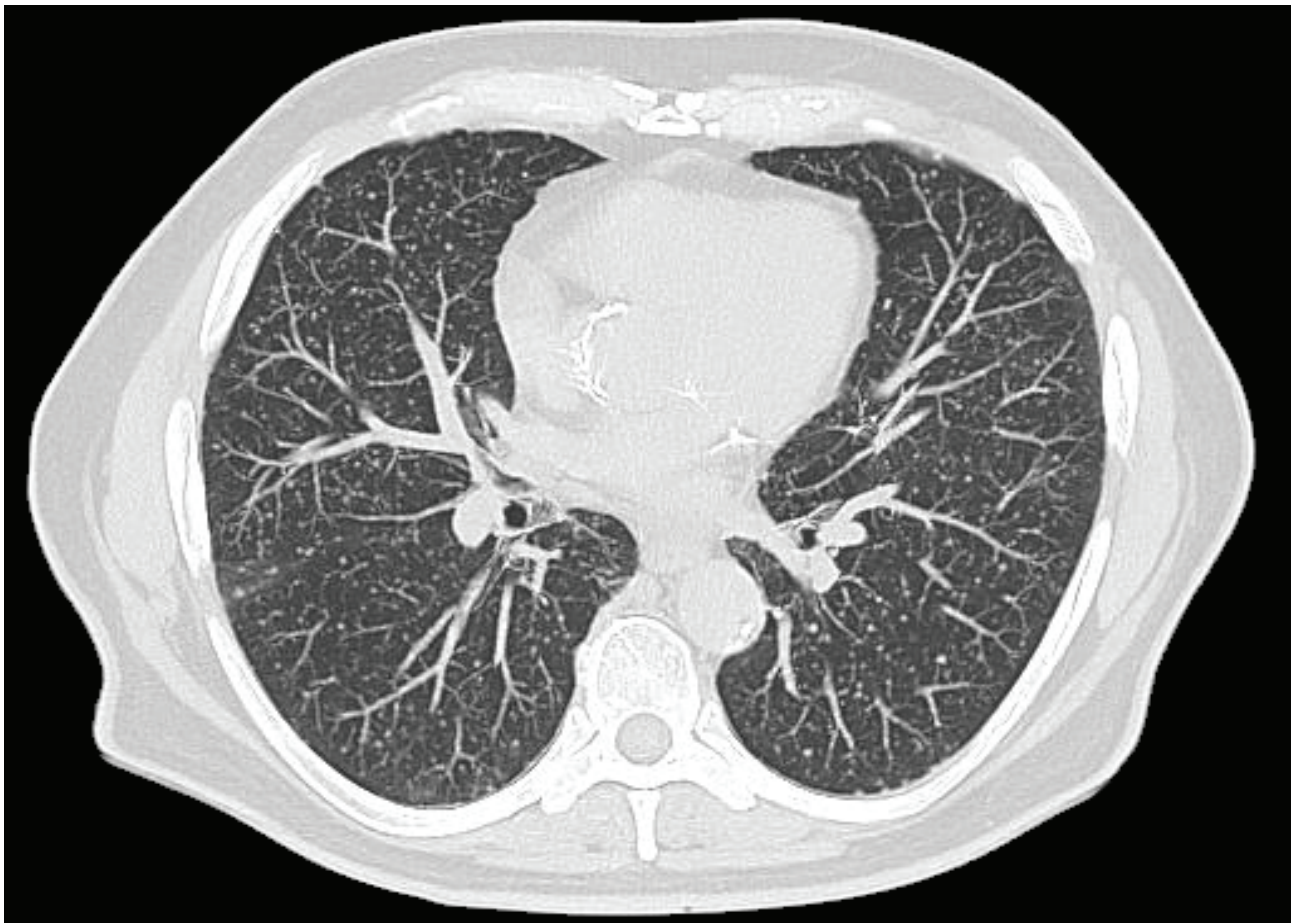


Figure 1 – Computed tomography scan showing pulmonary nodules in a miliary pattern

He was subsequently subjected to a thoracic CT that demonstrated miliary dissemination with pulmonary micronodulation (Fig. 1).

Additionally, he underwent a flexible bronchoscopy with bronchoalveolar lavage fluid (BALF) and transbronchial biopsy collection. Flow cytometric analysis of the BALF revealed a predominance of lymphocytes (53%). The Ziehl-Neelsen staining and real-time PCR performed on BALF and lung tissue specimens were negative. The lung tissue histopathological examination obtained by transbronchial biopsy revealed epithelioid granulomas in the absence of caseous necrosis and Langerhans giant cells. Furthermore, HIV1/2 antigen/antibody screening was negative. Blood, urine and sputum cultures were also negative for mycobacteria, as well as for common bacteria and fungi.

According to the patient's history of recent intravesical BCG treatment, disseminated BCG pneumonitis was assumed and BCG immunotherapy was discontinued. Anti-tuberculous treatment was added (isoniazid 5 mg/kg/day, rifampicin 10 mg/kg/day, ethambutol 20 mg/kg/day) as well as a short-course of oral prednisolone (0.5 mg/kg/day). Clinical symptoms and abnormal findings on thoracic CT scan improved after 2 months of treatment. Prednisolone was tapered to complete withdrawal in a two-month period, with no clinical relapse.

The patient continued receiving anti-tuberculous therapy with no reported problems, under the supervision of his physicians that included isoniazid and rifampicin for 12 months, with a two-month intensive phase including ethambutol. The treatment period was extended for a total of 12 months, due to slow imaging improvement suggestive of active disease at nine months of treatment. Chest CT at 12-month treatment showed considerable improvement with resolution of majority of the intrapulmonary nodules and calcification of the remaining (Fig. 2).

## DISCUSSION

The BCG mechanism that leads to complications is not entirely acknowledged, and neither is its mechanism in cancer as an immunotherapeutic agent.<sup>4</sup> Furthermore, it is controversial whether complications associated with intravesical BCG are an active infection or a hypersensitivity reaction.

Local or systemic complications of intravesical BCG instillations can arise. Mild adverse effects such as low-grade fever, dysuria and urinary frequency, develop in 3% – 5% of patients.<sup>5</sup> The most severe complications concern disseminated infection, being sepsis the most fulminant display, but organ infection can also occur. Distant organ complications are even less common and can manifest, as

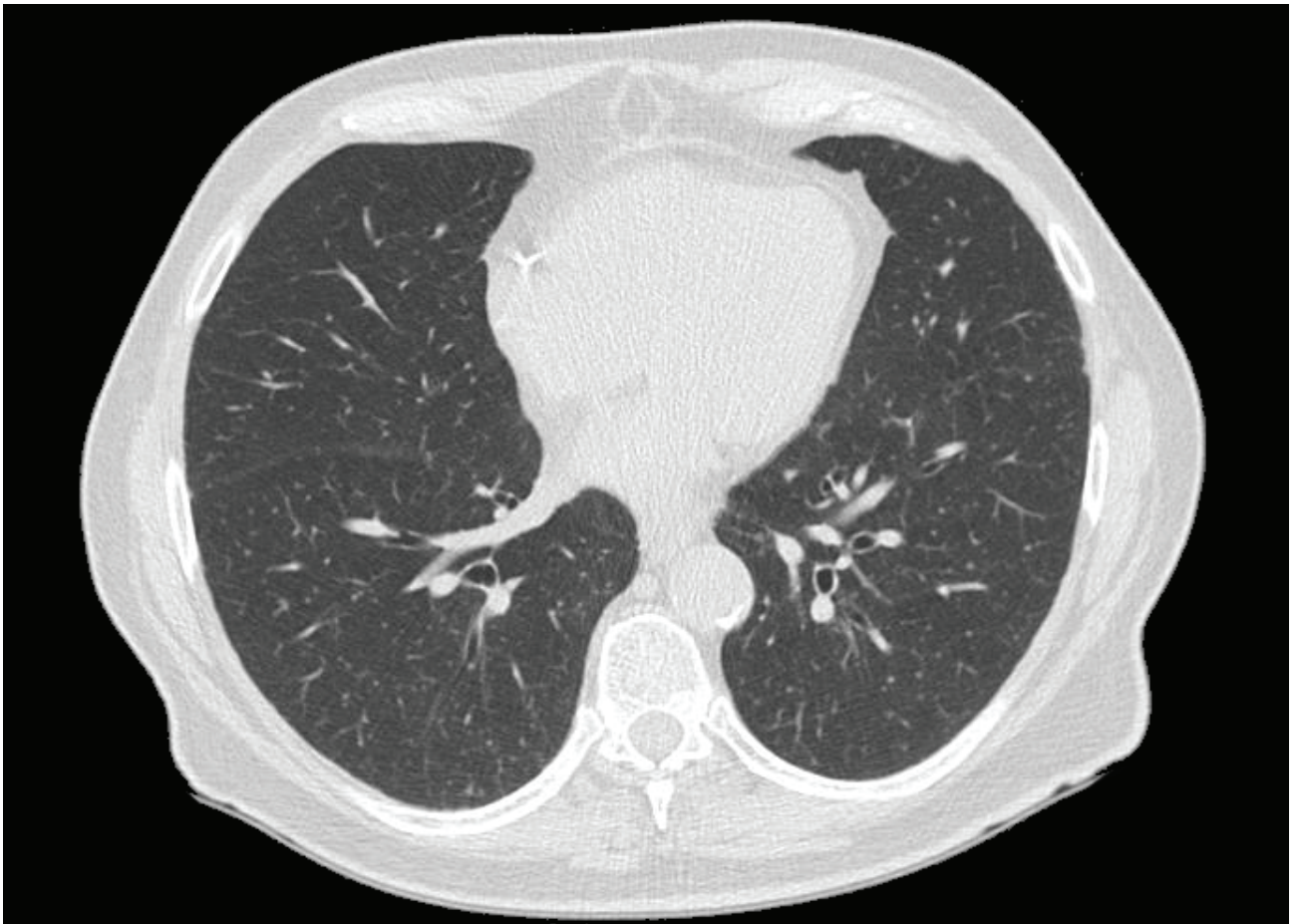


Figure 2 – Axial image of repeat chest computed tomography scans performed 12 months after initiation of anti-tuberculosis medications: showing further improvement with resolution and calcification of many of the intrapulmonary nodules

hepatitis, pneumonitis, osteomyelitis and arthritis, for example.<sup>6</sup> In the largest retrospective study reported to date, dissemination as pneumonitis and/or hepatitis occurred in 0.7% of over 2000 patients.<sup>3</sup>

In some patients with disseminated BCG infection, pneumonitis is characterized by an interstitial or miliary nodular pattern on chest radiography and CT scanning, most frequently present in patients with sepsis.<sup>7,8</sup> However, relatively asymptomatic patients with only mild symptoms or subclinical cases are even rarer and have been described.<sup>9</sup> Chest radiograph should not be chosen over thoracic CT scanning, since it is not adequately sensitive, leading to misdiagnosis. In fact, chest radiograph failed to reveal a miliary dissemination pattern in a quarter of the cases, recognized in a thoracic CT scanning.

The approach to complications related to intravesical BCG treatment depends on their type and severity. Relapsing fever with night sweats persisting beyond 48 hours or evidence of more acute serious systemic symptoms, are usually signs of BCG infection that requires antituberculous therapy.<sup>6</sup> *M. bovis* is susceptible to most of the anti-tuberculous therapy with the exception of pyrazinamide and cycloserine, to which it is typically resistant.<sup>11</sup> *M. bovis* is quite sensitive to later-generation fluoroquinolone antibiotics. A regimen that includes isoniazid, rifampicin, ethambutol and a fluoroquinolone can be typically used for six months, but there is limited evidence to support standard recommendations for the treatment of human disease due to *M. Bovis*.<sup>12</sup> This period may be extended due to symptoms relapse or refractory disease. Adjunctive therapy with corticosteroids has shown to be effective in decreasing symptoms in cases with suspected hypersensitivity, with attentiveness during tapering due to high risk of symptom relapse and formation of granuloma.<sup>7</sup>

Several studies have been done to demonstrate effective measures in preventing the occurrence of disseminated BCG infection, such as fluoroquinolone short prophylaxis use after each BCG administration. A multicenter, randomized and prospective study<sup>13</sup> showed that ofloxacin reduced the incidence of severe local reactions and the use of anti-tuberculosis treatment. However, no cases of BCG sepsis were reported and the ability of ofloxacin to prevent more severe complications was not evaluated. Fluoroquinolone prophylaxis might reduce the antitumor activity of BCG, but no clear evidence has been found to recommend routine fluoroquinolone prophylaxis. Another study using prulifloxacin reported very comparable findings.<sup>14</sup>

It can be discussed that in this report, the patient's symptoms were caused by a hypersensitivity reaction

instead of disseminated BCG, due to the absence of acid-fast bacilli on direct microscopy and negative culture results. Nevertheless, the presence of formed granuloma in transbronchial biopsy, added to anti-tuberculous treatment that led to clinical and radiological improvement supports disseminated BCG infection as a more probable diagnosis. Additionally, the lack of identification of *M. bovis* may be related to several modifying factors, such as culture techniques, the number of organisms, and its low virulence in an immunocompetent host. The patient presented in this case had some atypical features, for instance mild non-specific symptoms as low-grade fever, despite extensive pulmonary involvement; and only anti-tuberculous treatment with corticosteroids led to clinical and radiological improvement despite a slow image upgrading.

In conclusion, we report a rare complication of intravesical BCG instillation presenting as disseminated BCG pneumonitis. This case highpoints the importance of identifying disseminated mycobacterial infection as a complication in any patient receiving intravesical BCG instillation even if there are mild and non-specific symptoms.

#### ACKNOWLEDGEMENTS

The authors thank the collaboration of all elements of the Pulmonology Diagnosis Center Dr. Ribeiro Sanches – Lisbon, Portugal.

#### PROTECTION OF HUMANS AND ANIMALS

The authors declare that the procedures were followed according to the regulations established by the Clinical Research and Ethics Committee and to the Helsinki Declaration of the World Medical Association.

#### DATA CONFIDENTIALITY

The authors declare having followed the protocols in use at their working center regarding patients' data publication.

#### PATIENT CONSENT

Obtained.

#### CONFLICTS OF INTEREST

The authors declare to have no conflict of interest directly or indirectly related to the manuscript contents.

#### FUNDING SOURCES

This research received no specific grant from any funding agency in the public, commercial, or not-for-profit sectors.

#### REFERENCES

1. Ploeg M, Aben KK, Kiemeny LA. The present and future burden of urinary bladder cancer in the world. *World J Urol.* 2009;27:289–93.
2. Alexandroff AB, Jackson AM, O'Donnell MA, James K. BCG immunotherapy of bladder cancer: 20 years on. *Lancet.* 1999;353:1689–94.
3. Lamm DL. Efficacy and safety of bacilli Calmette-Guérin immunotherapy in superficial bladder cancer. *Clin Infect Dis.* 2000;31:86–90.
4. Mitropoulos DN. Novel insights into the mechanism of action of intravesical immunomodulators. *In Vivo.* 2005;19:611.
5. Koga H, Kuroda M, Kudo S, Yamaguchi A, Usami M, Suzuki T, et al. Adverse drug reactions of intravesical bacillus Calmette-Guérin instillation and risk factors of the development of adverse drug reactions

- in superficial cancer and carcinoma in situ of the bladder. *Int J Urol*. 2005;12:145–51.
6. Delimpoura V, Samitas K, Vamvakaris I, Zervas E, Gaga M. Concurrent granulomatous hepatitis, pneumonitis and sepsis as a complication of intravesical BCG immunotherapy. *BMJ Case Rep*. 2013;2013.
  7. Elkabani M, Greene J, Vincent A, VanHook S, Sandim R. Disseminated mycobacterium bovis after intravesicular bacillus calmette-Guérin treatments for bladder cancer. *Cancer Control*. 2000;7:476-81.
  8. Mignon F, Chevrère A, Mesurolle B, El Hajam M, Morel H, Lacombe P. Miliary induced by intravesical BCG immunotherapy for carcinoma of the bladder: CT Findings. *J Radiol*. 2002;83:368-71.
  9. Choi CH, Lee SO, Smith G. Subclinical miliary Mycobacterium bovis following BCG immunotherapy for transitional cell carcinoma of the bladder. *BMJ Case Rep*. 2014; 2014.
  10. Pérez-Jacoiste Asín MA, Fernández-Ruiz M, López-Medrano F, Lumbreras C, Tejido A, San Juan R, et al. Bacillus Calmette-Guérin (BCG) infection following intravesical BCG administration as adjunctive therapy for bladder cancer: incidence, risk factors, and outcome in a single-institution series and review of the literature. *Medicine*. 2014;93:236.
  11. Durek C, Rüsç-Gerdes S, Jocham D, Böhle A. Sensitivity of BCG to modern antibiotics. *Eur Urol*. 2000;37:21-5.
  12. Lan Z, Bastos M, Menzies D. Treatment of human disease due to mycobacterium bovis: a systematic review. *Eur Respir J*. 2016;48:1500–3.
  13. Colombel M, Saint F, Chopin D, Malavaud B, Nicolas L, Rishmann P. The effect of ofloxacin on bacillus calmette-guerin induced toxicity in patients with superficial bladder cancer: results of a randomized, prospective, double-blind, placebo controlled, multicenter study. *J Urol*. 2006;176:935-9.
  14. Damiano R, De Sio M, Quarto G, Di Lorenzo G, Perdonà S, Palumbo I, et al. Short-term administration of prulifloxacin in patients with nonmuscle-invasive bladder cancer: an effective option for the prevention of bacillus Calmette-Guérin-induced toxicity? *BJU Int*. 2009;104:633-9.