

Mucosal and Periungual Telangiectasia as Signs of Systemic Disease

Telangiectasia Mucosa e Periungual como Indícios de Doença Sistémica



Ana Sofia BORGES¹, Sara CAMPOS², Ana BRASILEIRO¹
Acta Med Port 2018 Feb;31(2):133-133 • <https://doi.org/10.20344/amp.10307>

Keywords: Capillaries; Nail Diseases; Scleroderma, Systemic; Telangiectasis
Palavras-chave: Capilares; Doenças da Unha; Esclerodermia Sistémica; Telangiectasia

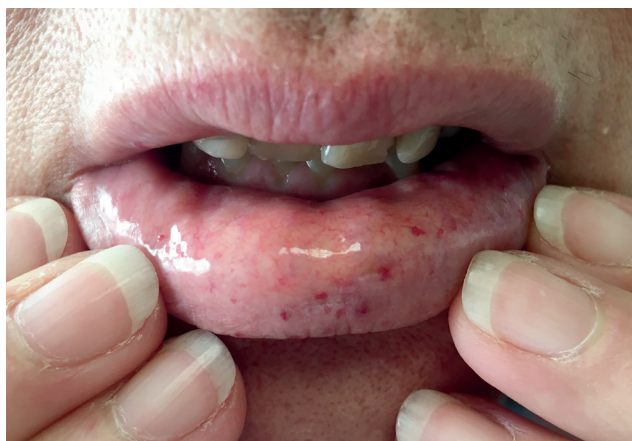

Figure 1 – Telangiectasias in periungual folds and cuticular dystrophy

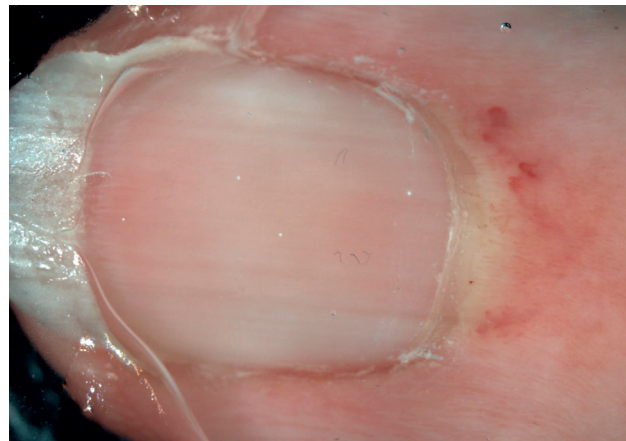


Figure 2 – Nail fold capillaroscopy revealed giant capillaries and neoangiogenesis

We report a 51-year-old woman who presented with 2-year evolving mucocutaneous telangiectasia, namely on the lower lip and periungual folds. Past medical and family history were unremarkable. On physical examination, several telangiectasia on the lower lip (Fig.1) and periungual folds were observed as well as cuticular dystrophy (Fig.2) and Raynaud phenomenon. Blood testing revealed positive antinuclear antibodies with a centromere-staining pattern and nail fold capillaroscopy revealed giant capillaries and neo-angiogenesis. No changes were observed in pulmonary function testing, endoscopy and echocardiography.

Telangiectasias are a typical feature of systemic sclerosis, mostly in localized variant, and often involve lips and palms.¹ However, they can be present in other connective tissue diseases or familial disorders as hereditary hemorrhagic telangiectasia and Peutz-Jeghers syndrome.² Nail fold capillary abnormalities, sclerodactyly and digital pitting scars are useful in supporting the diagnosis.³ The frequent internal involvement, with pulmonary disease being the leading cause of death, justifies the importance of high clinical suspicion and close monitoring of these patients.

PROTECTION OF HUMANS AND ANIMALS

The authors declare that the procedures were followed according to the regulations established by the Clinical Research and Ethics Committee and to the Helsinki Declaration of the World Medical Association.

DATA CONFIDENTIALITY

Informed consent was duly obtained from the patient.

CONFLICTS OF INTEREST

All authors report no conflict of interest.

FUNDING SOURCES

This research received no specific grant from any funding agency in the public, commercial, or not-for-profit sectors.

REFERENCES

1. Halachmi S, Gabari O, Cohen S, Koren R, Amitai DB, Lapidot M. Telangiectasis in CREST syndrome and systemic sclerosis: correlation of clinical and pathological features with response to pulsed dye laser treatment. *Lasers Med Sci.* 2014;29:137-40.
2. Grillo E, Miguel-Morrondo A, Jaén-Olasolo P. Anemia and mucocutaneous telangiectasias. *Am Fam Physician.* 2014;89:89-90.
3. Grassi W, Medico PD, Izzo F, Cervini C. Microvascular involvement in systemic sclerosis: capillaroscopic findings. *Semin Arthritis Rheum.* 2001;30:397-402.

1. Dermatology and Venereology Department. Hospital Santo António dos Capuchos. Centro Hospitalar de Lisboa Central. Lisboa. Portugal.

2. Champalimaud Foundation. Lisboa. Portugal.

✉ Autor correspondente: Ana Sofia Borges. asofiarborges@gmail.com

Recebido: 28 de janeiro de 2018 - Aceite: 06 de fevereiro de 2018 | Copyright © Ordem dos Médicos 2018

