

RADIOLOGICAL EXPLORATION OF VARICOCELE

Gianfranco D'Ottavio

Department of Surgery (Urology and Andrology Unit). St. Charles of Nancy Hospital. Rome. Italy.

SUMMARY

After a survey of the different techniques which are now employed in a radiological exploration of idiopathic varicocele, the technique of pre-operative ascending trans-scrotal venography is analysed. Radiograms of 94 venographies are presented and discussed. A classification of the normal data and anomalies which were observed with this technique is proposed. Based in such observations the use of pre-operative trans-scrotal venography is recommended as a stage of primary importance in the varicocele surgical treatment. In fact, the peculiar polymorphism of the testicular venous return and the presence of several anastomotic vessels can be considered as possible cause either of a recurrence of pathology, or of a bilateral inhibition of spermatogenesis.

The increased clinical use of radiological exploration in patients affected with idiopathic varicocele, has further explained some essential stages of this affection, which so significantly weighs on the complex andrological pathology.

Firstly, this clinical use has radiologically confirmed the primary role of the reflux from renal to spermatic vein in the pathogenesis of venous dilatation; this is a process previously conceived (Clegg 1970) on the basis of the anatomic characteristics of the confluence, on the left, of the internal spermatic vein with the renal one.

Secondly, it has pointed out the peculiar polymorphism of the testicular venous return, whose great variety represents the anatomic-functional cause of bilateral damage of spermatogenesis and, at the same time, of surgical recurrences.

Actually, there are three main techniques: retrograde selective venography, intra-operative venography (retrograde or ascending) and pre-operative ascending trans-scrotal venography.

We have here exposed a critical examination of the different techniques at our disposal taking into special account our own method and the results it led to.

MATERIAL AND METHODS

MATERIAL

We did study, between March 77 and January 79, 94 patients referred to the Urology and Andrology Unit with problems of infertility or non confirmed varicocele.

Venographic Techniques

From the methodological point of view, we can divide these techniques in: A) *Anatomic-functional techniques*, aiming at pointing out the existence of the reflux from renal to spermatic vein; B) *Anatomic-surgical techniques*, aiming at a more detailed demonstration of the anatomy of the venous spermatic system for a radical operation.

We shall come back with further details to the radicality of surgical relapses as well as to the important problem of recurrences in another paper. In this paper it's better to underline how the failures of surgery (both persistent dilatations of pampiniform plexus and real recurrences) are assuming an increased importance in the andrological literature (Comhaire and Kunnen 1976, Popelier 1973).

Anatomic-functional techniques

Retrograde selective venography

Even if it's not yet part of the clinical routine, this technique, which was standardized in 1966 by Ahlberg et al (1966), has been employed with excellent results by other Authors (Comhaire and Kunnen 1976). This method implies the percutaneous catheterization of the right femoral vein, under local anesthesia, according to Seldinger's technique. A special catheter is introduced in it up to the left renal vein under monitor control. Requesting the patient for a Valsava manoeuvre, 20 ml of 60 % Isopaque are injected, so that a visualization of the retrograde hematic flux is obtained. The first film exposures are made and 5 second later pampiniform plexus opacification is obtained.

This method proves excellent in cases of probable surgical recurrence or when, at a diagnostic stage, we want to explain, venographically, some dubious thermographic reports.

In our opinion, this technique appears to be extremely complex for a routine use: according to Cohen (1977) it involves a morbidity of 5 % and a considerable cost of execution.

Anatomic-surgical techniques

Intra-operative venography

This technique seems to meet now with the major consents (Etriby et al 1975) owing to its practicality.

This method, which was used in the past in Italy as well, assures a good visualization of the venous spermatic system, unifying, in addition, the radiological and the surgical stages.

As we can see from Fig. 1, the spermatic vein is cannulated by a Butterfly needle (in the case considered, there were two veins) and the contrast medium is injected both in the proximal and in the distal direction.

Even if it has some sure advantages, in our opinion this technique cannot be considered excellent, because it involves a considerable prolongation of surgery and it implies the correct and easy execution of radiograms; furthermore, the detection and the consequent ligation of vascular anomalies, which have been found in vasographic exploration, are strongly conditioned by the level and the extent of the cutaneous incision, chosen as inlet.

Pre-operative ascending trans-scrotal venography

We must state in advance that this is the technique we usually employ. In our clinical practice, the diagnostic stage becomes less important than the therapeutic one, also for the fact that clinical and laboratory exploration (palpation with Valsalva ma-

noeuvre, semen examination, thermography) are enough to cinch the diagnosis in most cases.

Therefore, just for pathogenetic considerations, surgical radicality becomes a necessary element for a correct therapeutical approach, aiming firstly at preventing possible recurrences involving the irreversibility of the damage of spermatogenesis.

Among the main advantages of this technique, we want to underline its easy execution joined to a total safety. It allows an excellent visualization of the whole venous system and, being pre-operative, it allows to adapt surgical inlet to possible vascular anomalies, which have been pointed out. In the end, it requires a low cost of execution.

Our method has already been pointed out in other publications (D'Ottavio et al 1978, D'Ottavio et al *in press*). Some days before surgery and even without hospitalization, we proceed, after local anesthesia at radix scroti, to the detection of an ectatic vein of the anterior pampiniform plexus through decollement manoeuvres. This detection is made easy by appropriate Valsalva manoeuvres. After finding and cannulating the vein with a Butterfly needle, 20 ml Uromiro are injected under monitor control. It's necessary to avoid cannulization of a vein of the cremasteric plexus, because this will involve some other vascular pictures.

As the opacification of the spermatic vein proceeds in the proximal direction up to the confluence with the renal vein, the most significant film exposures are made; a particular attention is payed to the existence of collateral vessels; their non-identification during surgery would be the cause of an anatomic-functional recurrence. Another important element is the visualization of the anatomic and functional ways of the renal vein junction as well as the research for a double spermatic vein, which is, also, a cause of recurrences when an incorret ligation is made.

Standardization of radiographic results

For an effective standardization of our venographic results, we deemed necessary to refer to a method of classification of the main results we found. This is reported in Table 1.

Table 1

Classification of venographic findings in subjects with idiopathic varicocele

<i>D</i> (dilatation)	D_0 = non dilatated D_1 = moderate D_2 = remarkable
<i>N</i> (number of vessels wich are seen above the iliac crest)	$N_1, N_2 \dots \dots \dots N_5 \dots \dots \dots$
<i>A</i> (relevant anastomotic systems)	A_0 = absence of relevant anastomoses A_p = pubic anastomoses A_s = sacral anastomoses A_r = connections with the right hemiscrotum A_l = lombar anastomoses A_v = various hardly classifiable anastomoses
<i>J</i> (renal-spermatic junction)	J_0 = unseen J_r = regular J_a = anomalous

RESULTS

The venographies using the pre-operative ascending trans-scrotal tecnic of the 94 patients investigated showed to be normal in 40.4 % of cases (D0, D1, D2, N1, A0, J-), and abnormal in 59.4 %. In table 2 we present the results obtained.

Table 2
Data from 94 venographies

D %	N %	A %	J %
D ₀ = 19,2	N ₁ = 55,2	A ₀ = 65,9	J- = 70,2
D ₁ = 36,2	N ₂ = 31,9	A = 34,1	J _n = 19,1
D ₂ = 44,6	N ₂ = 10,7	A _s = 8,3	J _o = 10,7
	N ₄ = 0	A ₁ = 16,6	
	N ₅ = 2,2	A ₂ = 16,6	
		A _s = 25,2	
		A _v = 33,3	

Some aspects of the pathology found are seen in Fig. 1 to 10.

The results are expressed according to our classification D-N-A-J.

Fig. 1 shows a normal spermatic vein with a regular gauge without anastomotic vessels or anomalies of number, which regularly joins the renal vein. Fig. 2 presents the typical confluence at right angles of the renal vein with the spermatic one; this is an anatomical situation, which certainly doesn't help an anterograde flux owing to hemodynamic reasons. A double portal distal spermatic vein is shown in Fig. 3; its non-identification during surgery should have surely involved a recurrence, owing to a very low ligation. Fig. 4 shows a double partial proximal spermatic vein, which would have involved a recurrence if a too high ligation was made. We also found curious, polymorphic vascular development following the main trunk of the spermatic vein (Fig. 5). We explained these reports as functional vicarious adaptations of a venous insufficiency, suggesting the canalization of alternative pathways of discharge. In Fig. 6 we can see a considerably dilated spermatic vein with a great collateral vascular development. During surgery, the ligation of five vessels has been made.

Fig. 7, 8, 9 and 10, show it is possible, for strictly anatomical reasons, to have a bilateral damage of spermatogenesis. Whatever noxa may be, which produces a spermatogenesis inhibition during varicocele, this can involve both testes just for the existence of these anastomotic vessels.

In this connection, Fig. 8 and Fig. 9 seem to be particularly significant; they respectively show antpubic and median anastomoses with visualized perivesical plexuses. Fig. 10 refers to a recurrence we had in a patient who had undergone an intervention of high spermatic vein ligation without pre-operative venography. It can well be noted, down, the previous ligation and in the top center the existence of a partly double spermatic vein, keeping on with its course towards the renal vein and causing venous insufficiency.

DISCUSSION

In 40 % of cases, we found venographies which can be considered normal from the anatomical point of view.

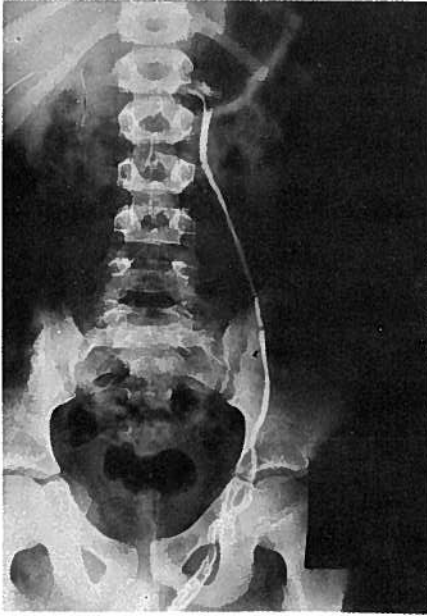


Fig. 1 — *Normal spermatic vein with regular gauge*

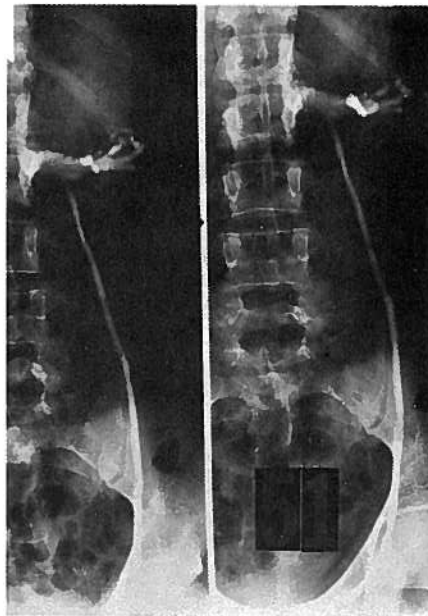


Fig. 2 — *Typical confluence at right angles of the renal vein with spermatic one*

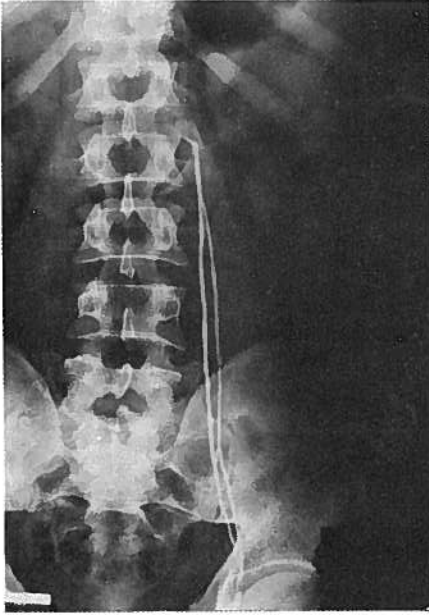
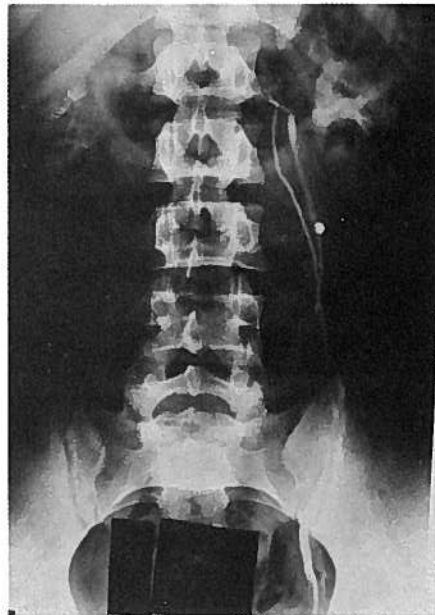

Fig. 3 — *Double portal distal spermatic vein*

Fig. 4 — *Double partial proximal spermatic vein*



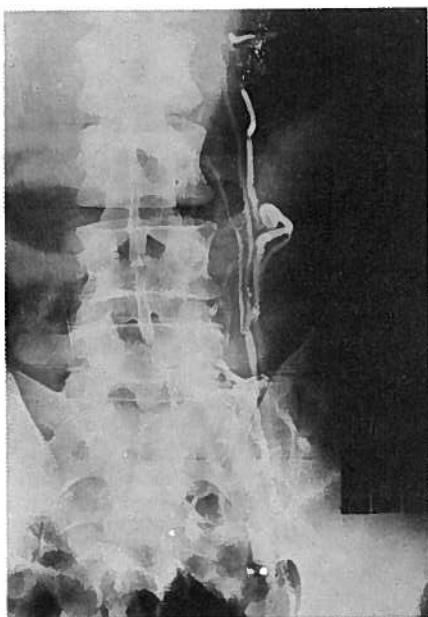
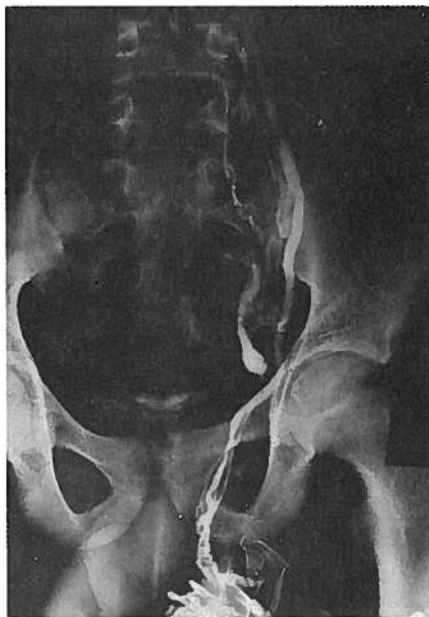

Fig. 5 — *Polymorphic vascular development following the main trunk of the spermatic vein*

Fig. 6 — *Greatly dilated spermatic vein with profuse collateral vascular development*



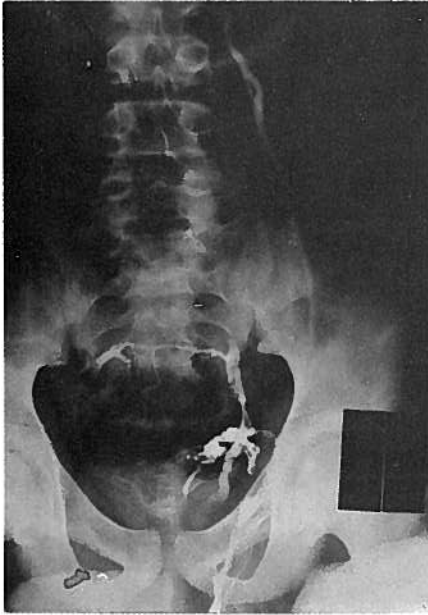

Fig. 7—This figure shows how it is possible, for strictly anatomical reasons, to have a bilateral damage of spermatogenesis

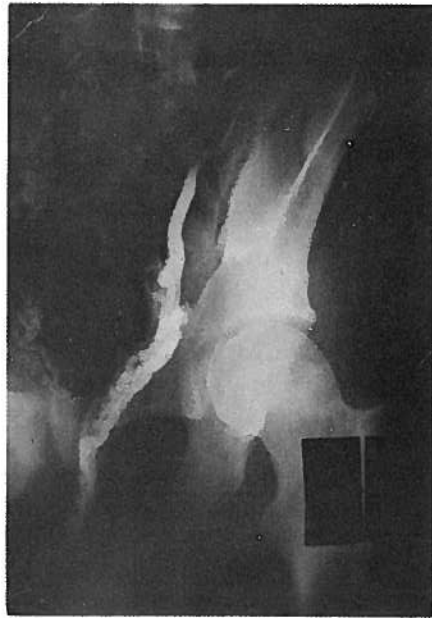


Fig. 8—Antpubic anastomoses with perivesical plexuses

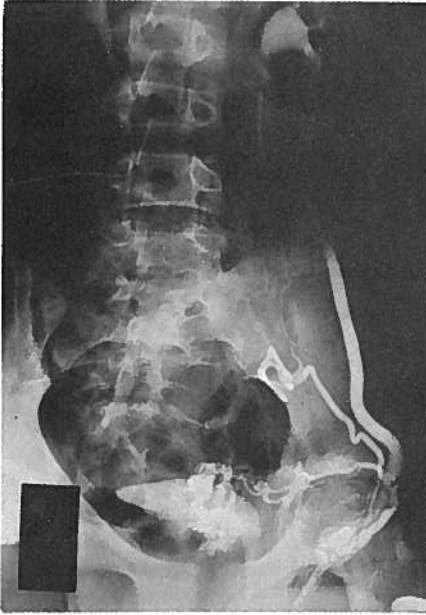

Fig. 9 — Median anastomoses with perivesical plexuses

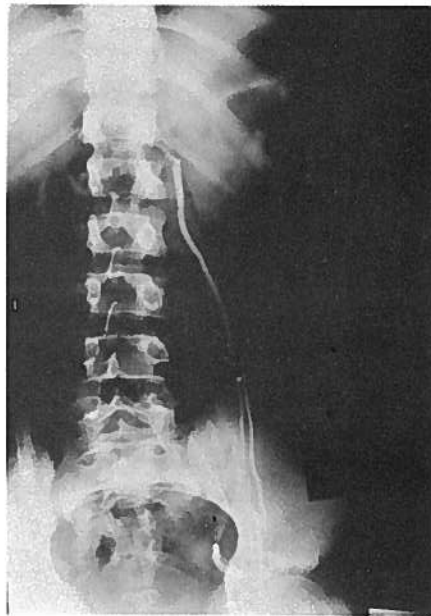


Fig. 10 — Recurrence in a patient who had undergone an intervention of high spermatic vein ligation without pre-operative venography. Note in the top center the existence of a partly double spermatic vein responsible for the venous insufficiency and, below, the previous ligation

In the remaining 60 % of cases, we registered anomalies of number, presence of significant anastomotic vessels and anomalies of the renal and spermatic veins confluence conformation. These anomalies can be all present in the same patient.

The anomalies of number, meant as the discovery of supernumerary vessels over the iliac crest, have been found in 45 % of cases, while significant anastomotic vessels in 34,1 %; 16,6 % of these cases must concern anastomoses with the right hemiscrotum, with interesting pathogenetic implications. Less significant is the finding of outlet anomalies, representing 19,1 % of cases.

Routine use of these techniques of exploration seems to be extremely justified, even if it surely modifies the traditional therapeutical management, making it more complex.

On the other hand, the peculiar polymorphism of the testicular venous return, such as we pointed out with our technique, must be known at the time to proceed to an intervention of high spermatic vein ligation, just because, in this wide anatomical variety, lies the pathogenetic mechanism of a recurrence.

RESUMO

Após uma apresentação das diversas técnicas presentemente utilizadas na exploração radiológica do varicocele idiopático, analisa-se a técnica da venografia trans-escrotal ascendente pré-operatória. Neste artigo são discutidos os resultados de 94 venografias e é proposta uma classificação dos dados normais e das anomalias observadas com esta técnica. Com base nos dados obtidos, o uso da venografia trans-escrotal pré-operatória é recomendado como essencial no tratamento cirúrgico do varicocele. De facto, o polimorfismo do retorno venoso testicular e a presença de grande número de vasos anastomóticos pode ser considerado como causa possível quer de recorrência da patologia, quer da inibição bilateral da espermatogénese.

REFERENCES

- AHLBERG NE, BARTLEY O, CHIDEKEL N, FRITJOFSSON A: Phlebography in varicocele scroti. *Acta Radiol* 4: 517, 1966.
- CLEGG EJ: The termination of the left testicular and adrenal veins in man. *Fertil Steril* 21: 36, 1970.
- COHEN J: Les stérilités et hypofertilités masculines. 2nd ed. Paris, Masson. p. 157, 1977.
- COMHAIRE F, KUNNEN M: Selective retrograde venography of the internal spermatic vein: a conclusive approach to the diagnosis of varicocele. *Andrologia* 8: 11, 1976.
- D'OTTAVIO G, POZZA D, ZAPPAVIGNA D: La flebografia trans-scrotale della vena spermatica interna sinistra in corso di varicocele: utilità propedeutica per il trattamento chirurgico. *Atti V.º Congresso ESCO*. 1978. *in press*
- D'OTTAVIO G, POZZA D, ZAPPAVIGNA D: Validity of the pre-operative trans scrotal venography of the internal spermatic vein in the presence of idiopathic varicocele. *Acta Eur Fertilit* 9: 105, 1978.
- ETRIBY AA, IBRAHIM AA, MAHMOUD MZ, ELHAGGAR S: Subfertility and varicocele. I. Venogram demonstration of anastomosis sites in subfertile men. *Fertil Steril* 26: 1013, 1975.
- PEPELIER G: Sur l'étiologie du varicocele. Utilité de la veinographie. *Acta Urol Belg* 41: 602, 1973.

Adress for Reprints: *Gianfranco D'Ottavio*

*Unità D'Andrologia
Div. Chir. Generale
Ospedale San Carlo di Nancy
Via Aurelia 275
Roma - Italia*