

REFERENCES

1. Nogueira PJ, Nobre MA, Nicola PJ, Curtado C, Vaz Carneiro A. Estimativa do excesso de mortalidade durante a pandemia COVID-19:

dados preliminares portugueses. Acta Med Port (in press). <https://doi.org/10.20344/amp.13928>

Alastair KNIGHT✉¹

1. Evicom Ltd, Cascais, Portugal.

Autor correspondente: Alastair Knight, mail@evicom.co.uk

Recebido: 03 de maio de 2020 - Aceite: 04 de maio de 2020 | Copyright © Ordem dos Médicos 2020
<https://doi.org/10.20344/amp.14032>



Development of a Portuguese COVID-19 Imaging Repository and Database: Learning and Sharing Knowledge during a Pandemic

Desenvolvimento de um Repositório de Imagens e Base de Dados Portuguesa de Casos COVID-19: Aprendizagem e Partilha de Conhecimento em Tempo de Pandemia

Keywords: Access to Information; Coronavirus Infections; COVID-19; Portugal; Radiology Information Systems; Tomography, X-Ray Computed

Palavras-chave: Acesso à Informação; COVID-19; Infecções por Coronavírus; Portugal; Portugal; Sistemas de Informação em Radiologia; Tomografia Computorizada

The coronavirus disease 2019 (COVID-19) has been evolving rapidly world-wide and preparedness of health services and front-line hospitals in particular has led to a focus in containment, rapid diagnosis, effective treatment and extensive population screening.

Radiology departments have implemented infection prevention and control standard precautions, according to

published recommendations.^{1,2} Restructuring of hospital operations, however, has affected trainees in terms of their educational (residency) programs and workforce capabilities, in order to promote workplace safety.³ In order to further engage trainees and mitigate the restrictions of social distancing, educators have been encouraged to design alternative instructional platforms for active learning and promote digital teaching resources⁴.

Some international societies have developed public imaging registries for learning and research purposes, sharing knowledge and experience regarding COVID-19 in dedicated websites, namely the European Society of Radiology (EURORAD), the British Society of Thoracic Imaging and Società Italiana di Radiologia Medica e Interventistica.^{5,6} Such databases have been used as an adjunctive tool by colleagues all over the world to boost and improve their skills, as well as provide a better understanding of this condition.

With this in mind, a group of radiology residents in Portugal designed a public database of COVID-19 cases from their respective institution with the intention of creating a learning platform and share knowledge among peers.⁷

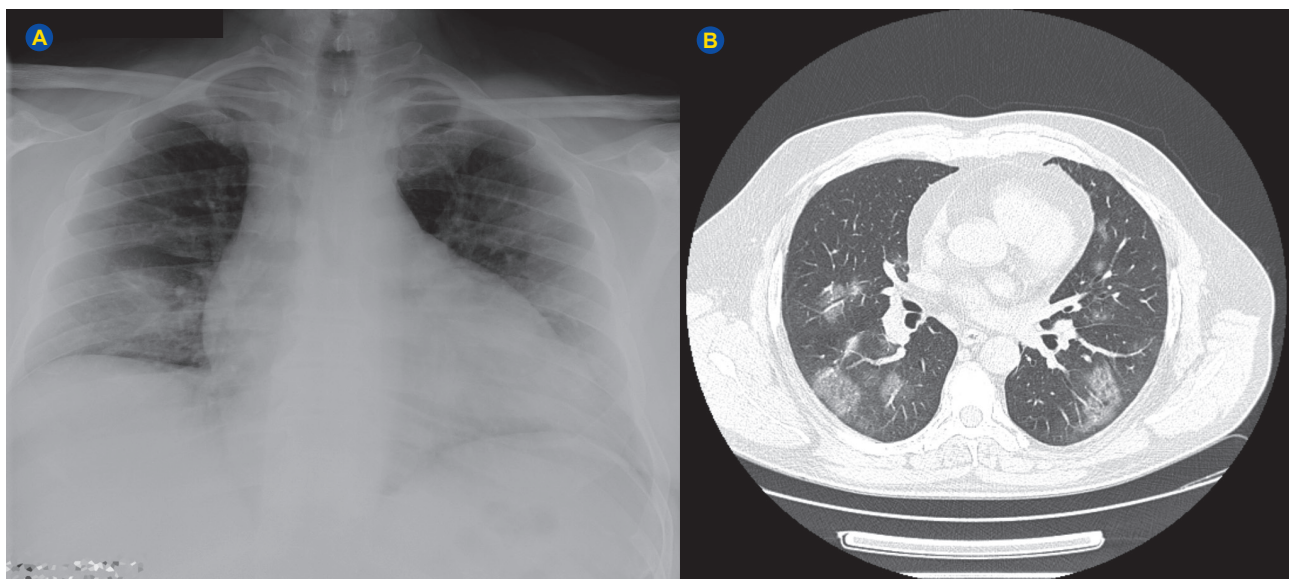


Figure 1 – 52-year-old hypertensive male patient attends the emergency department due to persistence of fever and diarrhea for six days. Lab work performed at admission reveals leucopenia, thrombocytopenia and increased lactate dehydrogenase levels. Chest radiography (A) and thoracic CT axial slice (B) performed at admission show multiple bilateral peripheral ground-glass opacities, compatible with COVID-19 pneumonia, which was confirmed with throat and nasal swab test.

The database is entirely anonymous and includes COVID-19 confirmed and suspected cases, as well as pertinent alternative cases such as COVID-229E, H1N1, H3N2 or atypical bacterial pneumonias. This public registry is unique since it contains a more detailed clinical history and follow-up of the patients.

To date, sixteen adult and ten pediatric COVID-19 confirmed cases have been inserted in the registry, as well as four COVID-19 suspected cases and eight alternative diagnoses (other atypical pneumonias). Informed consent was not possible to obtain due to patient contact restrictions, workplace precautions and quick progression of the outbreak, but absolute anonymity of the information shared was ensured. A clinical vignette was included for every patient which includes age, sex, clinical history, co-morbidities,

lab-work, follow-up time and hospitalization outcome, along with serial radiography and computed tomography (CT) performed at admission and during hospitalization (Fig. 1 shows a chest radiography and CT of a patient from the registry with typical COVID-19 pneumonia findings). More than 90% of cases included in the database performed thoracic CT, which allows for a more detailed imaging evaluation and comparison with radiographic findings.

The database is publicly available from <https://tinyurl.com/covid-19-portuguese-database> and has been disseminated to the scientific community through forums, websites and radiological societies. The authors would like to invite all radiologists as well as colleagues from other specialties to participate in this initiative and share cases with the community.

REFERENCES

1. Kooraki S, Hosseiny M, Myers L, Gholamrezanezhad A. Coronavirus (COVID-19) outbreak: what the department of radiology should know? *J Am Coll Radiol*. 2020;17:447-51.
2. Zhang H, Yu J, Xu H, Lei Y, Pu Z, Dai W, et al. Corona virus international public health emergencies: implications for radiology management. *Acad Radiol*. 2020;27:463-7.
3. Hyungjin K. Outbreak of novel coronavirus (COVID-19): what is the role of radiologists? *Eur Radiol*. 2020 (in press). doi.org/10.1007/s00330-020-06748-2.
4. Hare SS, Rodrigues JC, Jacob J, Edey A, Devaraj A, Johnstone A, et al. A UK-wide British Society of Thoracic Imaging COVID-19 imaging repository and database: design, rationale and implications for education and research. *Clin Radiol*. 2020;75:326-8.
5. British Society of Thoracic Imaging. COVID-19 BSTI Imaging database. 2020. [accessed 2020 Apr 27]. Available from: <https://www.bsti.org.uk/training-and-education/covid-19-bsti-imaging-database/>.
6. Società Italiana di Radiologia Medica e Interventistica. COVID-19 Database. 2020. [accessed 2020 Apr 27]. Available from: <https://www.sirm.org/category/senza-categoria/covid-19/page/4/>.
7. Portuguese COVID-19 Database, 2020. [accessed 2020 Apr 27]. Available from: <https://tinyurl.com/covid-19-portuguese-database>.

António Proença CAETANO✉¹, Teresa Resende NEVES¹, Rita Pina PRATA^{1,2}, Patrícia Silva FREITAS¹, Ana FORJACO¹, Matilde ALMEIDA E SOUSA¹, Ana Luísa PROENÇA¹, Carina RUANO¹, João Lopes DIAS¹

1. Radiology Department. Centro Hospitalar Universitário Lisboa Central. Lisboa. Portugal.

2. Radiology Department. Hospital Dr Nelio Mendonça (SSARAM, E.P.E.). Hospital Central do Funchal. Funchal. Portugal.

Autor correspondente: António Proença Caetano. aprocaetano@gmail.com

Recebido: 30 de abril de 2020 - Aceite: 05 de maio de 2020 | Copyright © Ordem dos Médicos 2020

<https://doi.org/10.20344/amp.14014>

