

Fever in a Patient with a Central Venous Catheter Colonized by *Pandoraea pnomenusa*

Febre numa Doente com Cateter Venoso Central Colonizado por *Pandoraea pnomenusa*

Susana RAMOS OLIVEIRA¹, Isabel COSTA MONTEIRO², Cristina RODRIGUES², Maria João SOARES³
Acta Med Port 2023 Feb;36(2):127-130 • <https://doi.org/10.20344/amp.16176>

ABSTRACT

Pandoraea species are a newly described genus of multidrug-resistant, non-fermentative Gram-negative bacilli, mainly isolated from sputum samples of cystic fibrosis patients. In immunocompromised patients or with high antibiotic selective pressure, these pathogens are generally opportunistic and invasive. Although *Pandoraea* spp. are rare, the true incidence of these infections may be underestimated due to difficulties in microbial identification by phenotypic methods. We present the case of a 51-year-old woman, with new-onset fever after a prolonged hospitalization and multiple courses of antibiotics. Mass spectrometry assays identified *Pandoraea pnomenusa* in the blood cultures taken from the central venous catheter and in the catheter tip. Fever cessation after catheter removal suggests a catheter-related bloodstream infection. To the best of our knowledge, this is the first isolation of a *Pandoraea* spp. in Portugal, which should raise awareness to the emergence of these opportunistic and multidrug-resistant microorganisms, and the importance of its prompt identification.

Keywords: Catheter-Related Infections; Central Venous Catheters/adverse effects; Fever; *Pandoraea pnomenusa*

RESUMO

O género *Pandoraea* é constituído por bacilos Gram-negativo não fermentadores multiresistentes, maioritariamente isolados em amostras respiratórias de doentes com fibrose quística. No entanto, em doentes imunodeprimidos e/ou sujeitos a elevada pressão antibiótica, podem ser agentes invasivos e oportunistas. Apesar de estas infeções serem raras, a incidência pode estar subestimada por dificuldades na sua identificação por métodos fenotípicos. Apresentamos um caso clínico de uma mulher de 51 anos, com febre *de novo* após um internamento complexo e múltiplos ciclos de antibioterapia. Nas hemoculturas colhidas do cateter venoso central e na ponta do cateter foi identificada, por espectrometria de massa, uma *Pandoraea pnomenusa*. A resolução da febre após retirada do cateter sugere uma bacteriemia associada a cateter. Tanto quanto é do nosso conhecimento, este é o primeiro caso reportado de *Pandoraea* spp. em Portugal, pondo em evidência a necessidade de se estar alerta para a emergência de agentes de infeção multiresistentes, bem como a necessidade da sua identificação precoce.

Palavras-chave: Cateter Venoso Central/efeitos adversos; Febre; Infecções Relacionadas a Cateter; *Pandoraea pnomenusa*

INTRODUCTION

The *Pandoraea* genus was first described by Coenye *T et al*¹ in 2000, after a careful genotypic and phenotypic characterization of species isolated from the environment or sputum of cystic fibrosis (CF) patients, previously misidentified as *Burkholderia cepacia*, *Ralstonia picketti* or *Ralstonia paucula*. The term *Pandoraea* refers to Pandora's box in Greek mythology – the origin of the evils of mankind.

These non-fermentative, Gram-negative bacilli (NFGNB), with oxidase activity, are naturally encountered in soil or water, but they can also be nosocomial pathogens associated with invasive devices, such as catheters or ventilation systems.¹⁻⁶ To date, six species have been identified in humans – *Pandoraea apista*, *Pandoraea pulmonicola*, *Pandoraea pnomenusa*, *Pandoraea sputorum*, *Pandoraea norimbergensis* and *Pandoraea fibrosis*.^{1,6}

Although rare, the *Pandoraea* spp. are emerging, with most isolates originating from sputum samples of patients with CF or other lung diseases.^{2-4,7,8} In addition to respiratory samples, isolation in skin lesions, urine and blood have

been described in CF and non-CF patients, the latter highlighting the invasive capacity of this species.^{2,4,9,10}

P. pnomenusa was the most isolated species from blood cultures (BC) in a Centers for Disease Control and Prevention study of 2001,² which revealed an increased potential for invasive disease. Since then, multiple invasive infections of *Pandoraea* spp. were described, mostly in non-CF patients.^{5,8-11} Catheter-related bloodstream infections (CR-BSI) and colonization of catheters without bacteriemia were also reported.^{3,12}

Phenotypically, *Pandoraea* spp. are very similar to *Burkholderia* and *Ralstonia* genera (with an intermediate phylogenetic position between these two), which may lead to an erroneous phenotypic identification of these agents.^{1-5,8,10} In fact, the incidence of *Pandoraea* infections may be underestimated due to difficulties in its identification. However, mass spectrometry assays have proven to be able to identify NFGNB which were not correctly identified by phenotypic methods.^{5,10,13,14}

1. Serviço de Doenças Infecciosas. Hospital Pedro Hispano. Matosinhos. Unidade Local de Saúde de Matosinhos. Portugal.

2. Serviço de Medicina Interna. Hospital Pedro Hispano. Unidade Local de Saúde de Matosinhos. Matosinhos. Portugal.

3. Sector de Microbiologia. Serviço de Patologia Clínica. Hospital Pedro Hispano. Unidade Local de Saúde de Matosinhos. Matosinhos. Portugal.

✉ Autor correspondente: Susana Ramos Oliveira. susana.ramosoliveira@ulsm.min-saude.pt

Recebido/Received: 12/03/2021 - Aceite/Accepted: 18/04/2022 - Publicado Online/Published Online: 23/05/2022 - Publicado/Published: 01/02/2023

Copyright © Ordem dos Médicos 2023



The treatment of *Pandoraea* infections can be challenging, as they have a broad resistance to antibiotics, and natural or acquired resistance mechanisms are not yet fully understood.^{2-5,7,8} In the particular case of carbapenems, there is a unique discrepancy in terms of susceptibility between meropenem and imipenem. Despite the presence of meropenem-hydrolyzing β -lactamases, which causes intrinsic resistance to meropenem, susceptibility to imipenem is common.^{2,4,5,8,12}

Moreover, due to its rarity, neither the European Committee on Antimicrobial Susceptibility Testing (EUCAST) nor the Clinical and Laboratory Standards Institute (CLSI) have established the antibiotic concentrations (breakpoints) at which this bacteria is considered to be susceptible to a certain antibiotic.^{5,15}

CASE REPORT

We report the case of a 51-year-old woman with a past medical history of severe hearing loss of unknown etiology, type 2 diabetes *mellitus* (HbA1c levels between 7.4% and 8.5% before admission), and a recent ischemic stroke requiring hospitalization for 34 days.

Twenty days after her discharge, the patient was admitted to the intermediate care unit with the diagnosis of sepsis due to *Clostridium perfringens* colitis with bacteremia, and initially completed 14 days of piperacillin/tazobactam and metronidazole.

Due to difficult peripheral access, a central venous catheter (CVC) was placed the following day.

The patient required a total of 78 days of hospitalization, reflecting a complex clinical course, with multiple infections and antimicrobial courses, which are summarized in Fig. 1.

On the 50th hospitalization day, while on daptomycin and ceftazidime/avibactam, the patient redeveloped subfebrile temperatures (37.4°C) of uncertain origin. BC were drawn the following day. Due to difficulty in obtaining peripheral access, BC were taken from the CVC.

One BC set was positive 21 hours after incubation. On microscopic examination, no bacteria were visualized in Gram staining. On bacteriological cultures, MacConkey agar revealed very small, non-fermentative colonies, oxidase positive, and blood and chocolate agar small, grey and pleomorphic colonies.

On the 53rd day, due to persistence of fever (maximum of 38.6°C) and the presence of a NFGNB on BC, empirical meropenem was initiated. The CVC was removed, and the catheter tip was cultured using a semiquantitative roll plate method (Maki's technique).

The second BC set was positive after 35 hours of incubation, and the Gram staining revealed very short and thin Gram-negative bacilli.

In both BC taken from the CVC and in the catheter tip

culture, *P. pnomenusa* was identified by mass spectrometry (VITEK[®]MS) with 99.9% certainty. The phenotypic identification method (VITEK[®] 2) was only able to identify the agent as *Pandoraea* spp. with 89% certainty.

On the 54th day, it was possible to obtain two peripheral BC, which yielded negative results.

According to the PK-PD (non-species related breakpoints) of EUCAST 2021,¹⁵ antimicrobial susceptibility was assessed by gradient tests (ETEST[®]) for ciprofloxacin, gentamycin, ceftazidime, ceftazidime/avibactam, piperacillin/tazobactam, imipenem and meropenem. The minimal inhibitory concentration of 2 μ g/mL of imipenem suggested that the isolated *P. pnomenusa* could only be treated with this antibiotic. For this reason, meropenem was discontinued.

Fever cessation coincided with CVC removal and no further treatment was instituted. The patient remained afebrile until discharge.

DISCUSSION

We report the identification of a rare microorganism – *P. pnomenusa*. To the best of our knowledge, this is the first isolation of *Pandoraea* spp. in Portugal.

The correct identification of NFGNB is crucial as the true incidence of *Pandoraea* infections may be underestimated. Its identification should be performed with mass spectrometry assays, which have demonstrated to have greater diagnostic accuracy compared with other phenotypic methods. In our laboratory VITEK[®] 2 was not able to distinguish between *Pandoraea* species.

It is known that *Pandoraea* spp. are opportunistic pathogens, infecting mainly CF patients, or individuals with some degree of immunosuppression or with a high antibiotic selective pressure.^{3,5,8,10,12} Our patient was hospitalized for a long period of time and received multiple antibiotic therapies, which probably favored the appearance of this organism.

Although *P. pnomenusa* was isolated in the BC taken from the CVC and in the catheter tip, the diagnosis of CR-BSI cannot be confirmed, as this agent was not identified in simultaneous peripheral BC. On the other hand, the fever had no-localized symptoms and ceased after removal of the colonized CVC, which supports this diagnosis.

To conclude, clinicians should be aware of the emergence of these multidrug-resistant microorganisms in susceptible patients, as they can be both colonizers and invasive infectious agents. Since *Pandoraea* species are a natural reservoir of carbapenem-hydrolyzing oxacillinases (antibiotic resistance genes), empirical treatment with carbapenems may be inappropriate, and even result in increased morbidity. Furthermore, the physical proximity with other species may promote plasmid-mediated horizontal

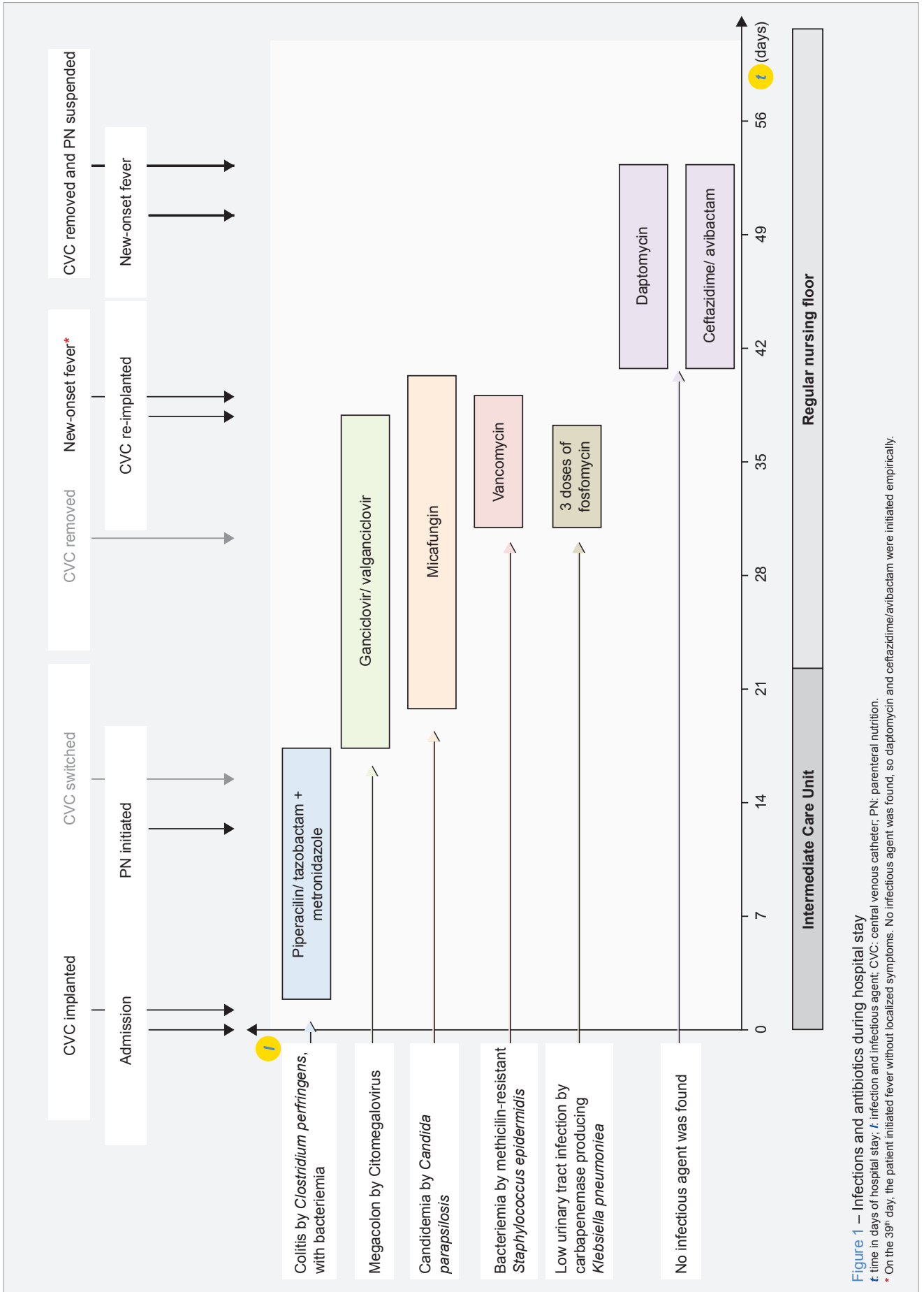


Figure 1 – Infections and antibiotics during hospital stay

t: time in days of hospital stay; t: infection and infectious agent; CVC: central venous catheter; PN: parenteral nutrition.

* On the 39th day, the patient initiated fever without localized symptoms. No infectious agent was found, so daptomycin and ceftazidime/avibactam were initiated empirically.

gene transfer of these resistance genes, favoring the appearance of new multi-drug resistance pathogens.⁷

ACKNOWLEDGMENTS

The authors gratefully acknowledge Mafalda Felgueiras for her advice and manuscript revision.

AUTHOR CONTRIBUTIONS

SRO: Literature review, data acquisition, drafting of the paper.

ICM: Literature review, data acquisition.

CR: Critical review of the paper (medical data).

MJS: Critical review of the paper (laboratory data).

PROTECTION OF HUMANS AND ANIMALS

The authors declare that the procedures were followed according to the regulations established by the Clinical Re-

search and Ethics Committee and to the Helsinki Declaration of the World Medical Association updated in 2013.

DATA CONFIDENTIALITY

The authors declare having followed the protocols in use at their working center regarding patients' data publication.

INFORMED CONSENT

Obtained.

COMPETING INTERESTS

None.

FUNDING SOURCES

The authors declare that there were no external sources of study for the performance of this article.

REFERENCES

1. Coenye T, Falsen E, Hoste B, Ohlen M, Goris J, Govan JR, et al. Description of *Pandoraea* gen. nov. with *Pandoraea apista* sp. nov., *Pandoraea pulmonicola* sp. nov., *Pandoraea pnomenusa* sp. nov., *Pandoraea sputorum* sp. nov. and *Pandoraea norimbergensis* comb. nov. *Int J Syst Evol Microbiol*. 2000;50:887-99.
2. Daneshvar MI, Hollis DG, Steigerwalt AG, Whitney AM, Spangler L, Douglas MP, et al. Assignment of CDC weak oxidizer group 2 (WO-2) to the genus *Pandoraea* and characterization of three new *Pandoraea* genomospecies. *J Clin Microbiol*. 2001;39:1819-26.
3. Monzón T, Valga F, Reichert J, López C. Hemodialysis catheter colonised by *Pandoraea sputorum*. *Nefrología*. 2018;38:662-4.
4. Tabatabaei M, Dastbarsar M, Moslehi MA. Isolation and identification of *Pandoraea* spp. from bronchoalveolar lavage of cystic fibrosis patients in Iran. *Ital J Pediatr*. 2019;45:1-8.
5. Lin C, Luo N, Xu Q, Zhang J, Cai M, Zheng G, et al. Pneumonia due to *Pandoraea Apista* after evacuation of traumatic intracranial hematomas : a case report and literature review. *BMC Infect Dis*. 2019;19:869.
6. See-too WS, Ambrose M, Malley R, Robson E, Mulcahy E, Manche E, et al. *Pandoraea fibrosis* sp. nov., a novel *Pandoraea* species isolated from clinical respiratory samples. *Int J Syst Evol Microbiol*. 2019;69:645-51.
7. Schneider I, Bauernfeind A. Intrinsic carbapenem-hydrolyzing oxacillinases from members of the genus *pandoraea*. *Antimicrob Agents Chemother*. 2015;59:7136-41.
8. Stryjewski ME, LiPuma JJ, Messier RH, Reller LB, Alexander BD. Sepsis, multiple organ failure, and death due to *Pandoraea pnomenusa* infection after lung transplantation. *J Clin Microbiol*. 2003;41:2255-7.
9. Pimentel JD, Macleod C. Misidentification of *Pandoraea sputorum* Isolated from sputum of a patient with cystic fibrosis and review of *Pandoraea* species infections in transplant patients. *J Clin Microbiol*. 2008;46:3165-8.
10. Xiao X, Tian H, Cheng X, Li G, Zhou J, Peng Z, et al. *Pandoraea sputorum* bacteremia in a patient who had undergone allogeneic liver transplantation plus immunosuppressive therapy: a case report. *Infect Drug Resist*. 2019;12:3359-64.
11. Johnson LN, Han JY, Moskowitz SM, Burns JL, Qin X, Englund A. *Pandoraea* bacteremia in a cystic fibrosis patient with associated systemic illness. *Pediatr Infect Dis J*. 2004;23:881-2.
12. Falces-Romero I, Gutiérrez-Arroyo A, Romero-Gómez MP. Catheter-associated bacteremia by *Pandoraea pnomenusa* in an infant with acute lymphoblastic leukaemia. *Med Clin*. 2016;147:132.
13. Fernández-Olmos A, García-Castillo M, Morosini MI, Lamas A, Máiz L, Cantón R. MALDI-TOF MS improves routine identification of non-fermenting Gram negative isolates from cystic fibrosis patients. *J Cyst Fibros*. 2012;11:59-62.
14. Fernández-Olmos A, Morosini MI, Lamas A, Garcia-Castillo M, Garcia-Garcia L, Cantón R, et al. Clinical and microbiological features of a cystic fibrosis patient chronically colonized with *Pandoraea sputorum* identified by combining 16S rRNA sequencing and matrix-assisted laser desorption ionization - time of flight mass spectrometry. *J Clin Microbiol*. 2012;50:1096-8.
15. The European Committee on Antimicrobial Susceptibility Testing. Breakpoint tables for interpretation of MICs and zone diameters. Version 11.0, 2021. [cited 2021 Feb 15]. Available from: https://www.eucast.org/fileadmin/src/media/PDFs/EUCAST_files/Breakpoint_tables/v_11.0_Breakpoint_Tables.pdf.