

Mesenteric Schwannoma, Intestinal Malrotation and Ileal Diverticulum: A Unique Association

Schwannoma Mesentérico, Má-rotação Intestinal e Divertículo Ileal: Uma Associação Única

Alberto ABREU DA SILVA¹, Andreia FERREIRA¹, Pierpaolo CUSATI², José Augusto MARTINS¹
Acta Med Port 2023 Apr;36(4):278-282 • <https://doi.org/10.20344/amp.17544>

ABSTRACT

Mesenteric schwannomas are rare benign tumors that arise in the mesentery. Ileal diverticula and intestinal malrotation in adults are rare findings, since they are usually asymptomatic. We present the case of an 86-year-old man, without any known previously known medical conditions, who was admitted in the emergency department with recurrent abdominal distension and intense pain. The radiological study suggested an intestinal malrotation. An exploratory laparotomy confirmed the intestinal malrotation with intermesenteric bands, as well as a mesenteric mass adjacent to an ileal diverticulum. Following a segmental enterectomy, the histology of the mass reported a mesenteric schwannoma. To the best of our knowledge, this is the first report of such association. We therefore present this report to showcase the diagnostic and therapeutical challenges in managing these conditions.

Keywords: Diverticulum; Intestinal Diseases; Neurilemmoma

RESUMO

Os schwannomas mesentéricos são tumores benignos raros com origem nas células de Schwann do mesentério. Divertículos ileais e má-rotação intestinal em adultos são também achados raros, por serem geralmente assintomáticos. Neste artigo apresentamos o caso de um homem de 86 anos, sem antecedentes conhecidos, que recorre à urgência por um quadro de dor abdominal e distensão. O estudo imagiológico sugeria uma má rotação intestinal, pelo que se realizou uma laparotomia exploradora, onde se verificaram várias bandas intermesentéricas, bem como uma massa mesentérica adjacente a um divertículo ileal. Foi realizada lise de bandas e uma enterectomia segmentar. A avaliação anatomo-patológica mostrou tratar-se de um schwannoma mesentérico. Tanto quanto é do nosso conhecimento, este é o primeiro relato de um caso com esta associação tripla, e tem como objetivo reforçar os desafios diagnósticos e terapêuticos na abordagem destas patologias.

Palavras-chave: Divertículo; Enteropatias; Neurilemoma

INTRODUCTION

Mesenteric schwannomas are rare benign tumors that arise from Schwann cells in neural sheaths in the mesentery, and are part of the family of benign peripheral nerve tumors.¹ Intestinal malrotations are disorders of the intestinal development and positioning, with a broad spectrum of anatomical presentations. The diagnosis in the elderly is rare and most commonly the presentation is either asymptomatic or with insidious symptoms.² Ileal diverticula are rare findings, seldom symptomatic, and are usually associated with dysmotility of the small bowel.³ We present, to the best of our knowledge, the first report of an association of these three conditions.

CASE REPORT

An 86-year-old man, without previously known medical conditions, presented to the emergency department with recurrent diffuse abdominal distention and pain, loss of appetite and vomiting for two weeks. Bowel movements were present, and the feces were liquid, yellow, without blood, pus or mucus. No significant change in body weight was reported. The patient had been admitted due to the same

symptoms four months before and had undergone conservative treatment with full recovery. At that time, the radiologic and endoscopic tests did not reveal any unusual findings. In our evaluation, there were no changes of inflammatory or other biochemical parameters. A CT scan was performed and suggested an atypical intestinal malrotation based on a whirlpool pattern (Fig. 1) with mild intestinal distention. Given the recurrence of symptoms and considering the CT findings, we decided to perform an exploratory laparotomy. We confirmed the existence of a mildly distended small bowel, due to a torsion caused by an atypical intestinal malrotation. This torsion was caused by anomalous intermesenteric bands (Fig. 2). Surprisingly, we also found a mesenteric mass of 3.5 x 4 x 3.6 cm, of elastic consistency, white colored, adjacent to an ileal loop (Figs. 3 and 4). We sectioned the intermesenteric bands and performed a segmental enterectomy, which included the mass. During this process, an ileal diverticulum was found within the sheaths of the mesentery, next to the mass (Fig. 4). Due to its covert position, the diverticulum was accidentally sectioned, without significant field contamination. The recovery was

1. Serviço de Cirurgia Geral. Unidade Local de Saúde do Litoral Alentejano. Santiago do Cacém, Portugal.

2. Serviço de Anatomia Patológica. Unidade Local de Saúde do Litoral Alentejano. Santiago do Cacém, Portugal.

✉ Autor correspondente: Alberto Abreu da Silva. alberto.abreudasilva@gmail.com

Recebido/Received: 07/12/2021 - Aceite/Accepted: 08/07/2022 - Publicado Online/Published Online: 01/08/2022 - Publicado/Publicated: 03/04/2023

Copyright © Ordem dos Médicos 2023



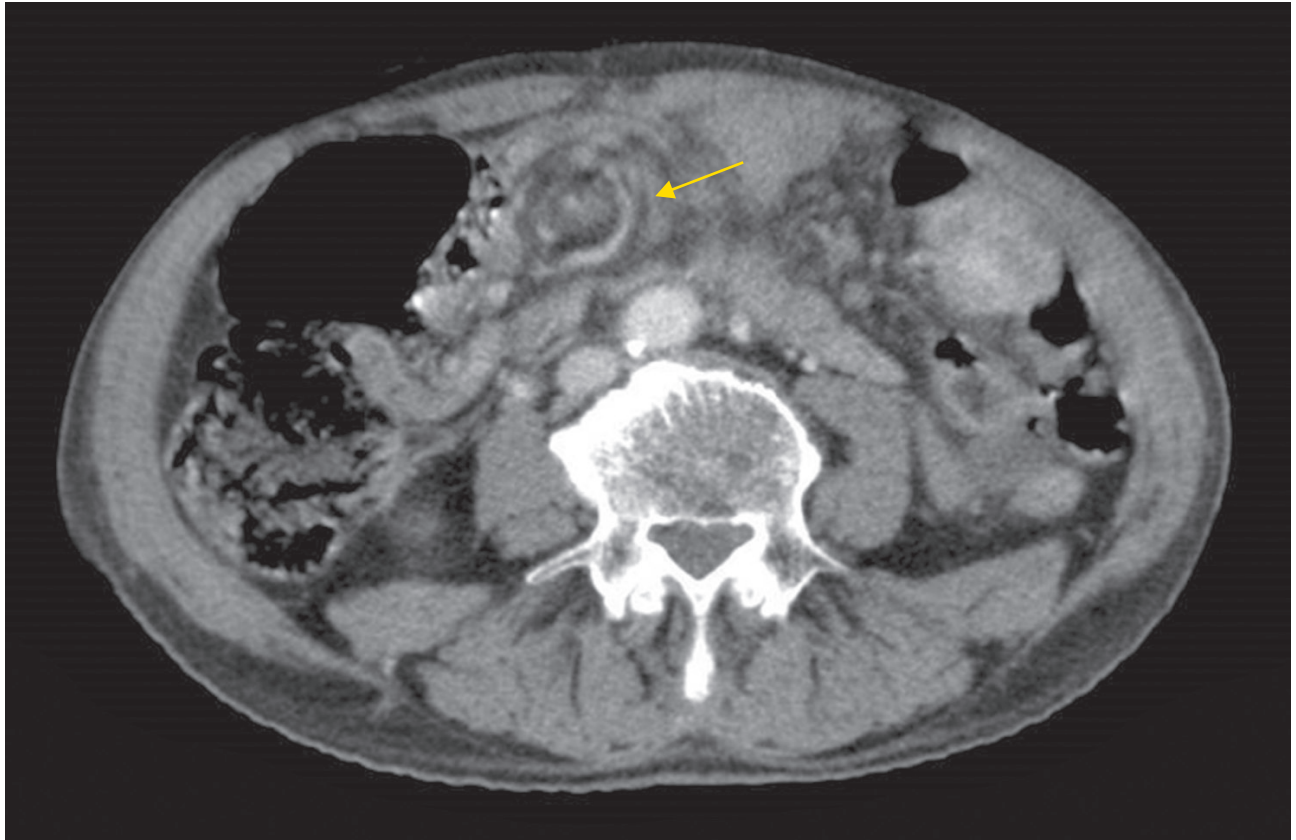


Figure 1 – Abdominal CT scan, axial. Arrow: whirlpool sign, suggestive of mesenteric torsion.

uneventful, and the patient was discharged five days after. The histology of the mass was reported as a mesenteric schwannoma. In the microscope it was possible to identify Antoni A areas, composed of Schwann cells, alternating with hypocellular Antoni B areas, with rare cells with a hyalinized stroma (Fig. 5A). Moreover, immunohistochemistry assays showed a strongly positive nuclear staining for S-100 (Fig. 5B). The patient has been followed up for two years. During this time, he remained asymptomatic and without complications following the surgical intervention.

DISCUSSION

Schwannomas are benign neoplasms that originate from Schwann cells and are part of the family of benign nerve sheath tumors, along with other neoplasms such as neurofibromas or perineurinomas.¹ The occurrence of mesenteric schwannomas is exceedingly rare. These tumors are usually slow-growing and therefore asymptomatic, even though they may cause recurrent abdominal pain or gastrointestinal occlusion due to organ compression.⁴ Hence, schwannomas are usually incidentally discovered in imaging studies or during surgery. Since their radiological findings are non-specific and biopsy has low sensitivity, the

definitive diagnosis is given by the pathological evaluation of the mass following surgical resection.⁵ An incidental finding of mesenteric masses is unusual, with an estimated prevalence in the United States of 1/100 000. The most common mesenteric masses are cystic lymphangiomas, which account to nearly 50% of all cases of mesenteric masses, and the most frequent mesenteric solid masses are lymphomas, although other diagnoses are possible.⁶ Given the possibility of malignancy, and to avoid complications associated with tumor growth, the resection of a mesenteric mass is thus indicated whenever discovered.

The case we present depicts a clinical scenario composed of vague but recurrent symptoms which can be attributed to the schwannoma, to the malrotation or to the combination of both conditions. An intestinal malrotation is an abnormality of the intestinal position and the fixation is secondary to an irregular intestinal embryological development.⁷ A finding like this in adulthood is infrequent, with approximately 90% of the cases presenting in the first year of life.² The presentation of intestinal malrotations in adults is more frequently insidious, with chronic mild gastrointestinal symptoms such as recurrent abdominal pain, nausea, vomiting and constipation, but may be more evident with

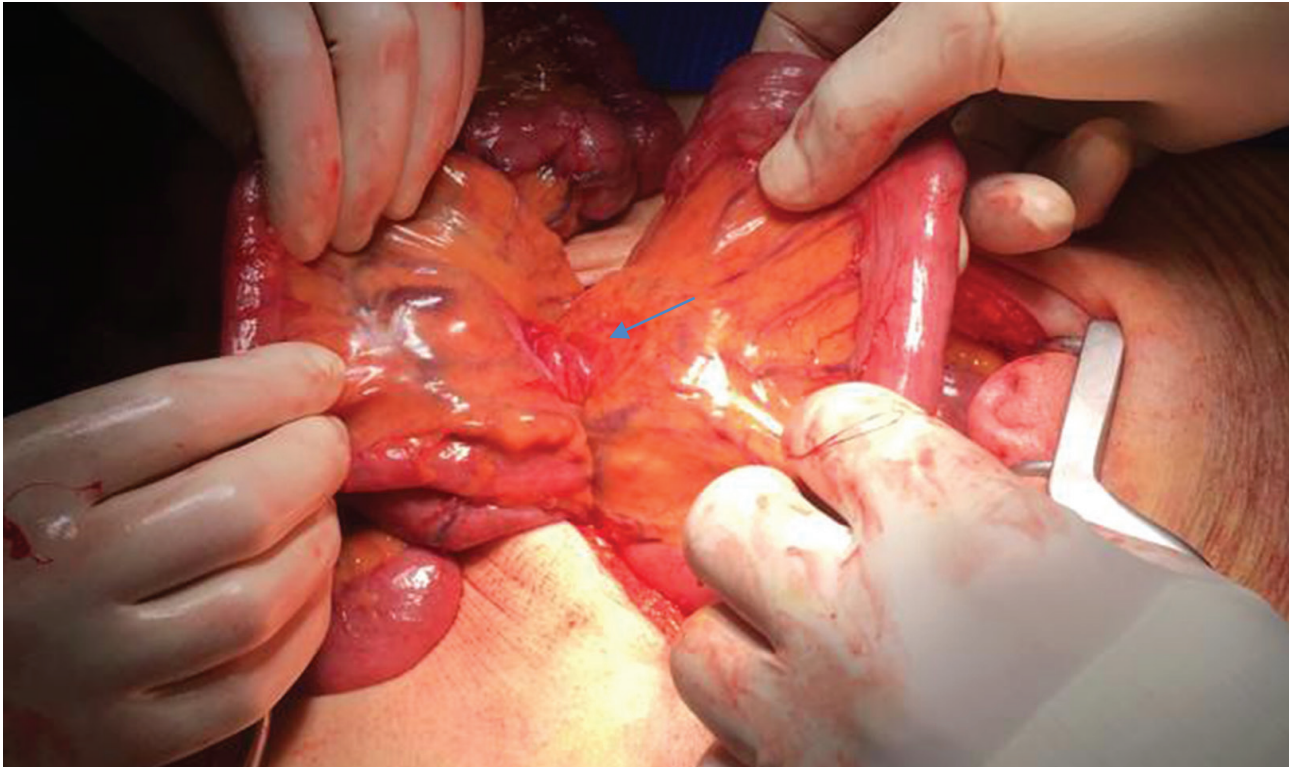


Figure 2 – Intraoperative finding. Arrow: intermesenteric band.

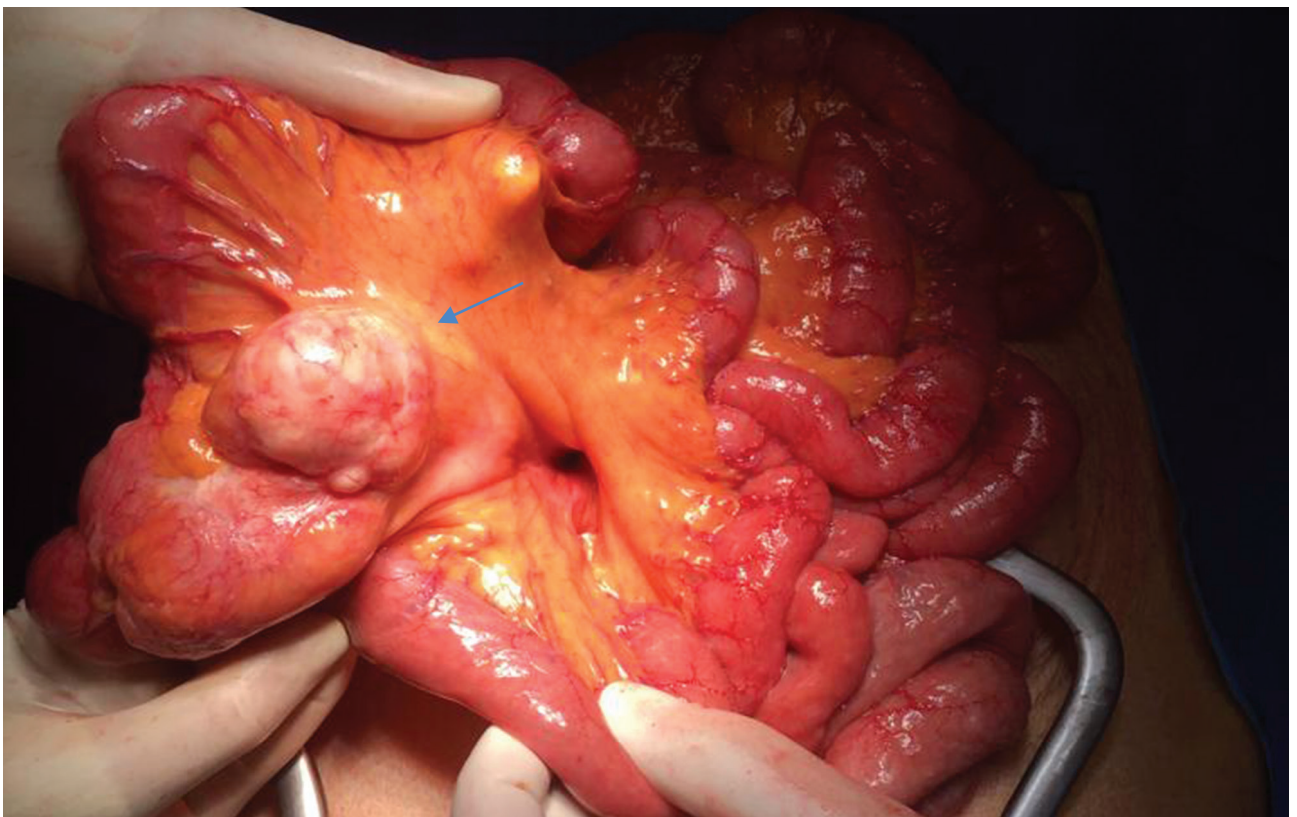


Figure 3 – Intraoperative finding. Arrow: mesenteric mass adjacent to an ileal loop.

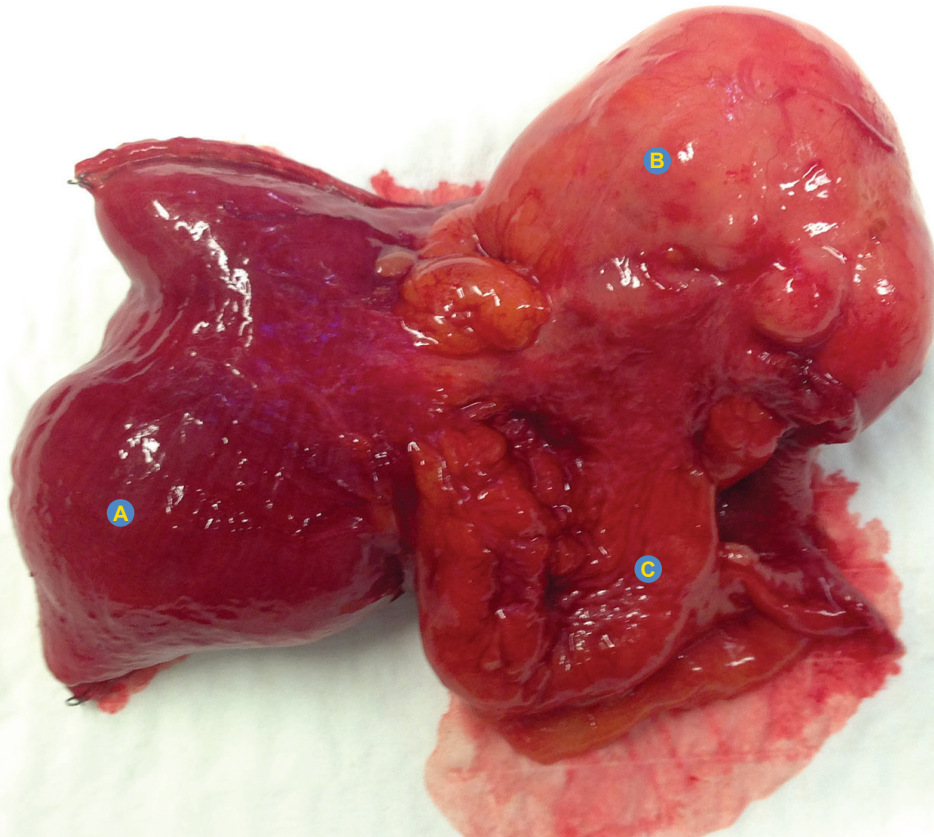


Figure 4 – Resection specimen (A) ileal loop; (B) mesenteric mass; (C) ileal diverticulum within the mesentery sheaths.

occlusive symptoms or in association with symptoms related to additional congenital defects.⁸ The most common findings in the CT scan were already described elsewhere,⁹ with a particular note on the possibility of finding the whirlpool sign.¹⁰ This pattern, which our patient presented, depicts a twist of the mesentery, and must raise suspicion of

an intestinal volvulus. The treatment of symptomatic intestinal malrotations is surgical.¹¹ Some studies suggest that asymptomatic patients can be treated conservatively, but this approach remains controversial.¹²

Our procedure was complicated by the section of an ileal diverticulum occurring within the mesenteric sheaths,

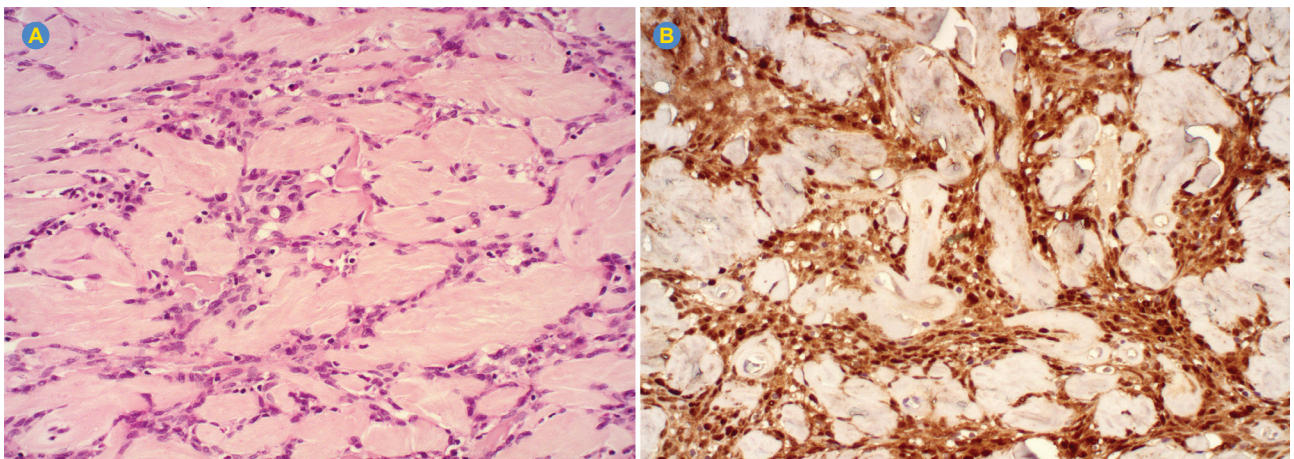


Figure 5 – Characteristic histological findings of schwannomas (200x, electronic microscope) (A) Antoni A and Antoni B areas; (B) Positive S100 nuclear protein immunohistochemistry staining.

next to the mass. Jejunoileal diverticula are rare, with reported incidence rates ranging from 0.3% to 1.3%, with a lower incidence in the ileum. They occur more commonly during the sixth and seventh decades of life.¹³ Most acquired ileal diverticula are related with intestinal dysmotility and high intraluminal pressures, which cause an invagination through weakened smooth muscle regions next to penetrating mesenteric branches. These diverticula are frequently engulfed within the mesenteric sheaths, which explains why they are often overlooked during surgery.³ In this case, it is possible that a local compressive effect by the mass altered the local intestinal motility, hence promoting the formation of a diverticulum.

To the best of our knowledge, this is the first report of an association of a mesenteric schwannoma, an intestinal malrotation and an ileal diverticulum. This case report draws attention to multiple aspects that the surgeon must bear in mind: there are cases in which non-specific symptoms without obvious clinical cues may be a sign of an underlying important condition; intestinal malrotation has to be a differential diagnosis of occlusion in the elderly, despite its low frequency; when approaching incidental mesenteric masses one must always consider the possibility of malignancy; consideration to disorders that are concomitant with intestinal diseases must be given, such as small bowel diverticula.

REFERENCES

- Rodríguez F, Folpe A, Giannini C, Perry A. Pathology of peripheral nerve sheath tumors: diagnostic overview and update on selected diagnostic problems. *Acta Neuropathol.* 2013;123:295-319.
- Mcvay MR, Kokoska ER, Jackson RJ, Smith SD. The changing spectrum of intestinal malrotation: diagnosis and management. *Am J Surg.* 2007;194:712-19.
- Makris K, Tsiotos GG, Stafyla V, Sakorafas GH. Small intestinal nonmeckelian diverticulosis. *J Clin Gastroenterol.* 2009;43:201-7.
- Tepox-Padrón A, Ramírez-Márquez MR, Córdova-Ramón JC, Cosme-Labarthe J, Carrillo-Pérez DL. Mesenteric schwannoma: an unusual cause of abdominal mass. *Rev Española Enfermedades Dig.* 2017;109:76-8.
- Yeh Y, Hsieh C, Chan D, Yu J. Mesenteric schwannoma: a case report and review of the literature. *J Med Sci.* 2011;31:43-6.
- Dufay C, Abdelli A, Pennec V Le, Chiche L. Mesenteric tumors: diagnosis and treatment. *J Visc Surg.* 2012;149:e239-51.
- Durkin ET, Lund DP, Shaaban AF, Schurr MJ, Weber SM. Age-related differences in diagnosis and morbidity of intestinal malrotation. *J Am Coll*

AUTHOR CONTRIBUTIONS

All authors contributed equally to this manuscript.

PROTECTION OF HUMANS AND ANIMALS

The authors declare that the procedures were followed according to the regulations established by the Clinical Research and Ethics Committee and to the Helsinki Declaration of the World Medical Association published in 2013.

DATA CONFIDENTIALITY

The authors declare having followed the protocols in use at their working center regarding patients' data publication.

PATIENT CONSENT

Obtained.

COMPETING INTERESTS

All authors report no competing interests.

FUNDING SOURCES

This research did not receive any specific grant from funding agencies in the public, commercial, or not-for-profit sectors.

- Surg. 2008;206:658-63.
- Neville JJ, Sharma E, Al-Muzrakchi A, Sheth H. Congenital intestinal malrotation presenting in octogenarians: a report of two cases. *Ann R Coll Surg.* 2020;102:e12-4.
- Husberg B, Salehi K, Peters T, Gunnarsson U, Michanek M, Nordenskjöld A, et al. Congenital intestinal malrotation in adolescent and adult patients: a 12-year clinical and radiological survey. *SpringerPlus.* 2016;5:245.
- Bhatia S, Jain S, Singh CB, Bains L, Kaushik R. Malrotation of the gut in adults: an often forgotten entity. *Cureus.* 2018;10:e2313.
- Fu T, Tong WD, He YJ, Wen YY, Luo DL, Liu BH. Surgical management of intestinal malrotation in adults. *World J Surg.* 2007;31:1797-803.
- Choi M, Borenstein S, Hornberger L, Langer J. Heterotaxia syndrome: the role of screening for intestinal rotation abnormalities. *Arch Dis Child.* 2005;90:813-5.
- Peuter B De, Box I, Vanheste R, Dymarkowski S. Case report small-bowel diverticulosis: imaging findings and review of three cases. *Gastroenterol Res Pract.* 2009:549853.