

## Spontaneous Monochorionic Quadramniotic Pregnancy: A Rare and Challenging Diagnosis

### Gravidez Monocoriónica Quadriamniótica Espontânea: Um Diagnóstico Raro e Desafiante

**Keywords:** Amnion/diagnostic imaging; Chorion/diagnostic imaging; Pregnancy, Quadruplet; Twins, Monozygotic; Ultrasonography, Prenatal

**Palavras-chave:** Âmnio/diagnóstico por imagem; Córion/diagnóstico por imagem; Gémeos Monozigóticos; Gravidez de Quadrigémeos; Ultrassonografia Pré-Natal

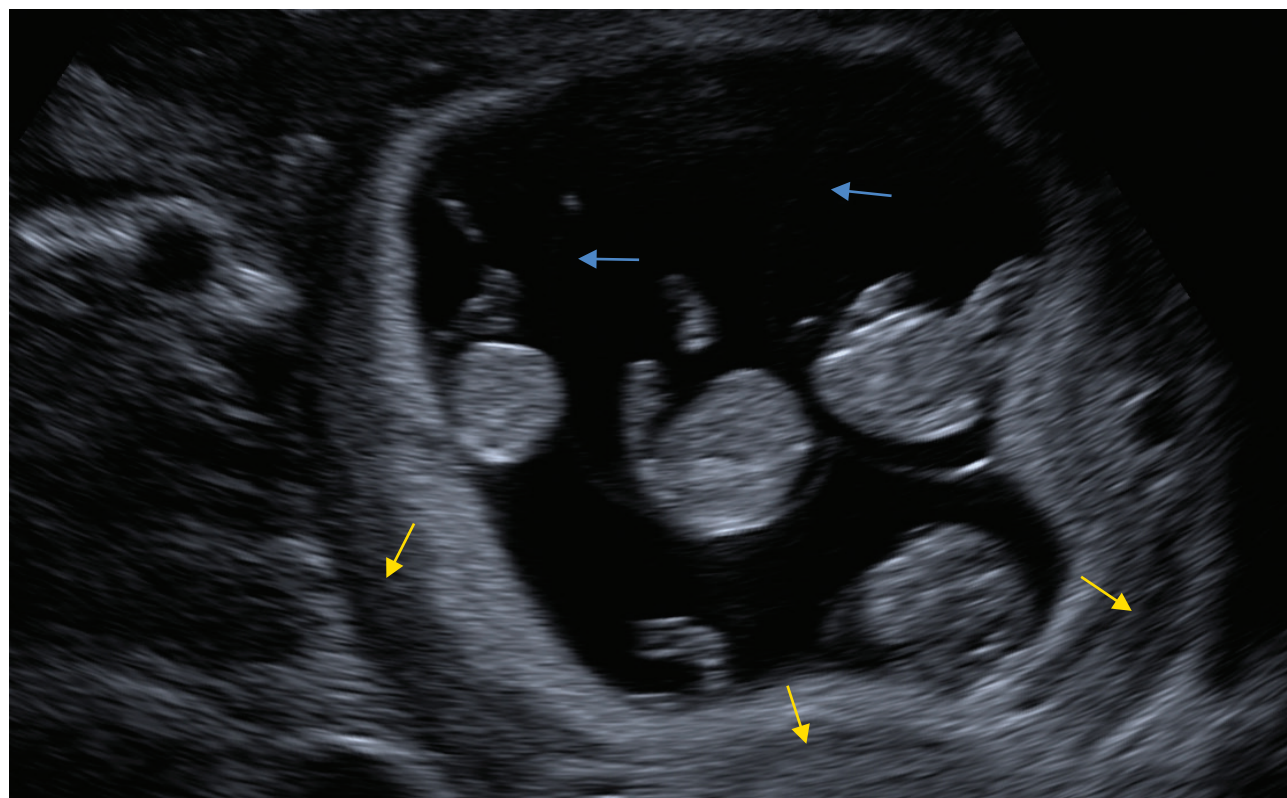
Dear Editor,

Monochorionic quadruplet pregnancy is extremely rare, particularly if naturally conceived, with an estimated incidence of 1 in 15 million pregnancies.<sup>1,2</sup>

We present the case of a 40-year-old primiparous healthy pregnant woman that was referred to our department at 9 + 6 weeks for early-pregnancy assessment and a suspected spontaneous quadruplet gestation. The ultrasound investigation revealed a quadruplet pregnancy with a common placental mass and thin membranes approaching the placental surface in a T-shape, confirming a monochorionic quadramniotic pregnancy (Fig. 1). The crown-rump length was similar for all fetuses (fetus: A – 27.2 mm; B – 31.9 mm; C – 30.8 mm; D – 33.7 mm) and the placental insertion of the umbilical cord was velamentous (umbilical cord attaches to the chorioamniotic membranes surrounding the placenta instead of the central mass) in fetuses A and B and marginal in fetus C and D. After comprehensive

counselling regarding the risks and complications of monochorionic quadruplets by a prenatal diagnosis multidisciplinary team, the parents decided to voluntarily interrupt the pregnancy, which is legally allowed in Portugal at the woman's request until ten weeks of gestation.

The risk of complications in quadruplet pregnancies is high and depends on the chorionicity (number of placentas in a multiple gestation). In multifetal pregnancies, monochorionicity is associated with higher morbidity and mortality rates, particularly in cases of twin-twin transfusion syndrome (TTTS), twin anemia polycythemia sequence (TAPS) and selective intrauterine growth restriction, all complications of monochorionic pregnancies that may develop owing to placental vascular anastomoses and unequal placental sharing.<sup>3</sup> Although endoscopic laser ablation of these anastomoses has been considered an effective treatment in TTTS, this procedure could be particularly challenging in pregnancies with more than two fetuses that are at higher risk of complications, namely early preterm delivery and low birth weight.<sup>1,3</sup> Furthermore, maternal morbimortality is also higher in multiple gestations compared with singletons, in particular in monochorionic pregnancies and those with more than two fetuses, due to an increase of some life-threatening and potentially fatal complications such as hypertensive disorders, placental abruption or postpartum hemorrhage. In the literature, there are only four case reports on monochorionic quadruplets,<sup>1-4</sup> whose outcomes are detailed in Table 1.



**Figure 1** – Ultrasound imaging of a monochorionic quadramniotic pregnancy with a common placental mass (yellow arrows) and thin amniotic membranes (blue arrows)

Table 1 - Case reports in the literature on monochorionic quadruplets and its outcomes

Ref.	Age at diagnosis	TTTS	Laser treatment	Delivery	Postnatal outcomes
1.	-	TTTS between fetuses D (donor) and A (recipient) – Quintero stage IV. Diagnosis at 20 weeks.	Endoscopic laser ablation of 3 anastomoses at 20 weeks. Fetal demise of the recipient (A).	Spontaneous vaginal birth of 3 live neonates at 24 weeks (300 g, 650 g and 700 g).	Neonatal death of neonates D and B. Neonate C survived, presenting with complications related to prematurity and continuing to improve neurodevelopmentally.
2.	11 + 6 weeks	Polyhydramnios in the 4 <sup>th</sup> fetus, suggesting the onset of TTTS at 28 weeks. Postnatal placental evaluation confirmed 3 intertwin AV anastomoses between the 3 <sup>rd</sup> and 4 <sup>th</sup> fetuses.	No	Elective CS of 4 live neonates (1050 g, 986 g, 1050 g and 1100 g) at 28 weeks.	Four healthy neonates were discharged from the hospital after 63 days in the NICU.
3.	12 + 6 weeks	Double TTTS (2 pairs: fetuses B and C and fetuses A and D) – Quintero stage II. Diagnosis at 19 weeks.	Endoscopic laser ablation of all visible anastomoses at 19 weeks.	Elective CS of 4 live neonates (1340 g, 1110 g, 1040 g and 1060 g) at 32 weeks.	Four healthy neonates were discharged from the hospital after 30 days in the NICU. No functional or developmental abnormalities were reported until the 2 years of corrected age.
4.	16 weeks	No	No	Elective CS due to preeclampsia at 31 weeks, with 4 live neonates (1440 g, 1361 g, 1380 g and 940 g).	All neonates were admitted to NICU with complications related to prematurity (ventilatory support and retinopathy of prematurity).

All monochorionic quadramniotic pregnancies were spontaneous.

TTTS: twin-twin transfusion syndrome; AV: arteriovenous; CS: cesarean section; NICU: neonatal intensive care unit

This article highlights a very rare and challenging clinical case, whose management was hindered by the advanced maternal age and the potential adverse outcomes related with monochorionic quadramniotic pregnancies. Moreover, early ultrasound assessment of chorionicity and amnionity is strongly recommended to ensure a careful surveillance and avoid serious pregnancy complications, while allowing parents to promptly decide to terminate or continue the pregnancy, as demonstrated in this particular case.

#### AUTHOR CONTRIBUTIONS

DA: Conception and design of the manuscript and literature review.

MB: Image creation.

FM, ISS, MB: Patient management, critical review of the work, approval of the version to be published.

#### PROTECTION OF HUMANS AND ANIMALS

The authors declare that the procedures were followed according to the regulations established by the Clinical Re-

search and Ethics Committee and to the Helsinki Declaration of the World Medical Association updated in 2013.

#### DATA CONFIDENTIALITY

The authors declare having followed the protocols in use at their working center regarding patients' data publication.

#### PATIENT CONSENT

Obtained.

#### COMPETING INTERESTS

The authors have declared that no competing interests exist.

#### FUNDING SOURCES

This research received no specific grant from any funding agency in the public, commercial, or not-for-profit sectors.

#### REFERENCES

- O'Brien BM, Feltovich HM, Carr SR, Luks FI. Feto-fetal transfusion syndrome in monochorionic quadruplets. *Obstet Gynecol.* 2010;115:470–2.
- Faber S, Riße S, Steinke H, Thome U, Stepan H. Monochorionic quadruplet pregnancy without severe complications: sonographic work-up and placental findings. *Ultrasound Obstet Gynecol.* 2013;41:707–8.
- Tul N, Bricelj K, Ravnik D, Diehl W, Hecher K. Successful laser treatment in monochorionic quadruplets affected by fetofetal transfusion syndrome. *Ultrasound Obstet Gynecol.* 2015;46:749–50.
- Timor-Tritsch IE, Fleischer A, Monteagudo A, Valderrama E. Monochorionic quadramniotic quadruplets: sonographic workup. *Fetal Diagn Ther.* 1997;12:363–7.

Dora ANTUNES<sup>1,2</sup>, Filipa MARQUES<sup>1</sup>, Isabel SANTOS SILVA<sup>1,2</sup>, Miguel BRANCO<sup>1</sup>

1. Departamento de Ginecologia, Obstetrícia, Reprodução e Neonatologia. Centro Hospitalar e Universitário de Coimbra. Coimbra. Portugal.

2. Faculdade de Medicina. Universidade de Coimbra. Coimbra. Portugal.

✉ Autor correspondente: Dora Antunes. [dora.antunes9@gmail.com](mailto:dora.antunes9@gmail.com)

Recebido/Received: 02/11/2022 - Aceite/Accepted: 15/02/2023 - Publicado/Published: 03/04/2023

Copyright © Ordem dos Médicos 2023

<https://doi.org/10.20344/amp.19283>

## Exercise Intolerance Following COVID-19: What Is the Role of Dysfunctional Breathing?

### Intolerância ao Exercício Após COVID-19: Qual o Papel da Respiração Disfuncional?

**Keywords:** COVID-19; Exercise Test; Exercise Tolerance; Post-Acute COVID-19 Syndrome; Respiration

**Palavras-chave:** COVID-19; Respiração; Síndrome Pós\_COVID-19 Agudo; Teste de Esforço; Tolerância ao Exercício

Dear Editor,

Cardiopulmonary exercise testing (CPET) has been used to explore persisting symptoms post-COVID-19. Different pathophysiological patterns have been reported<sup>1-3</sup>: oxygen transport/delivery problems, dysfunctional breathing (erratic or inappropriate ventilation during exercise),<sup>4</sup> ventilatory limitation, gas exchange abnormality, chronotropic insufficiency (reduced ability to increase heart rate during exercise) and dysautonomia. To explain these findings, a number of mechanistic explanations have been proposed,<sup>1,2</sup> namely deconditioning, endothelial injury, enhanced chemoreflex sensitivity, respiratory centre dysfunction and mitochondrial dysregulation.

We analysed our case series from Glasgow (Gartnavel General Hospital and Glasgow Royal Infirmary), Scotland, of 46 adult incremental symptom-limited CPETs (the standard protocol in the unit) performed because of breathlessness post-COVID-19 that was not fully explained by pulmonary function tests, chest imaging or echocardiogram. The data in this study are anonymised and retrospectively collected from tests performed as part of the routine clinical care of patients. Consequently, ethics committee approval was not sought for this analysis.

The median (IQR) duration from COVID diagnosis to CPET was 14 (10) months. The mean (SD) age was 51.9 (12.8) years, 63% were women, mean (SD) BMI was 31.1 (6.2) kg/m<sup>2</sup> and 30.4% (n = 14) were smokers/ex-smokers. As for comorbidities, 13 patients had asthma, one had COPD, six had systemic hypertension, four had mild anaemia, three had type 2 diabetes, one had ischemic heart disease and seven had been prescribed heart rate-control medication. Twelve patients were hospitalized with one being admitted to the high-dependence or intensive care unit. Six patients had pulmonary embolism and three had a di-

agnosis of chronic thromboembolic pulmonary disease. The mean (SD) forced expiratory volume in 1 second (FEV<sub>1</sub>) was 101% (17) and transfer factor for carbon monoxide (TLCO) was 82% (19), of the predicted value. Lung imaging was abnormal in five [minor non-specific reticular changes or ground glass (n = 3); expiratory air trapping (n = 1); and hemidiaphragm elevation (n = 1)] and the echocardiogram was abnormal in three out of 25 patients tested (mildly dilated right ventricle, mild left ventricular systolic dysfunction and bicuspid aortic valve).

Only 27 subjects (59%) performed a maximal test. The remaining patients stopped before clear physiological limitation. The mean (SD) peak oxygen uptake (VO<sub>2</sub>) was 20.7 (6.7) mL/kg/min and 88.2% (20.1) of predicted, with 14 patients (30.4%) having a peak VO<sub>2</sub> below the lower limit of normal (LLN) and 80% showing functional limitation with VO<sub>2</sub> < 25 mL/kg/min. The commonest abnormalities seen were dysfunctional breathing/acute hyperventilation (54%), gas exchange abnormalities (52%; with dysfunctional breathing in 72% of these cases) and oxygen transport/delivery problems typically of mild degree and consistent with deconditioning (35%). Evidence of dysfunctional breathing was seen in 64% of those with a peak VO<sub>2</sub> < LLN. Dysfunctional breathing was identified subjectively from an abnormality in the biomechanical pattern of breathing in response of exercise during the test. The commonest abnormality was an abrupt rise in the respiratory exchange ratio (RER, the ratio between the metabolic production of carbon dioxide and the uptake of oxygen) (> 1.0) and ventilatory equivalents in the early part of the test which then fell again as the test proceeded. This was usually combined with an irregular pattern of tidal volume and respiratory rate when plotted against ventilation. There were no cases of ventilatory limitation and there was one case of postural tachycardia syndrome (which has also been reported<sup>5</sup> with other viruses).

Other than dysfunctional breathing, we did not find a COVID-19 specific CPET pattern of exercise intolerance that could not be explained by other conditions. In our view and as previously reported,<sup>2,4</sup> breathing dysregulation may represent a possible pathophysiological explanation for much of the physical limitation post-COVID-19.

#### ACKNOWLEDGMENTS

We acknowledge the respiratory physiology staff at