

Exuberant Plexiform Neurofibroma

Neurofibroma Plexiforme Exuberante

Catarina CORREIA¹, Miguel REIS^{1,2}, Paulo FILIPE^{1,2}
Acta Med Port 2023 Dec;36(12):846-847 • <https://doi.org/10.20344/amp.19477>

Keywords: Neurofibroma, Plexiform; Neurofibromatosis 1
Palavras-chave: Neurofibroma Plexiforme; Neurofibromatose 1

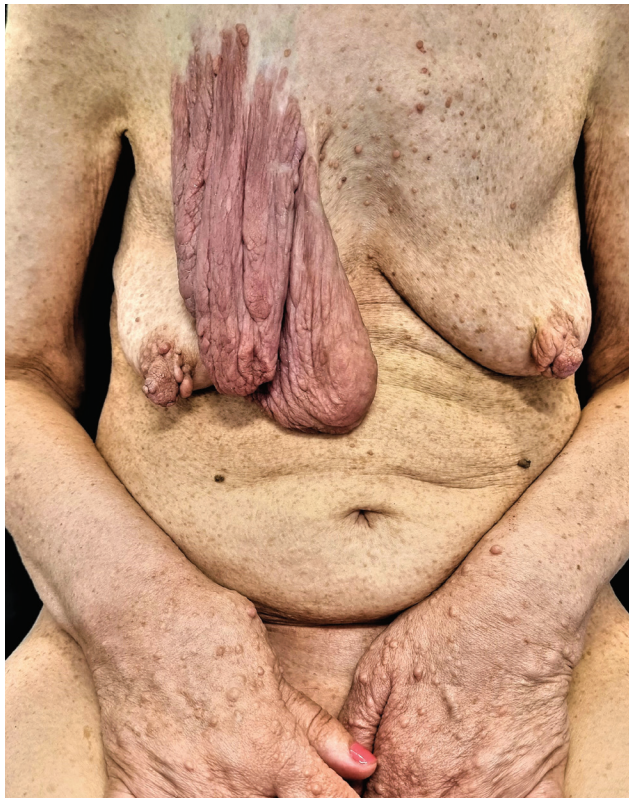


Figure 1 – Plexiform neurofibroma on the right thoracic region and multiple disseminated neurofibromas on the trunk and upper limbs. In the lower right corner, the plexiform neurofibroma is seen in greater detail laterally.

A 60-year-old woman with neurofibromatosis type-1 presented with a 10-year history of an asymptomatic slow-growing erythematous pedunculated tumor with 16 x 11 x 4 cm on the right thoracic region. She also had numerous neurofibromas on the trunk and upper limbs, as well as axillary and inguinal freckles (Fig. 1). On palpation of this tumor, there was a 'bag of worms'-like consistency. The biopsy of the tumor confirmed the diagnosis of plexiform neurofibroma (Fig. 2). The patient remains under follow-up

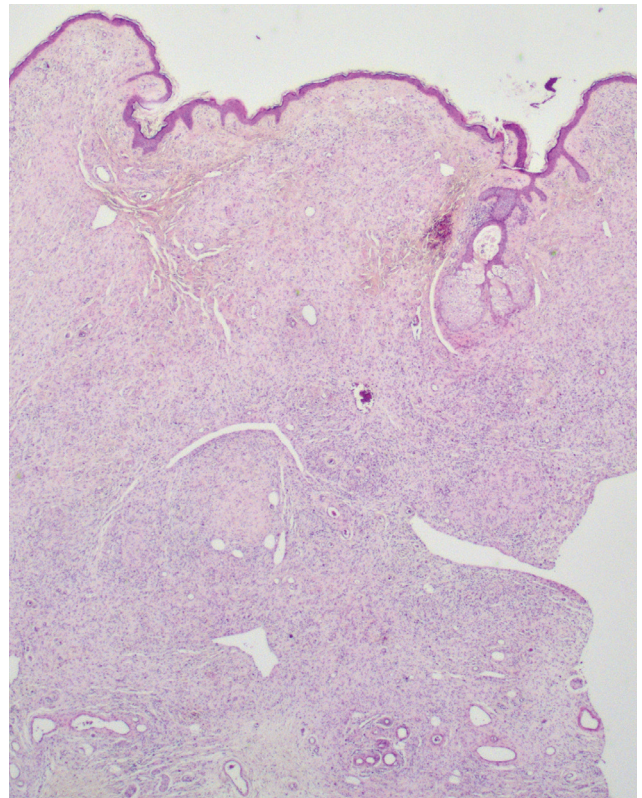


Figure 2 – On histopathological examination, we can observe numerous large nerve fascicles embedded in a cellular matrix containing abundant mucin as well as collagen, fibroblasts, and Schwann cells (HE, x16).

at the Dermatology clinic, with no changes in the tumor or development of other neoplasms.

Plexiform neurofibromas are benign tumors of the peripheral nerve sheath seen in approximately 30% of patients with NF1. They often develop within the first two to five years of life and are commonly seen on the craniofacial region, neck, and lower extremities. They grow most rapidly during childhood and adolescence and can cause significant morbidity because of pain, disfigurement, and

1. Dermatology Department. Hospital de Santa Maria. Centro Hospitalar Universitário Lisboa Norte. Lisbon. Portugal.

2. Dermatology University Clinic. Faculdade de Medicina. Universidade de Lisboa. Lisbon. Portugal.

✉ **Autor correspondente:** Catarina Correia. catarinacorreia03@gmail.com

Recebido/Received: 13/12/2022 - **Aceite/Accepted:** 21/03/2023 - **Publicado Online/Published Online:** 19/05/2023 - **Publicado/Published:** 04/12/2023

Copyright © Ordem dos Médicos 2023



local compression. Therefore, plexiform neurofibroma growth in adulthood warrants close surveillance for possible malignant transformation. Malignant progression is considered the leading cause of mortality, occurring in 2% to 16% of cases.^{1,2}

ACKNOWLEDGMENTS

The authors would like to thank João Pedro Vasconcelos of the Dermatology Department of the Centro Hospitalar Universitário Lisboa Norte for the photographs of the histopathological examination.

AUTHOR CONTRIBUTIONS

CC: Design of the work, data acquisition, and paper drafting.

MR, PF: Critical review of the manuscript.

REFERENCES

1. Fisher MJ, Blakeley JO, Weiss BD, Dombi E, Ahlawat S, Akshintala S, et al. Management of neurofibromatosis type 1-associated plexiform neurofibromas. *Neuro Oncol.* 2022;24:1827-44.
2. Ly KI, Blakeley JO. The diagnosis and management of neurofibromatosis type 1. *Med Clin North Am.* 2019;103:1035-54.

PROTECTION OF HUMANS AND ANIMALS

The authors declare that the procedures were followed according to the regulations established by the Clinical Research and Ethics Committee and to the Helsinki Declaration of the World Medical Association updated in 2013.

PATIENT CONSENT

Obtained.

COMPETING INTERESTS

The authors have declared that no competing interests exist.

FUNDING SOURCES

This research received no specific grant from any funding agency in the public, commercial, or not-for-profit sectors.