

## Case Report of a Challenging Diagnosis of Nasal Tuberculosis

### Caso Clínico de um Diagnóstico Desafiante de Tuberculose Nasal

**Keywords:** Antitubercular Agents/therapeutic use; Nose Diseases/drug therapy; Tuberculosis/diagnosis; Tuberculosis/drug therapy  
**Palavras-chave:** Antituberculosos/uso terapêutico; Doenças Nasais/tratamento farmacológico; Tuberculose/diagnóstico; Tuberculose/tratamento farmacológico

Dear Editor,

The incidence of tuberculosis (TB) has been steadily declining for the past two decades. However, since the beginning of the COVID-19 pandemic, the TB incidence rate is estimated to have increased.<sup>1</sup>

Although western Europe is considered a low TB incidence region, recent migration trends have called attention to its ongoing relevance, since ear, nose, and throat (ENT) manifestations, such as nasal and nasopharyngeal tuberculosis, are rare.<sup>2</sup>

We describe a clinical case of a 77-year-old white man presenting to the ENT clinic with a two-week history of right nasal obstruction and localized pain. Anterior rhinoscopy revealed a friable, erythematous crusting of the anterior right septal mucosa. A biopsy was done showing inflammatory exudate, ulceration, and no evidence of malignancy. The patient started oral antibiotics and corticosteroids, with limited improvement.

At re-assessment, an anterior septal friable perforation was seen, and a paranasal sinus computed tomography (CT) scan revealed thickening of the nasal vestibule and anterior nasal septum with irregularity of the right mucosa and septal perforation. Paranasal sinuses were clear and pneumatized. No bone lesions were found. Punch biopsy of the septal ulcer was repeated, confirming the ulcerative granulomatous lesion with caseating necrosis without vasculitic nor neoplastic features (Fig. 1A). No microorganisms were found.

An immune panel, a klebsiella nasal swab and an HIV test were negative.

At this point, a review of the patient's medical history disclosed an episode of ganglionic tuberculosis 30 years ago. The patient denied fever, weight loss or night sweats and chest CT was normal. The histopathologic review of the tissue sample taken previously was required and staining with Ziehl-Neelsen was positive for acid-alcohol resistant bacilli. The polymerase chain reaction (PCR) and culture test were positive for *Mycobacterium tuberculosis* (Fig. 1B).

The patient started antitubercular therapy with isoniazid, rifampin, ethambutol and pyrazinamide for four months, followed by two months of isoniazid and rifampin.

At the first- evaluation one month following treatment, the patient was clinically improved. Anterior septal perforation remained, which resulted in nasal tip ptosis.

Nasal tuberculosis is a rare entity, and clinical presentation with ulcerative and destructive features can mimic malignancy, emphasizing not only the need for biopsy, but also routine microbiology and appropriate culture tests, so that infectious causes are not overlooked, and treatment is not delayed.

The diagnosis is difficult, especially because it requires a high diagnostic suspicion and histological confirmation is hampered by lengthy and false negative results. In fact, smears of acid-fast bacilli and cultures tend to be negative in nasal tuberculosis.

Given the recent reversal in TB prevalence trends worldwide, physicians should bear in mind that, even though nasal tuberculosis is a challenging diagnosis, new diagnostic tools such as PCR or interferon- $\gamma$  assay can be extremely useful to achieve prompt results.<sup>3</sup>

#### AUTHOR CONTRIBUTIONS

JID: Conception and writing of the manuscript.

ANP: Writing and critical review of the manuscript.

FSV: Data collection.

SSC, LM: Critical review of the manuscript.

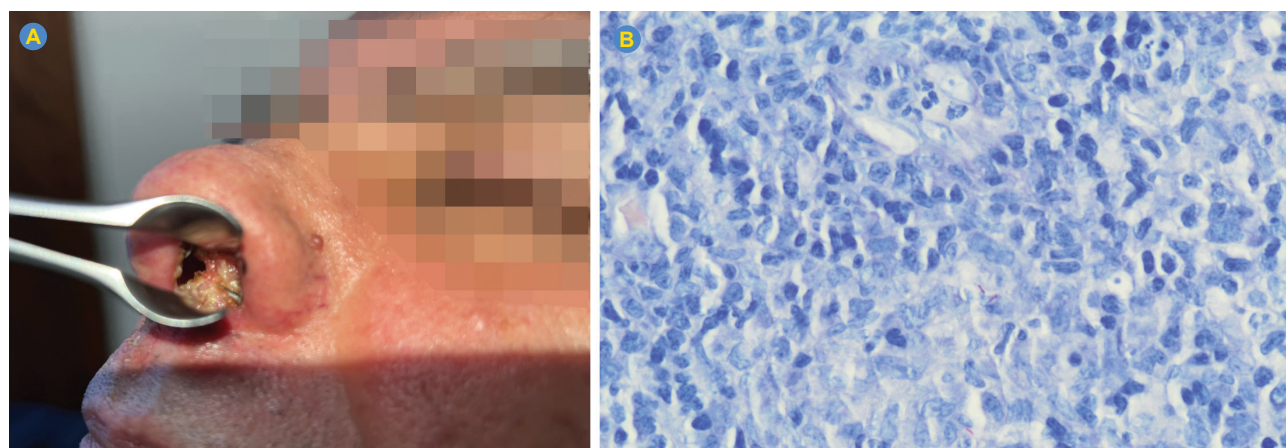


Figure 1 – (A) Anterior rhinoscopy revealing septal lesion; (B) Staining with Ziehl-Neelsen revealing acid-alcohol resistant bacilli (original magnification x600)

**PROTECTION OF HUMANS AND ANIMALS**

The authors declare that the procedures were followed according to the regulations established by the Clinical Research and Ethics Committee and to the Helsinki Declaration of the World Medical Association updated in 2013.

**DATA CONFIDENTIALITY**

The authors declare having followed the protocols in use at their working center regarding patients' data publication.

**REFERENCES**

1. World Health Organization. Global tuberculosis report 2022. Geneva: WHO; 2022.
2. Butt AA. Nasal tuberculosis in the 20th century. *Am J Med Sci.* 1997;313:332-5.
3. Masterson L, Srouji I, Kent R, Bath AP. Nasal tuberculosis-an update of current clinical and laboratory investigation. *J Laryngol Otol.* 2011;125:210-3.

**PATIENT CONSENT**

Obtained.

**COMPETING INTERESTS**

The authors have declared that no competing interests exist.

**FUNDING SOURCES**

This research received no specific grant from any funding agency in the public, commercial, or not-for-profit sectors.

Joana Ida DIAS<sup>✉1</sup>, Ana NÓBREGA PINTO<sup>1</sup>, Francisco SOUSA VIEIRA<sup>2</sup>, Luís MEIRELES<sup>1</sup>

1. Department of Otorhinolaryngology and Head and Neck Surgery, Centro Hospitalar Universitário do Porto. Porto, Portugal.

2. Department of Clinical Pathology, Centro Hospitalar Universitário do Porto. Porto, Portugal.

✉ Autor correspondente: Joana Ida Dias. [joanaidasousadias@gmail.com](mailto:joanaidasousadias@gmail.com)

Recebido/Received: 12/01/2023 - Aceite/Accepted: 04/05/2023 - Publicado Online/Published Online: 12/06/2023 - Publicado/Published: 03/07/2023

Copyright © Ordem dos Médicos 2023

<https://doi.org/10.20344/amp.19614>



## Unveiling the First *Staphylococcus argenteus* Infection in Portugal

### Descrição da Primeira Infecção por *Staphylococcus argenteus* em Portugal

**Keywords:** Portugal; Staphylococcal Infections; *Staphylococcus argenteus*

**Palavras-chave:** Infecções Estafilocólicas; Portugal; *Staphylococcus argenteus*

Dear Editor,

*Staphylococcus argenteus* is a novel species described in 2015, belonging to a divergent *Staphylococcus aureus* lineage.<sup>1</sup> Since then, the detection of *S. argenteus* infections increased worldwide, although it remains undistinguished from *S. aureus* by standard non-molecular methods.<sup>1-4</sup>

In December 2021, a 71-year-old man was admitted to the intensive care unit with respiratory failure associated with COVID-19 pneumonia. On day six of intubation, the tracheal aspirate was collected after the detection of purulent sputum associated with fever and increased systemic inflammatory markers.

At the microbiology laboratory, the bacteriological examination revealed a non-pigmented and greyish creamy colony with beta-haemolysis on blood agar (Fig. 1A) and a positive coagulase agglutination test. A putative *Staphylo-*

*coccus aureus* was initially identified (labelled as ULSM26) through the automated identification systems VITEK<sup>®</sup>MS (bioMérieux) and susceptibility testing was performed on Vitek<sup>®</sup>2 (bioMérieux) with the AST-P648 card. Penicillin and vancomycin susceptibility were assessed by disc diffusion and the agar gradient test, respectively, according to the EUCAST breakpoints. The genetic background of ULSM26 was assessed by *spa* typing and detection of *mecA*, *pvl* and other virulence determinants were carried out by PCR.<sup>5,6</sup>

A methicillin-susceptible *S. aureus* (MSSA), with non-multiresistant profile, except to penicillin and tetracycline, was reported and the patient received ceftriaxone with a favourable clinical evolution.

Molecular characterization identified a *spa* type t5078, associated with clonal complex 75 and suggestive of a *Staphylococcus argenteus* species, which was confirmed by NRPS gene amplification (Fig. 1B).<sup>1</sup> Neither *mecA*, *pvl*, or other virulence genes were detected on ULSM26, except the staphylococcal immune evasion cluster genes *sak* (staphylokinase) and *scn* (staphylococcal complement inhibitor).

Previous studies suggest that the frequency of health-care-associated infections, morbidity and mortality are comparable to those of *S. aureus*.<sup>2</sup> Although resistance rates seem to be lower in *S. argenteus*, penicillin-resistant strains are common and methicillin resistance is prevalent in Europe and Australia.<sup>3</sup> Furthermore, a wide variety of virulence