

Rare Presentation of Primary Hyperparathyroidism in a Young Woman

Apresentação Rara de Hiperparatiroidismo Primário numa Mulher Jovem

Isabel MONTENEGRO ARAÚJO¹, Ana Isabel BROCHADO¹, Inês BRANCO CARVALHO¹, Sofia MATEUS², António MARTINS BAPTISTA¹

Acta Med Port 2023 Nov;36(11):746-750 • <https://doi.org/10.20344/amp.19616>

ABSTRACT

Even though primary hyperparathyroidism (PHPT) is a common endocrine disorder, due to better and more regular screening, the usual presentation is only seen in less than 15% of cases of PHPT. The authors present the case of a young female patient with a previous medical history of depression and nephrolithiasis, with one year of bone pain, that had become progressively worse and disabling. In the initial work-up, several lytic bone lesions and moderate hypercalcemia were found, leading to admission of the patient in the Internal Medicine ward for investigation and treatment. The ensuing investigation revealed PHPT due to hyperfunctioning parathyroid adenoma. The patient underwent a parathyroidectomy and at the follow-up assessment two months after discharge, she reported no symptoms and a computer tomography scan showed regression of the lytic lesions. This case is a reminder that severe symptomatic PHPT, a rare form in developed countries nowadays, still exists, and even though it is a medical condition, collaboration with surgical specialties is necessary to ensure the best possible treatment and prognosis.

Keywords: Bone Diseases/etiology; Hypercalcemia; Hyperparathyroidism, Primary/complications

RESUMO

Embora o hiperparatiroidismo primário (HPTP) seja uma doença endócrina comum, com a evolução e a melhoria dos métodos de rastreio, a apresentação clássica é apenas observada em menos de 15% dos casos. Os autores apresentam o caso de uma jovem com antecedentes de síndrome depressiva e nefrolitíase, com história de um ano de dor óssea, incapacitante e de agravamento progressivo. Na avaliação inicial, é de realçar a deteção de lesões ósseas líticas graves e hipercalcemia moderada, o que levou ao internamento da doente para investigação e tratamento. O estudo seguinte possibilitou o diagnóstico de HPTP por adenoma da paratiroide hiperfuncionante. A doente foi submetida a paratiroidectomia e na reavaliação dois meses depois da alta apresentava-se assintomática e com regressão das lesões líticas na imagem de tomografia computadorizada. Este caso serve para relembrar que as manifestações muito sintomáticas de HPTP, embora raras nos países desenvolvidos, ainda existem e, que embora sejam quase sempre benignas, a abordagem multidisciplinar com as especialidades cirúrgicas é essencial para a melhor abordagem terapêutica e para um melhor prognóstico.

Palavras-chave: Doenças dos Ossos/etiologia; Hipercalcemia; Hiperparatiroidismo Primário/complicações

INTRODUCTION

Even though primary hyperparathyroidism (PHPT) is a common endocrine disorder that has been known for more than 100 years, its presentation has been changing over time, especially in the last four decades in developed countries.¹⁻³

Primary hyperparathyroidism is usually characterized by the presence of hypercalcemia and inappropriately normal or elevated parathyroid hormone (PTH) levels.^{3,4} It is more common in female patients.^{3,4} A few decades ago, the most common presentation was severe bone and kidney disease, but nowadays, due to increased testing for calcium and PTH levels, it is usually diagnosed in asymptomatic patients.^{1,2}

CLINICAL CASE

The authors present the case of a young female patient, 32 years old, who went to the Emergency Room (ER) in the previous year several times, due to bone pain and mobility impairment.

This patient had a medical history of nephrolithiasis, in

the last three years, with several episodes of renal colic. In addition, she was treated in the previous year for depression by her Family Physician. She had been prescribed an oral contraceptive pill and an anxiolytic drug on demand. Moreover, she had always been autonomous, and worked as a call-center operator.

In the last year, the patient came several times to the ER due to intense thoracic and lumbar pain, referring already to persisting generalized mild osteoarticular and muscular pain, associated with asthenia. In the last two weeks, the pain became progressively worse. She also reported nausea with vomiting, and polydipsia in the last few days. On the day of admission, she presented intense and completely disabling hip pain in the last three days, placing her in a wheelchair.

The physical examination showed dehydrated mucous membranes, pain on palpation of the 8th to 10th right ribs and pain during mobilization of the lower limbs. In addition, there was a small, painless, and mobile nodule on palpation of the anterior neck and a small, elastic, painless retroareolar

1. Departamento de Medicina Interna. Hospital Beatriz Ângelo. Loures. Portugal.

2. Departamento de Medicina Interna. Hospital CUF Torres Vedras. Torres Vedras. Portugal.

✉ Autor correspondente: Isabel Montenegro Araújo. isa.araujo013@gmail.com

Recebido/Received: 15/01/2023 - Aceite/Accepted: 28/03/2023 - Publicado Online/Published Online: 20/06/2023 - Publicado/Publicado: 02/11/2023

Copyright © Ordem dos Médicos 2023



nodule in the right breast. There were no other relevant findings to the case.

The arterial blood gas test presented high ionized calcium (1.99 mmol/L – Reference range 1.12 - 1.32 mmol/L); the initial blood tests confirmed moderate hypercalcemia (14.7 mg/dL – Reference range 8.6 - 10.0 mg/dL), high alkaline phosphatase (447.Ul/L – Reference range 35 – 105 Ul/L) and elevated C reactive protein (3 mg/dL – Reference range < 0.5 mg/dL). The complete blood count and

renal function were normal, without other relevant changes. The electrocardiogram was normal, in sinus rhythm with 76 beats per minute, without repolarization or QT interval changes.

The hip x-ray and computer tomography (CT) presented several lytic images in the iliac bones and femurs, with cortical thinning and associated soft tissue component – which suggested the possibility of secondary lesions (Figs.1 and 2).

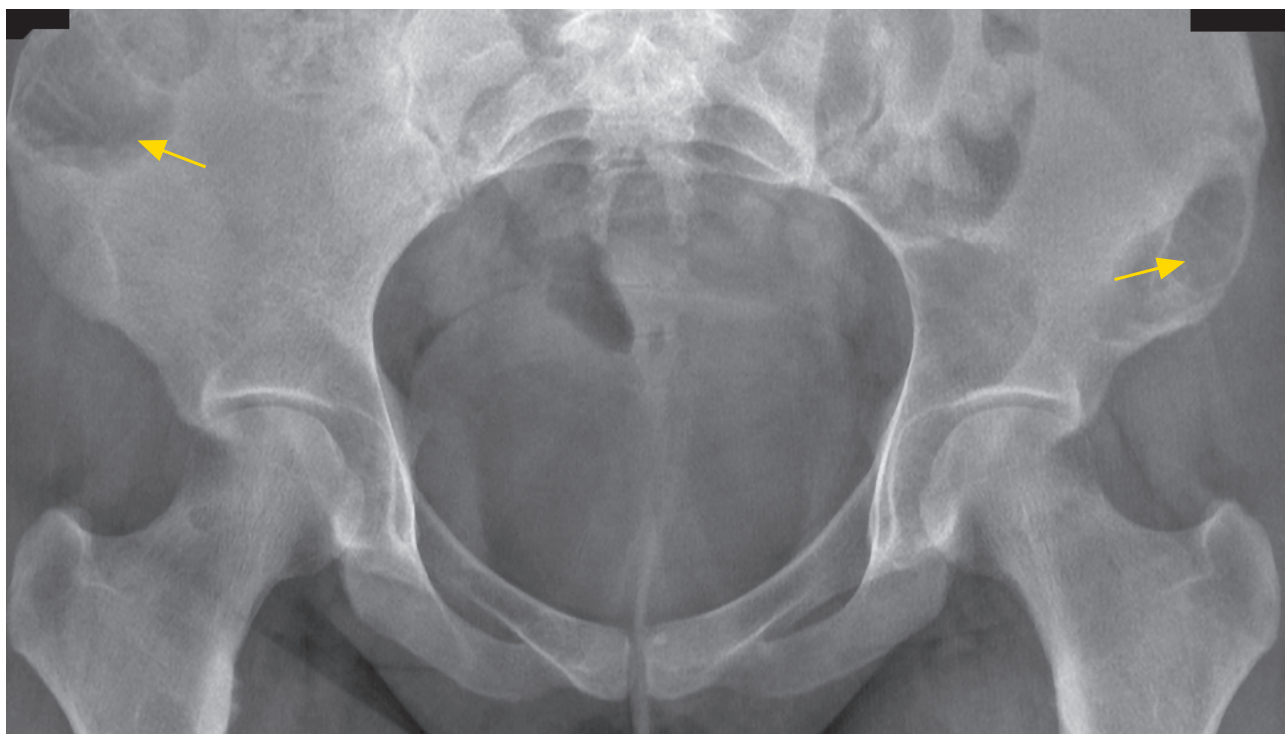

Figure 1 – Hip x-ray (yellow arrows – lytic bone lesions on iliac bone)

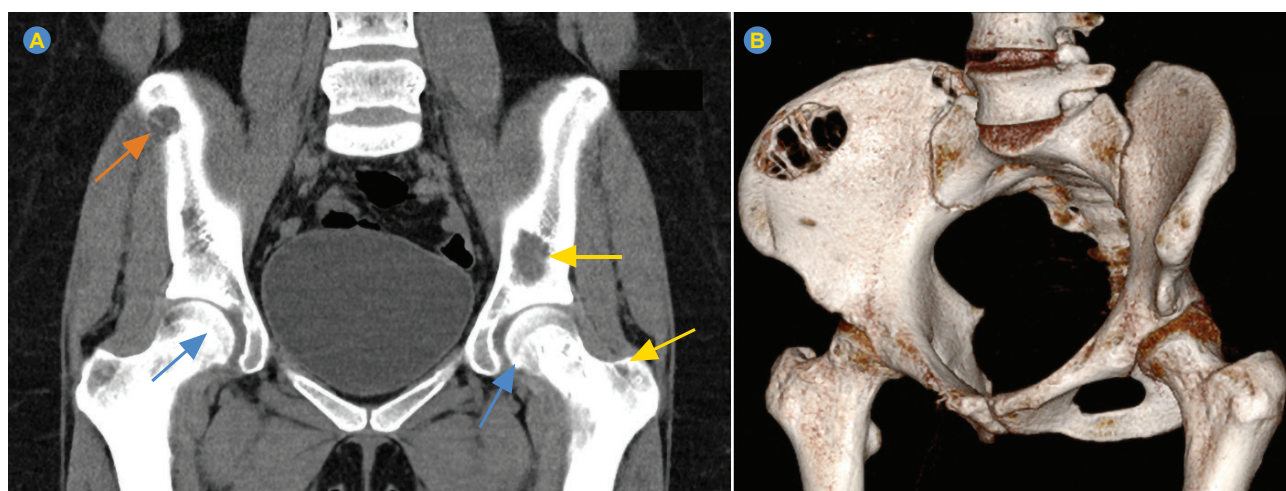


Figure 2 – (A) Hip CT (yellow arrows – lytic bone lesions on iliac bone and femurs; blue arrows – cortical thinning; orange arrow – soft tissue component) and (B) 3D reconstruction of hip CT images

The patient was admitted to the Internal Medicine ward to start a clinical investigation as well as symptomatic treatment.

Due to chronic, moderate, not very symptomatic hypercalcemia, intense fluid therapy was started, in addition to furosemide, analgesic therapy and bed rest.

The mammography and breast ultrasound showed a benign breast nodule. The neck ultrasound and aspiration biopsy suggested a nodule of the parathyroid gland. A full body CT showed no lesions suggestive of cancer or metastasis, other than a cervical nodule suggestive of a parathyroid gland nodular lesion and showed several scattered lytic bone lesions on the ribs, vertebral bones, scapula, and iliac bones. The head X-ray revealed a 'salt-and-pepper' pattern. The head CT presented several bone lesions, more indicative of brown tumors instead of lytic lesions (Fig. 3). The more complete blood tests showed hypophosphatemia and elevated levels of PTH (688 pg/mL – Reference range 15 – 65 pg/mL), with no other findings, namely no other endocrine or immunologic changes. This investigation allowed the diagnosis of symptomatic PHPT.

With the collaboration of General Surgery to help identify the precise location of the parathyroid nodule, the patient underwent a perfusion scintigraphy revealing hyperfunctioning parathyroid tissue, probably a parathyroid adenoma, of the right superior parathyroid gland. She underwent a parathyroidectomy, without any immediate intercurrents, presenting a drop higher than 50% in the values of PTH in the ten minutes after excision, meaning curative resec-

tion. The histological examination of the resected tissue confirmed the diagnosis of PHPT due to a hyperfunctioning parathyroid adenoma.

Finally, during the post-operative period, the patient presented hungry bone syndrome (persistent hypocalcemia post-op due to prolonged exposure to PTH, which leads to high bone turnover with bone resorption that suddenly shifts towards osteoblastic activity after the hormone removal),⁵ and required to start intravenous and oral calcium supplementation. After almost two months of hospital admission, the patient was released, only with oral calcium supplementation and an indication for physical rehabilitation.

At the two-month follow-up, lytic bone lesions were much smaller and less expressive in the CT, as expected (Fig. 4), and the patient fully recovered her functional capacity.

DISCUSSION

This case presents a young woman with two different but still interconnected pathological findings: osteolytic lesions and hypercalcemia.

The main concern about this initial presentation was the possibility that it was caused by cancer.⁴ However, in the presence of hypercalcemia and osteolytic lesions, other different diagnoses must be considered, and PHPT is one of them.

Fortunately, the full investigation revealed a benign condition, but with a presentation rarely seen nowadays – symptomatic PHPT, which is only present today in less than

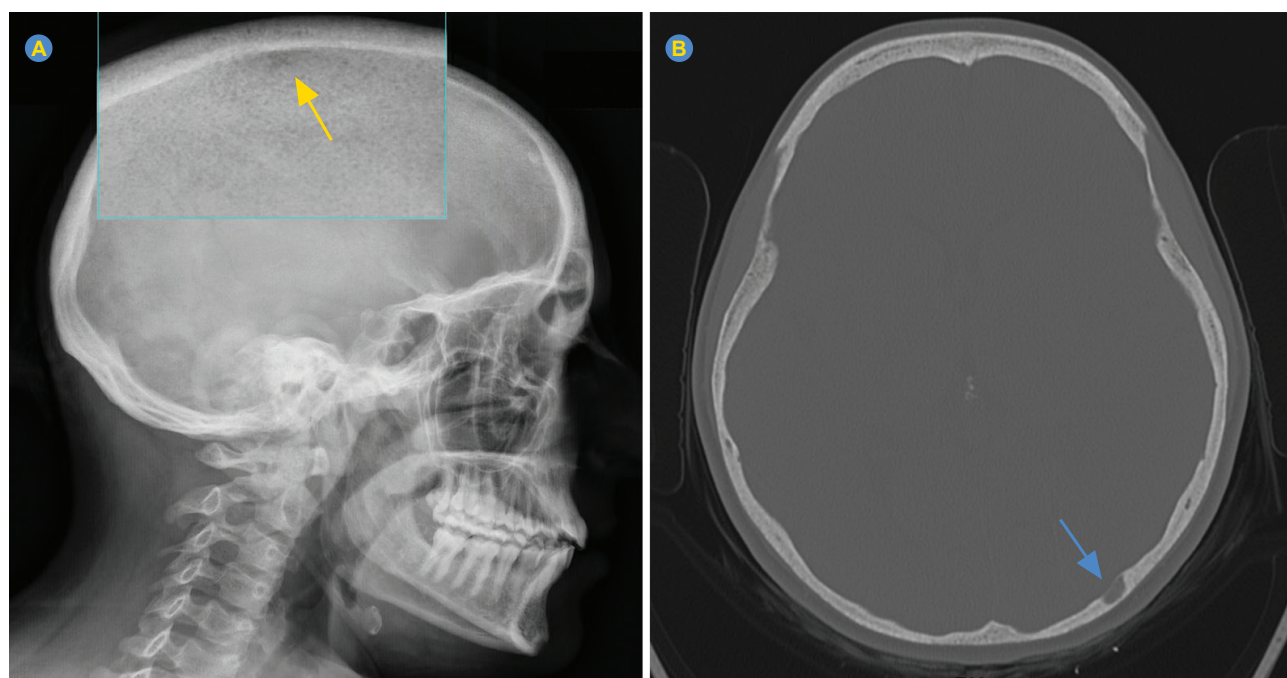


Figure 3 – (A) Head x-ray (yellow arrow – salt-and-pepper pattern) and (B) head CT (blue arrow – brown tumor)

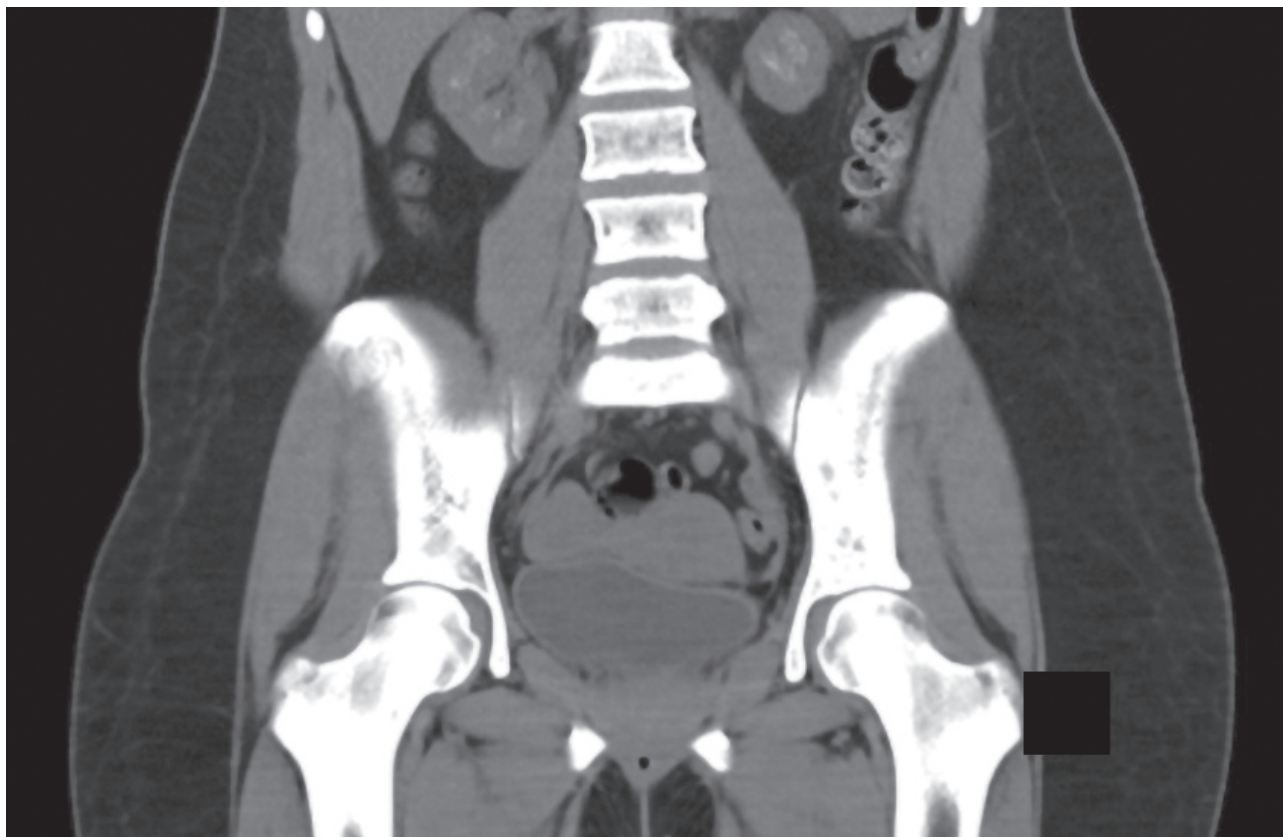

Figure 4 – Hip CT (two-month follow-up)

15% of PHPT patients.³

The ‘classic’ symptoms of PHPT target the bone and kidney.^{2,4,7} ‘Salt-and-pepper’ pattern skull demineralization, distal clavicle tapering, subperiosteal bone resorption, cysts, and brown tumors – together they are described as osteitis fibrosa cystica.^{2,4,6} The main renal complication is nephrolithiasis, being much more prevalent than in the normal population.^{2,4}

There are also neurocognitive changes (such as depression, fatigue, and anxiety)^{2,4} and effects in the cardiac and gastro-intestinal tract.⁴

After diagnosis, it was also possible to associate this disease with the patient’s history of kidney stones, fatigue, and depression for more than a year.

Parathyroidectomy of the hyperfunctioning parathyroid tissue is the curative approach^{2,4,6}; it is advised in younger patients with symptomatic PHPT or with severe hypercalcemia or renal disease.^{2-4,6}

After the surgical procedure, the identified gland hyperplasia was successfully removed, confirming the diagnosis of PHPT due to a hyperfunctioning single parathyroid gland, which is the most common cause of PHPT.^{3,4}

CONCLUSION

The aim of this article is to raise awareness to the fact that severe symptomatic PHPT still exists in developed countries, is an entity that should be considered every time hypercalcemia is found, and is mostly associated with skeletal and kidney disease. Despite being a medical condition, collaboration with surgical specialties is necessary to ensure the best possible treatment and prognosis.

PREVIOUS AWARDS AND PRESENTATIONS

This clinical case was presented as an Oral Communication at the 24th National Congress of Internal Medicine on May 30, 2018.

AUTHOR CONTRIBUTIONS

IMA: Draft, writing and critical review of the manuscript.
AIB: Writing and critical review of the manuscript.
IBC, AMB: Critical review of the manuscript.
SM: Study design and critical review of the manuscript.

PROTECTION OF HUMANS AND ANIMALS

The authors declare that the procedures were followed according to the regulations established by the Clinical Research and Ethics Committee and to the Helsinki

Declaration of the World Medical Association updated in 2013.

DATA CONFIDENTIALITY

The authors declare having followed the protocols in use at their working center regarding patients' data publication.

PATIENT CONSENT

Obtained.

REFERENCES

1. Ferraz-de-Sousa B. The evolution of primary hyperparathyroidism. Arch Endocrinol Metab. 2015;59:381-2.
2. Khan AA, Hanley DA, Rizzoli R, Bollerslev J, Young JE, Rejnmark L, et al. Primary hyperparathyroidism: review and recommendations on evaluation, diagnosis, and management. A Canadian and international consensus. Osteoporos Int. 2017;28:1-19.
3. Syed H, Khan A. Primary hyperparathyroidism: diagnosis and management in 2017. Pol Arch Intern Med. 2017;127:438-41.
4. Masi, L. Primary hyperparathyroidism. Front Horm Res Basel. 2019;51:1-12.
5. Cartwright C, Anastasopoulou C. Hungry bone syndrome. Treasure Island: StatPearls Publishing; 2021.
6. Makras P, Anastasilakis AD. Bone disease in primary hyperparathyroidism. Metabolism. 2018;79:64-76.
7. Walker MD, Silverberg SJ. Primary hyperparathyroidism. Nat Rev Endocrinol. 2018;14:115-25.

COMPETING INTERESTS

The authors have declared that no competing interests exist.

FUNDING SOURCES

This research received no specific grant from any funding agency in the public, commercial, or not-for-profit sectors.