

Morbihan Disease: A Diagnostic and Therapeutic Challenge

Doença de Morbihan: Um Desafio Diagnóstico e Terapêutico

Maria J. GUIMARÃES✉¹, Ana Gabriela LOPES¹, Ana Paula VIEIRA¹
Acta Med Port 2024 Feb;**37(2):145-146** • <https://doi.org/10.20344/amp.19904>

Keywords: Doxycycline; Facial Dermatoses; Rosacea
Palavras-chave: Dermatoses Faciais; Doxiciclina; Rosácea

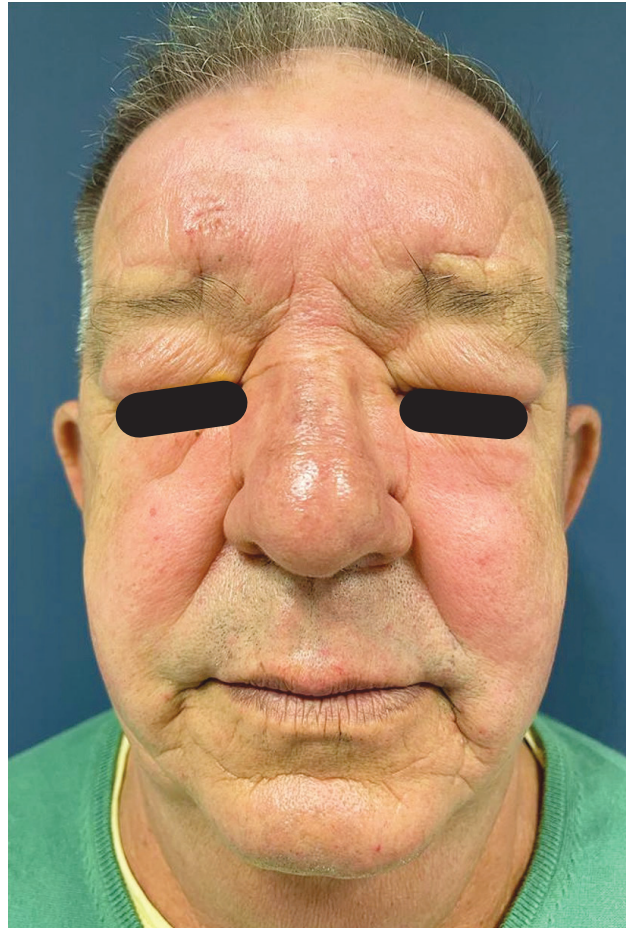

Figure 1 – Marked edema and erythema of the face, particularly the eyelids and upper face

A 64-year-old man presented with an initially transient but later persistent facial edema for the past five years.

Dermatological examination revealed poorly defined areas of erythema and non-pitting edema on the upper face and eyelids (Fig. 1). Laboratory and imaging studies were unremarkable. A skin biopsy revealed edema and superficial dermal vascular ectasia with mild lympho-histiocytic perivascular infiltrate with mast cells (Fig. 2), suggestive of

Morbihan disease.

Sequential treatment with isotretinoin (10 mg/day) and bilastine (20 mg/day) for four months followed by isotretinoin (20 mg/day) and prednisolone (10 mg/day) for three months was attempted, without significant benefit. Later on, doxycycline (100 mg/day) was initiated, with mild improvement after two months translating into a significant improvement in the quality of life.

1. Serviço de Dermatologia e Venereologia. Hospital de Braga. Braga. Portugal.

✉ **Autor correspondente:** Maria José Guimarães. mjcnhaguimaraes@gmail.com

Recebido/Received: 14/03/2023 - **Aceite/Accepted:** 26/05/2023 - **Publicado Online/Published Online:** 28/06/2023 - **Publicado/Published:** 01/02/2024
Copyright © Ordem dos Médicos 2024



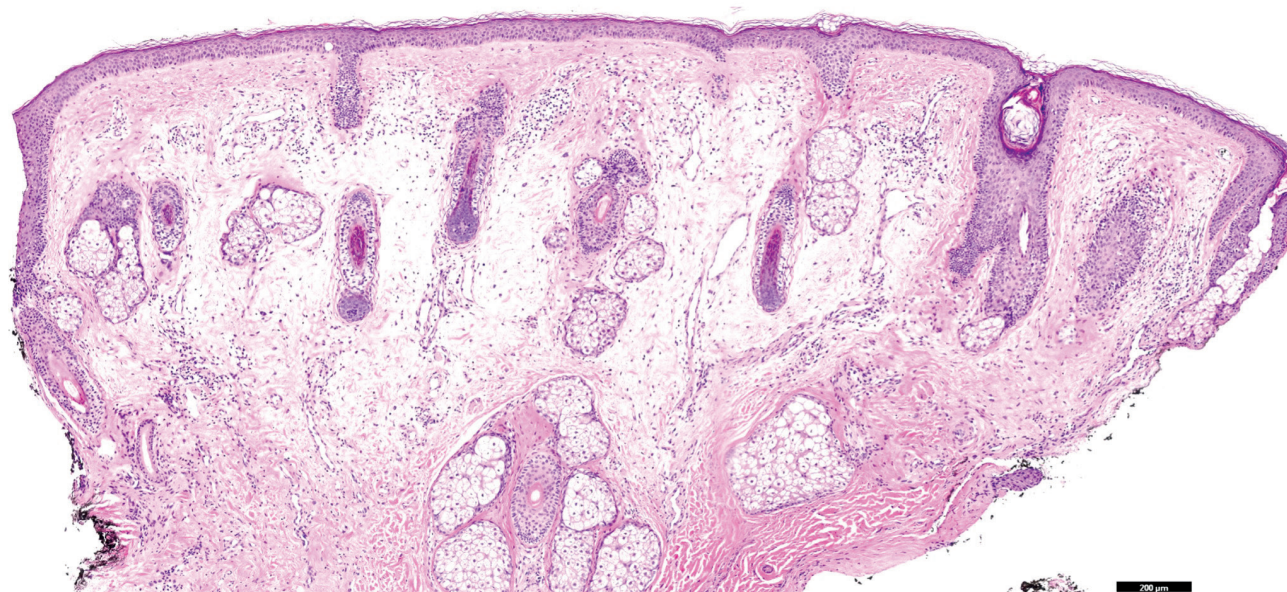


Figure 2 – Hematoxylin-eosin 50x – skin with marked edema of the upper half of the reticular dermis

Morbihan disease is considered a late stage of rosacea and is characterized by non-pitting facial edema.^{1,2} The lack of pathognomonic clinical or histopathological features makes this a challenging and frequently delayed diagnosis.³ Given its rarity, no guidelines are available regarding its management. Patients are generally treated with systemic corticosteroids, antibiotics, and/or isotretinoin, often with unsatisfactory results.^{1,4,5} Further studies are required to define an optimal therapeutic approach.

AUTHOR CONTRIBUTIONS

All authors contributed equally to this manuscript.

PROTECTION OF HUMANS AND ANIMALS

The authors declare that the procedures were followed according to the regulations established by the Clinical Research and Ethics Committee and to the Helsinki Declaration of the World Medical Association updated in 2013.

REFERENCES

1. Donthi D, Nenow J, Samia A, Phillips C, Papalas J, Prenshaw K. Morbihan disease: a diagnostic dilemma: two cases with successful resolution. *SAGE Open Med Case Rep.* 2021;9:2050313X211023655.
2. Smith LA, Cohen DE. Successful long-term use of oral isotretinoin for the management of morbihan disease: a case series report and review of the literature. *Arch Dermatol.* 2012;148:1395-8.
3. Veraldi S, Persico M, Francia C. Morbihan syndrome. *Indian Dermatol Online J.* 2013;4:122.
4. Fujimoto N, Mitsuru M, Tanaka T. Successful treatment of morbihan disease with long-term minocycline and its association with mast cell infiltration. *Acta Derm Venereol.* 2015;95:368-9.
5. Boparai RS, Levin AM, Lelli GJ. Morbihan disease treatment: two case reports and a systematic literature review. *Ophthalmic Plast Reconstr Surg.* 2019;35:126-32.

DATA CONFIDENTIALITY

The authors declare having followed the protocols in use at their working center regarding patients' data publication.

PATIENT CONSENT

Obtained.

COMPETING INTERESTS

The authors have declared that no competing interests exist.

FUNDING SOURCES

This research received no specific grant from any funding agency in the public, commercial, or not-for-profit sectors.