

COL4A1 and Intraventricular Hemorrhage

COL4A1 e Hemorragia Intraventricular

Laura LEITE DE ALMEIDA^{1,2}, Ana GRANGEIA^{2,3}, Luísa SAMPAIO^{2,4}, Ana VILAN^{2,5}
Acta Med Port (In Press) ▪ <https://doi.org/10.20344/amp.20515>

Keywords: Cerebral Hemorrhage/genetics; Collagen Type IV/genetics; Fetal Diseases/genetics; Infant, Newborn
Palavras-chave: Colagénio Tipo IV/genética; Doenças Fetais/genética; Hemorragia Cerebral/genética; Recém-Nascido

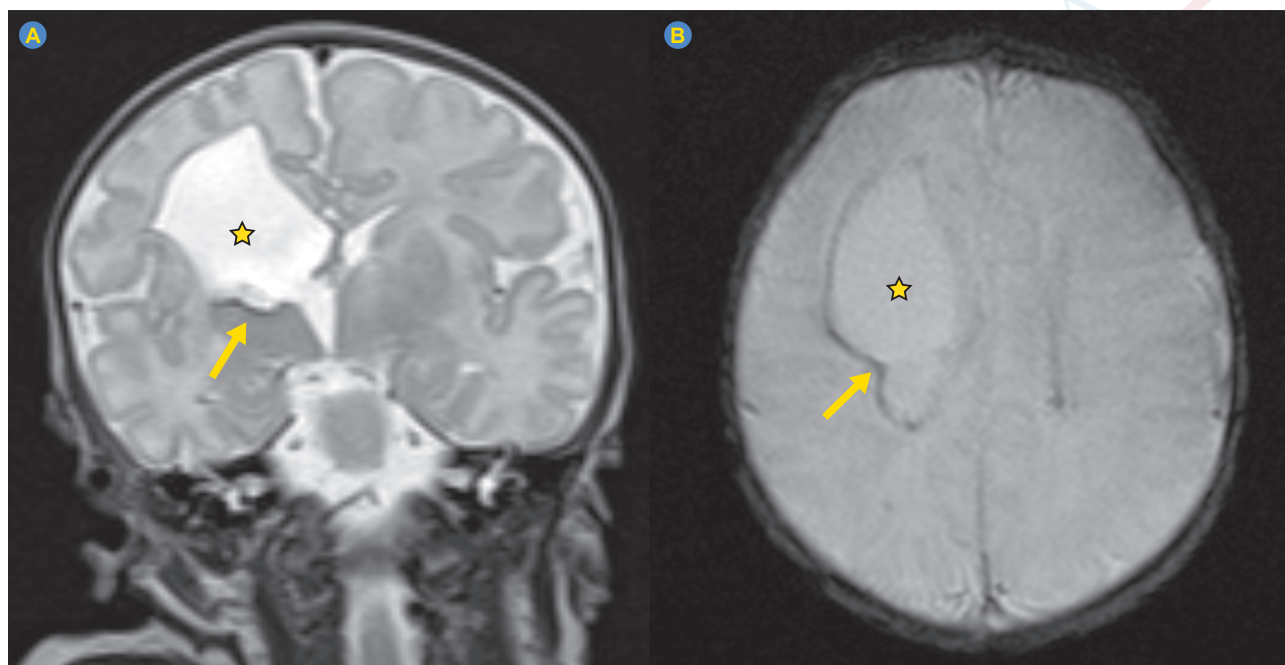


Figure 1 – Brain MRI. Coronal T2 weighted-image (WI) (A) and axial T2*-WI (B), depicting right frontal porencephalic cavity (star) with peripheral hemorrhagic residues (arrow)

A healthy primigravida with a 36-week gestation presented with fetal right ventriculomegaly. Magnetic resonance imaging (MRI) showed an encephaloclastic porencephaly and residual hemorrhagic components. Trauma, hypertension, TORCH infection and alloimmune thrombocytopenia were excluded. A caesarean section was planned and a term boy with normal platelet count and coagulation tests was delivered. Brain MRI confirmed the previous findings (Fig. 1). A heterozygous pathogenic variant (c.518G>A, p.Gly173Asp), maternally inherited, was identified in the *COL4A1* gene. Abdominal and cardiac ultrasound were normal. At three years old the child presented left hemiparesis, inaugural epilepsy, and strabismus with no retinal arterial tortuosity or cataract.

Collagen type IV alpha 1 (*COL4A1*) is a structural component of the vascular basement membrane of many tissues. Its fragility can trigger rupture and intrauterine intraventricular hemorrhage, leading to porencephaly and neurological symptoms, like hemiparesis and epilepsy, which were previously unexplained.¹⁻³ Early diagnosis allowed an appropriate follow-up and genetic counseling.

1. Serviço de Pediatria. Centro Hospitalar Universitário de São João. Porto. Portugal.
2. Faculdade de Medicina. Universidade do Porto. Porto. Portugal.
3. Serviço de Genética Médica. Centro Hospitalar Universitário de São João. Porto. Portugal.
4. Serviço de Neurorradiologia. Centro Hospitalar Universitário de São João. Porto. Portugal.
5. Serviço de Neonatologia. Centro Hospitalar Universitário de São João. Porto. Portugal.

✉ **Autor correspondente:** Laura Leite de Almeida. analaurlalmeida@gmail.com

Recebido/Received: 21/08/2023 - **Aceite/Accepted:** 06/12/2023 - **Publicado Online/Published Online:** 29/05/2024

Copyright © Ordem dos Médicos 2024



AUTHOR CONTRIBUTIONS

LLA: Data collection, literature search and drafting of the manuscript.

AG: Critical review of the manuscript.

LS: Data collection and analysis.

AV: Data collection, literature search and critical review of the manuscript.

PROTECTION OF HUMANS AND ANIMALS

The authors declare that the procedures were followed according to the regulations established by the Clinical Research and Ethics Committee and to the Helsinki Declaration of the World Medical Association updated in 2013.

DATA CONFIDENTIALITY

The authors declare having followed the protocols in use at their working center regarding patients' data publication.

PATIENT CONSENT

Obtained.

COMPETING INTERESTS

The authors have declared that no competing interests exist.

FUNDING SOURCES

This research received no specific grant from any funding agency in the public, commercial, or not-for-profit sectors.

REFERENCES

1. Lanfranconi S, Markus HS. COL4A1 mutations as a monogenic cause of cerebral small vessel disease: a systematic review. *Stroke*. 2010;41:e513-8.
2. Plaisier E, Ronco P. COL4A1-related disorders. In: Adam MP, Mirzaa GM, Pagon RA, Wallace SE, Bean LJ, Gripp KW, et al, editors. *GeneReviews*®. Seattle: University of Washington; 2009.
3. Vahedi K, Alamowitch S. Clinical spectrum of type IV collagen (COL4A1) mutations: a novel genetic multisystem disease. *Curr Opin Neurol*. 2011;24:63-8.