

## Cholecystocutaneous Fistula Secondary to Cholelithiasis: A Case Report

### Fístula Colecistocutânea Secundária a Litíase Biliar: Um Caso Clínico

**Keywords:** Biliary Fistula/diagnostic imaging; Cholelithiasis/complications; Cutaneous Fistula/diagnostic imaging; Gallbladder Diseases/diagnosis

**Palavras-chave:** Colelitíase/complicações; Doenças da Vesícula Biliar/diagnóstico; Fístula Biliar/diagnóstico por imagem; Fístula Cutânea/diagnóstico por imagem

Dear Editor,

Cholecystocutaneous fistula is a rare but potentially serious complication of acute cholecystitis. It may arise as a result of untreated gallbladder inflammation or previous surgical interventions. Abnormal communication between the gallbladder and the skin leads to the drainage of bile to the skin surface, which increases the risk of infections and sepsis.<sup>1-3</sup>

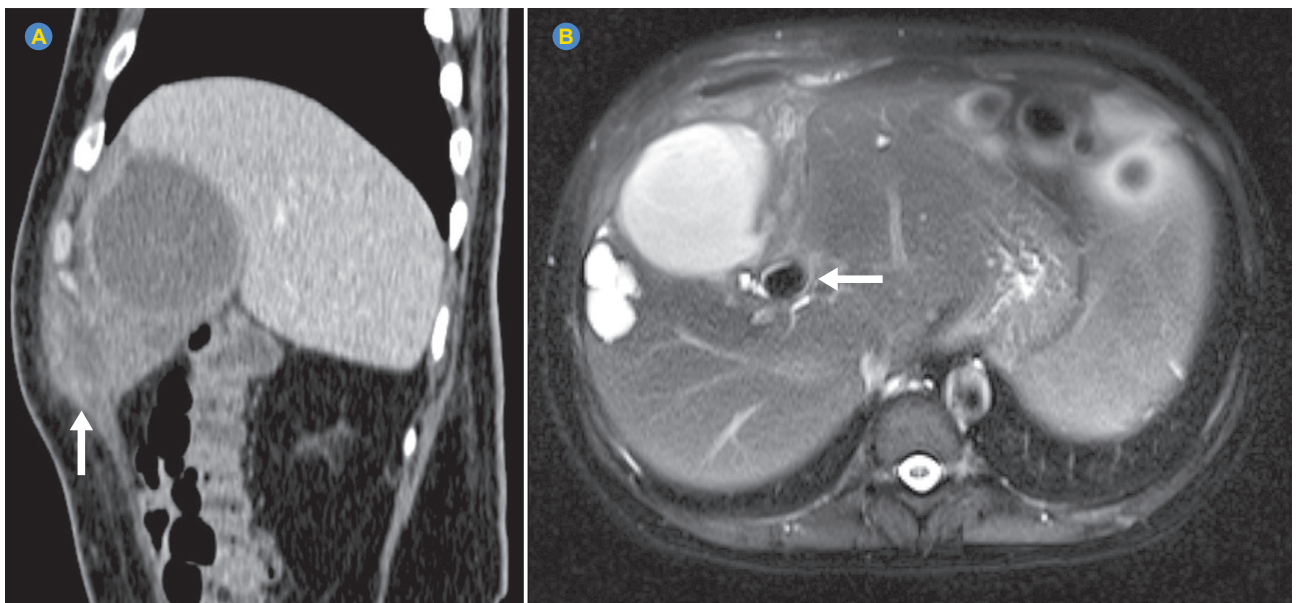
We describe the case of a 58-year-old male patient referring intense and persistent abdominal pain in the right hypochondrium and flank, accompanied by a high fever that persisted for more than a week. He reported no other significant complaints or symptoms. The physical examination revealed pain on superficial palpation of the right hemiabdomen, which limited the evaluation. Due to this limitation, computed tomography (CT) was requested. The test revealed a fluid collection with approximately 300 mL of volume in the abdominal cavity in the location of the gallbladder and invading the abdominal wall (Fig. 1A). A subsequent magnetic resonance cholangiopancreatography (MRCP) was requested for a more precise assessment of the bile

ducts, identifying an abscess in the gallbladder region in contact with the proximal portion of the cystic duct (Fig. 1B). Additionally, the presence of obstructive lithiasis was observed in the distal third of the cystic duct measuring 1.8 cm, compatible with infected cholecystitis (abscess) with fistulization to the abdominal wall. The treatment consisted of drainage of the abdominal collection guided by CT, in addition to the administration of appropriate antibiotic therapy to control the infection.

A cholecystocutaneous fistula can arise as a result of different underlying conditions. The most common cause is cholelithiasis, that is, the development of gallstones in the gallbladder. These stones can damage the gallbladder wall over time, leading to the development of an abnormal pathway between the gallbladder and the skin. Additionally, chronic inflammation of the gallbladder (cholecystitis) can also contribute to the development of this fistula.<sup>4,5</sup>

The accurate diagnosis of a cholecystocutaneous fistula is essential to determine the most appropriate treatment strategy. However, a detailed clinical history, physical examination, and imaging tests, such as ultrasound and CT, are essential. The presence of symptoms such as persistent abdominal pain, drainage of bile fluid through the skin, and fever are strongly suggestive of a fistula.<sup>3</sup>

Other causes include complications after gallbladder surgery such as cholecystectomy (gallbladder removal), abdominal trauma, infections, and inflammatory bowel disease. Patients with a history of biliary disease, previous abdominal surgeries, and recurrent infections may be at greater risk of developing this condition.<sup>1,2</sup>



**Figure 1** – CT scan with contrast in the portal phase in the axial view (A) demonstrating abscess in the abdominal cavity at the location of the gallbladder invading the abdominal wall (white arrow). MRCP in the T2 FAT SAT sequence in the axial view (B) showing abscess in the gallbladder region which is in contact with the proximal portion of the cystic duct, in addition to obstructive lithiasis in the distal third of the duct cystic (white arrow), compatible with infected cholecystitis with fistulization to the abdominal wall.

**AUTHOR CONTRIBUTIONS**

All authors contributed equally to this manuscript and approved the final version to be published.

**PROTECTION OF HUMANS AND ANIMALS**

The authors declare that the procedures were followed according to the regulations established by the Clinical Research and Ethics Committee and to the Helsinki Declaration of the World Medical Association updated in 2013.

**DATA CONFIDENTIALITY**

The authors declare having followed the protocols in use at their working center regarding patients' data publication.

**REFERENCES**

1. Ramia JM, de la Plaza R, López Marcano A, Ramiro C, Valenzuela Torres JC. Fistula colecistocutânea y fistula colecistocolédociana (Mirizzi II). *Gastroenterol Hepatol*. 2016;39:599-600.
2. Brimo Alsaman MZ, Mazketly M, Ziadeh M, Aleter O, Ghazal A. Cholecystocutaneous fistula incidence, etiology, clinical manifestations, diagnosis and treatment. A literature review. *Ann Med Surg*. 2020;59:180-5.
3. Gossage J, Forshaw M, Stephenson J, Mason R. Spontaneous cholecysto-cutaneous fistula. *J Surg*. 2004;2:52-3.
4. Surya M, Soni P, Nimkar K. Spontaneous cholecysto-cutaneous fistula draining through an old abdominal surgical scar. *Pol J Radiol*. 2016;81:498-501.
5. Singh A, Bansal S. Human gall-bladder communicating with skin: rare anatomical swerve. *J Clin Diagn Res*. 2013;7:2321-2.

Carutia Araujo SOARES<sup>1</sup>, Márcio Luís DUARTE<sup>2</sup>, Marcelo de Queiroz Pereira da SILVA<sup>3</sup>

1. Department of Internal Medicine. Universidade de Ribeirão Preto (UNAERP) - Campus Guarujá. Guarujá. Brazil.

2. Department of Radiology. Universidade de Ribeirão Preto (UNAERP) - Campus Guarujá. Guarujá. Brazil.

3. Department of Radiology. Webimagem Telerradiologia. São Paulo. Brazil.

✉ **Autor correspondente:** Márcio Luís Duarte. [marcioluisduarte@gmail.com](mailto:marcioluisduarte@gmail.com)

**Recebido/Received:** 25/09/2023 - **Aceite/Accepted:** 08/01/2024 - **Publicado/Published:** 01/04/2024

Copyright © Ordem dos Médicos 2024

<https://doi.org/10.20344/amp.20726>

