

Mediastinal Enlargement in an 8-Year-Old Child: What Could Be Causing It?

Alargamento do Mediastino numa Criança de 8 Anos: Quais as Possíveis Causas?

Inês Isabel AIRES MARTINS¹, Bárbara COSTA CORREIA², Sofia Alexandra MORAIS PIMENTA², Ana Clara GOMES GRACIO DOS REIS²

Acta Med Port 2024 Apr;37(4):289-290 • <https://doi.org/10.20344/amp.20727>

Keywords: Child; Mediastinal Cyst/diagnostic imaging

Palavras-chave: Criança; Quisto do Mediastino/diagnóstico por imagem

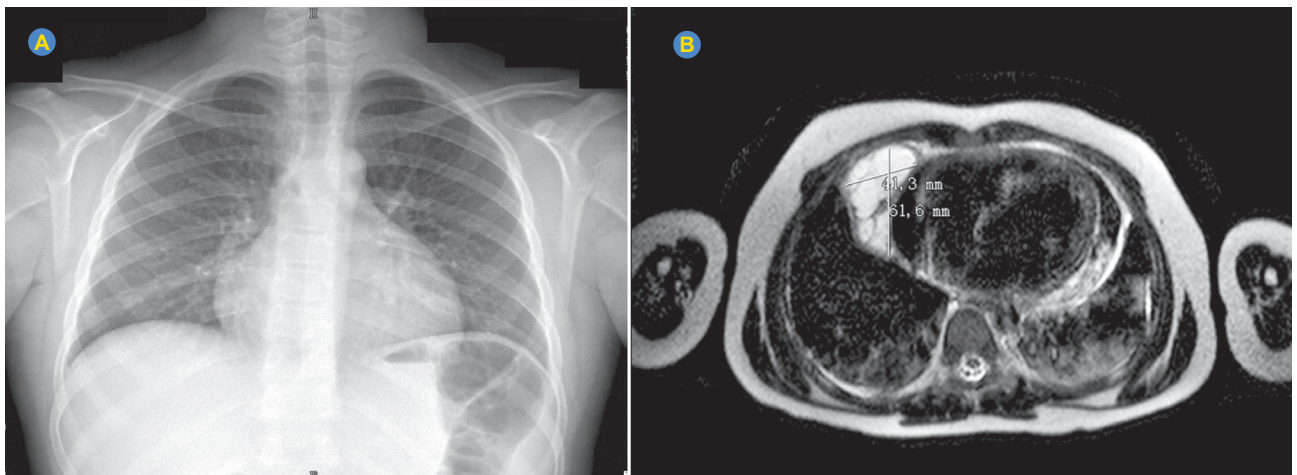


Figure 1 – Enlargement of the mediastinum in the chest radiography (A). MRI showing pericardial cyst in the right hemithorax, measuring 61.6 x 41.3 mm (B).

An 8-year-old boy presented to the Emergency Department with a persistent cough and right-sided chest pain. Physical examination was normal. Imaging tests revealed mediastinal enlargement on chest radiography (Fig. 1A), a 62 mm cystic lesion in close proximity to the pericardium on computed tomography, and an echocardiogram showed a small pericardial effusion. The magnetic resonance imaging test then confirmed a 62 mm pericardial cyst (Fig. 1B). Blood tests including inflammation markers and cardiac biomarkers were normal. Further tests including immunologic assays and tuberculosis screening were unremarkable. Pericardial cysts have an incidence of 1 in 100 000, accounting for 6% of mediastinal masses.¹ They are usually congenital and asymptomatic, often incidentally detected during imaging.^{1,2} Most are benign, prompting a conservative approach, but symptomatic or rapidly enlarging cysts may require surgery.^{1,3} In this case, conservative management was chosen, and the patient remained stable after eight months of follow-up.

AUTHOR CONTRIBUTIONS

IIAM: Study design, literature search, data acquisition, writing of the manuscript.

BCC: Data acquisition, critical review of the manuscript.
SAMP, ACGGR: Critical review of the manuscript.

PROTECTION OF HUMANS AND ANIMALS

The authors declare that the procedures were followed according to the regulations established by the Clinical Research and Ethics Committee and to the Helsinki Declaration of the World Medical Association updated in 2013.

DATA CONFIDENTIALITY

The authors declare having followed the protocols in use at their working center regarding patients' data publication.

PARENTAL CONSENT

Obtained.

1. Pediatrics Department. Centro Materno-Infantil do Norte Albino Aroso. Centro Hospitalar Universitário do Porto. Porto. Portugal.

2. Pediatrics and Neonatology Department. Centro Hospitalar do Tâmega e Sousa. Guilhufe. Portugal.

✉ **Autor correspondente:** Inês Isabel Aires Martins. inesairesmartins@gmail.com

Recebido/Received: 25/09/2023 - **Aceite/Accepted:** 08/11/2023 - **Publicado/Published:** 01/04/2024

Copyright © Ordem dos Médicos 2024



COMPETING INTERESTS

The authors have declared that no competing interests exist.

FUNDING SOURCES

This research received no specific grant from any funding agency in the public, commercial, or not-for-profit sectors.

REFERENCES

1. Alkharabsheh S, Gentry Iii JL, Khayata M, Gupta N, Schoenhagen P, Flamm S, et al. Clinical features, natural history, and management of pericardial cysts. *Am J Cardiol.* 2019;123:159-63.
2. Bezgin T, Elveran A, Varol S, Dogan C, Karagoz A, Esen AM. Pericardial cyst. *Herz.* 2014;39:1005-7.
3. Carmona-Ruiz HA, Orihuela-Rodríguez O, Morales-Gudiño I. Asymptomatic giant pericardial cyst. *Cir Cir.* 2021;89:s68-71.