


Unusual Presentation of Kaposi Sarcoma Mimicking Pyogenic Granuloma in an Immunocompetent Patient

Apresentação Incomum de Sarcoma de Kaposi Semelhante a Granuloma Piogénico num Doente Imunocompetente

José RAMOS ¹, Hugo LEME ¹, Joana NOGUEIRA²
Acta Med Port (In Press) • <https://doi.org/10.20344/amp.23544>

Keywords: Granuloma, Pyogenic; Sarcoma, Kaposi

Palavras-chave: Granuloma Piogénico; Sarcoma de Kaposi

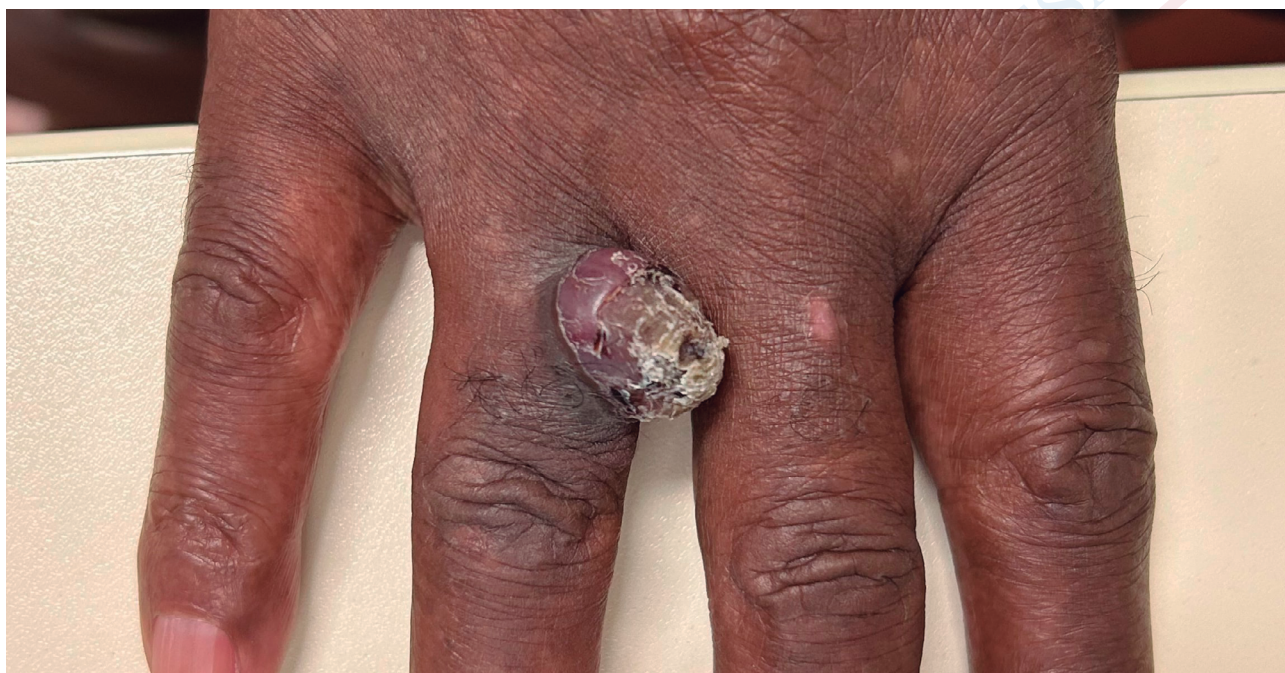

Figure 1 – Violaceous, hyperkeratotic nodule on the fourth digit of the right hand

A 76-year-old Angolan man presented with a three-month history of a violaceous nodule on the fourth digit of the right-hand, with occasional bleeding (Fig. 1). No other mucocutaneous lesions were noted. A clinical diagnosis of pyogenic granuloma was suspected, and the lesion was partially removed by shaving. However, the histopathological examination, supported by immunohistochemistry (CD34+, human herpesvirus-8+), revealed Kaposi sarcoma (KS). Human immunodeficiency virus (HIV) serology was negative and systemic involvement was excluded. Given that it was a solitary lesion, complete excision of the lesion was subsequently performed.

This case represents an endemic variant of KS in an immunocompetent, HIV-negative African patient. Pyogenic granuloma-like KS is a rare presentation that may mimic benign vascular lesions, especially in unusual locations like the hand.¹

Clinicians should consider KS in the differential diagnosis of solitary vascular lesions, even in immunocompetent individuals from endemic regions. Early histological assessment is essential to avoid diagnostic delay, especially when clinical features are atypical.

ACKNOWLEDGMENTS

The authors have declared that no AI tools were used during the preparation of this work.

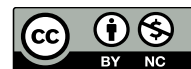1. Dermatovenereology Department. Unidade Local de Saúde Almada-Seixal. Almada. Portugal.

2. Pathology Department. Unidade Local de Saúde Almada-Seixal. Almada. Portugal.

 **Autor correspondente:** José Ramos. j.aramos@campus.ul.pt

Recebido/Received: 01/07/2025 - **Aceite/Accepted:** 23/10/2025 - **Publicado Online/Published Online:** 17/11/2025

Copyright © Ordem dos Médicos 2025



AUTHOR CONTRIBUTIONS

JR: Data collection, literature review, drafting of the manuscript.

HL: Literature review, critical review of the manuscript.

JN: Data analysis, critical review of the manuscript.

All authors approved the final version to be published.

PROTECTION OF HUMANS AND ANIMALS

The authors declare that the procedures were followed according to the regulations established by the Clinical Research and Ethics Committee and to the Helsinki Declaration of the World Medical Association updated in October 2024.

DATA CONFIDENTIALITY

The authors declare having followed the protocols in use at their working center regarding patients' data publication.

PATIENT CONSENT

Obtained.

CONFLICTS OF INTEREST

The authors have no conflicts of interest to declare.

FUNDING SOURCES

This research received no specific grant from any funding agency in the public, commercial, or not-for-profit sectors.

REFERENCES

1. Reznitsky C, Resnik SR, Calame A, Erickson CP, Resnik BI. An unusual case of pyogenic granuloma-like Kaposi sarcoma. Dermatol Online J. 2021;27:13030/qt3rw719np.