

Obstruction of Transplanted Kidney from Urinary Catheter Misplacement

Obstrução de Aloenxerto Renal Secundária a Sonda Vesical Mal Posicionada

Vítor FERNANDES ^{✉1}, Joana ANDRADE LOPES ¹, Alberto COSTA SILVA ²
Acta Med Port (In Press) • <https://doi.org/10.20344/amp.23634>

Keywords: Incidental Findings; Kidney Transplantation; Urinary Catheterization/adverse effects

Palavras-chave: Achados Incidentais; Cateterização Urinária/efeitos adversos; Transplante de Rim

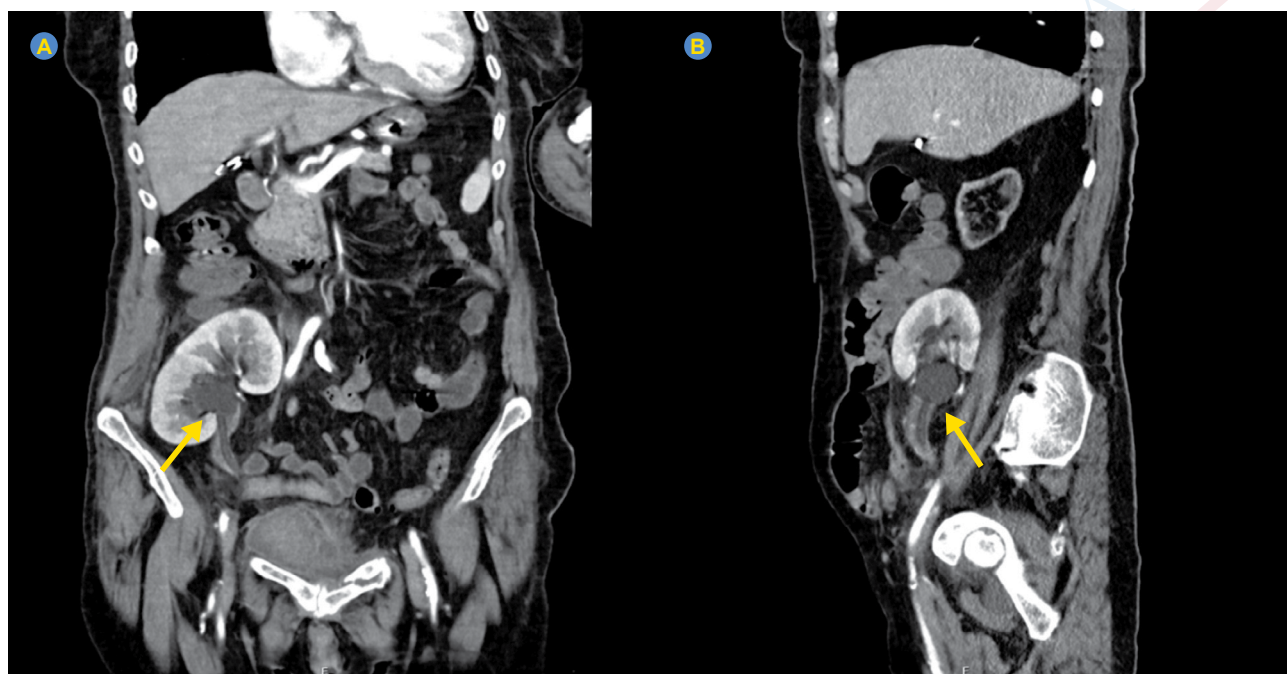


Figure 1 – Indwelling urinary catheter within the renal pelvis. The arrow indicates the catheter balloon.

A 71-year-old woman was admitted for an infected pelvic hematoma, 11 years post-kidney transplant. Baseline renal function was stable (serum creatinine 1.2 mg/dL). Following urinary catheterization, she developed progressive oliguria, with creatinine rising to 3.4 mg/dL.

Computed tomography imaging revealed malposition of the indwelling urinary catheter, which had been inadvertently inserted into the renal pelvis of the transplanted kidney (Fig. 1). No hydronephrosis was present on admission. Ultrasound-guided catheter replacement promptly led to resolution of oliguria and hydronephrosis, with recovery of kidney function to baseline.

This case highlights a rare but serious complication of urinary catheterization in kidney transplant recipients. Unlike prior reports identifying pre-existing hydronephrosis as a risk factor, this occurred in the absence of structural abnormalities.¹ However, iliac fossa allograft placement with ureteroneocystostomy can result in altered anatomy, potentially predisposing to catheter misplacement. A simple preventive maneuver is a slight catheter withdrawal after balloon inflation to ensure correct bladder positioning.²

¹. Nephrology Department. Unidade Local de Saúde São João. Porto. Portugal.

². Urology Department. Unidade Local de Saúde São João. Porto. Portugal.

✉ **Autor correspondente:** Vítor Fernandes. vita_fnds@hotmail.com

Revisão por/Reviewed by: Carla Nicolau

Recebido/Received: 03/07/2025 - **Aceite/Accepted:** 23/09/2025 - **Publicado Online/Published Online:** 22/10/2025

Copyright © Ordem dos Médicos 2025



ACKNOWLEDGMENTS

The authors have declared that no AI tools were used during the preparation of this work.

AUTHOR CONTRIBUTIONS

VF, JAL: Study design, data analysis and interpretation, writing and critical review of the manuscript.

ACS: Data collection, critical review of the manuscript.

All authors approved the final version to be published.

PROTECTION OF HUMANS AND ANIMALS

The authors declare that the procedures were followed according to the regulations established by the Clinical Research and Ethics Committee and to the Helsinki Declaration of the World Medical Association updated in October 2024.

DATA CONFIDENTIALITY

The authors declare having followed the protocols in use at their working center regarding patients' data publication.

PATIENT CONSENT

Obtained.

COMPETING INTERESTS

VF and ACS received payment or honoraria for lectures, presentations, speakers' bureaus, manuscript writing or educational events from AstraZeneca.

JAL received payment or honoraria for lectures, presentations, speakers' bureaus, manuscript writing or educational events from Takeda - Farmacêuticos Portugal, Lda.; received support for attending meetings or travel from Bayer Portugal, Lda., and A Menarini Portugal Farmacêutica, S.A.

FUNDING SOURCES

This research received no specific grant from any funding agency in the public, commercial, or not-for-profit sectors.

REFERENCES

1. Bradley A, Sozener C. Incidentally discovered foley catheter placement into a transplanted kidney. Urology. 2015;86:e11-2.
2. European Association of Urology Nurses. Evidence-based guidelines for best practice in urological health care: indwelling catheterisation. 2024. [cited 2025 Aug 17]. Available from: <https://nurses.uroweb.org/wp-content/uploads/EAUN-Guideline-indwelling-catheterisation-2024.pdf>.