

PULMONAR VASCULAR CHANGES IN THE PLAIN CHEST FILM OF CARDIAC PATIENTS

J. MARTINS PISCO

Serviço de Radiologia Hospital de Santa Marta. Lisboa.

SUMMARY

The correct interpretation of chest film on cardiac patients is very important. The most important feature is the radiographic appearance of the pulmonary vascularity. Four different patterns of pulmonary vascularity are considered: normal, decreased, increased and uneven. The different diseases associated with each type are mentioned. From the pulmonary vascular pattern one can deduct hemodynamic data which are important for the diagnosis, grade of severity and follow-up.

RESUMO

Alteração da vascularização pulmonar na radiografia do tórax de doentes cardíacos

É da maior importância a interpretação correcta da radiografia do tórax de doentes cardíacos. O factor mais importante é o aspecto radiográfico da vascularização pulmonar. Consideram-se 4 tipos de vascularização pulmonar: normal, diminuída, aumentada e desigual. Menciona-se as diferentes cardiopatias associadas com cada um dos 4 tipos. A partir do padrão de vascularização pulmonar podem deduzir-se dados hemodinâmicos que são factores importantes para o diagnóstico, grau de gravidade e evolução.

INTRODUCTION

The pulmonary vascularity in a patient with heart disease reflects the underlying pathophysiology and hemodynamics. The importance of the pulmonary vascularity cannot be overestimated in determining the basic physiology of the heart lesion. The most important feature in the interpretation of any heart lesion is the radiographic appearance of the pulmonary vascularity, which gives orientation of the pathophysiologic or hemodynamic aspect. The pulmonary vascularity is the Key to successfully arriving at the correct category of lesions. In order to properly interpret chest film of patients with heart disease, the physician must develop an approach. The diagnostic approach that we propose is based primarily upon the pattern of vascularity. Following the study of pulmonary vessels we analyse the cardiac structures¹.

Among all forms of heart disease, changes that occur in the pulmonary vasculature are reflected in the plain film as one of the four basic patterns: normal pulmonary vascularity, decreased pulmonary vascularity, increased pulmonary vascularity and uneven pulmonary vascularity¹.

PATTERNS OF PULMONARY VASCULARITY

Normal pulmonary vascularity — The normal pulmonary vascularity can be observed in shunt lesions in which the shunt is inferior to 40%, right obstructive lesions, mitral regurgitation and the so called left ventricle (LV) stress lesions. The diseases that stress the L.V. can be divided in 4 categories: 1 — pressure overloading, in which there is obstruction of the flow leaving the L.V., e. g. aortic valve stenosis, coarctation; 2 — volume overload, in which an excess amount of blood returns to the L.V., e. g. aortic valve regurgitation; 3 — disorders of contraction and/or relaxation of the L.V., e. g. miocardiopathy, L.V. aneurysm; 4 — alteration of miocardium vascularization, e.g. coronary disease.

In all these situations the pulmonary vascularity is normal while the corresponding ventricle maintains its compensatory state and therefore remains normal in size¹.

Decreased pulmonary vascularity — Decreased pulmonary vascularity or oligoemia indicates that there is severa obstruction of the flow of blood to the lungs from whichever ventricle the pulmonary artery arises an association with a ventricular septal defect (VSD). Oligoemia is always associated with cyanosis³.

Pulmonary valve stenosis per se does not cause decreased pulmonary flow, because the right ventricle (RV) is able to raise its systolic pressure so as to maintain normal cardiac output by increasing the intraventricular pressure⁴. However if there is an associated VSD, as occurs in Fallot's tetralogy the RV systolic pressure is limited to the systemic pressure and there is right-to-left shunt and therefore oligoemia. The most common causes of oligoemia and normal heart size are

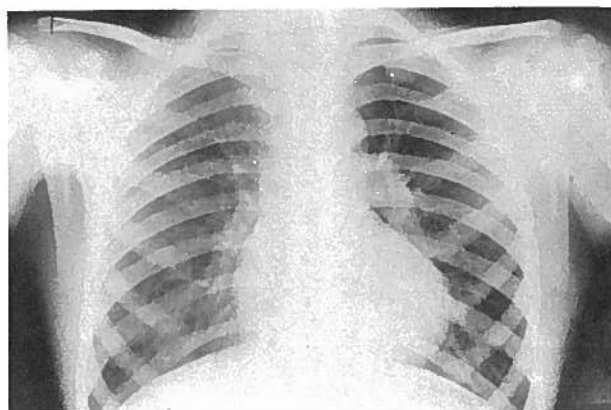


Fig. 1 — Decreased pulmonary vascularity, englargement of left pulmonary artery; heart size normal Fallot's tetralogy.

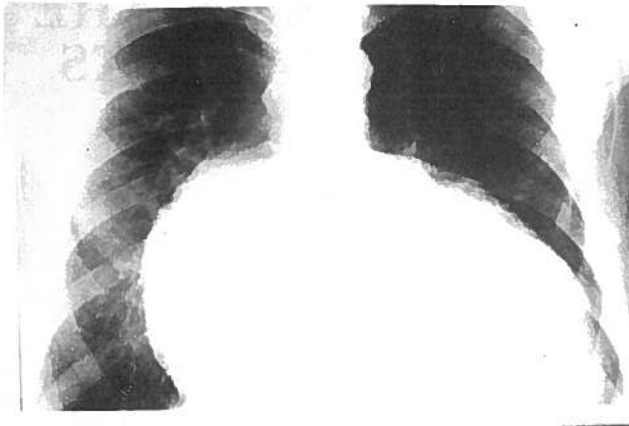


Fig. 2—Oligemia, heart size increased; congenital tricuspid valve stenosis.

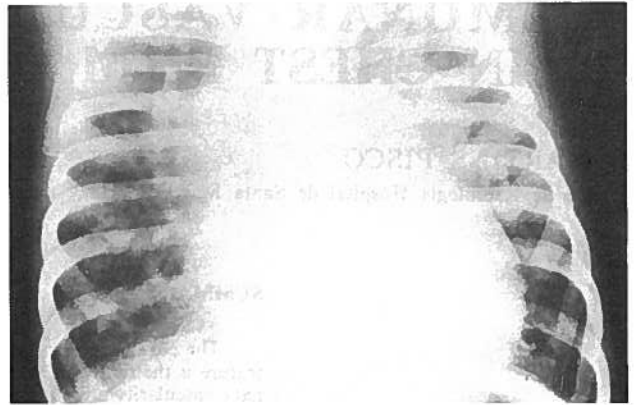


Fig. 4—Plethora, snow-man configuration of heart shadow; total anomalous pulmonary venous drainage.

Fallot's tetralogy and its variants (Fig. 1). Oligemia and cardiomegaly is usually due to Ebstein disease⁵. Another cause of oligemia and cardiomegaly is congenital tricuspid valve stenosis (Fig. 2).

Increased pulmonary vascularity — There are three different patterns of increased pulmonary vascularity: uniform or plethora in which proximal and distal vessels are dilated in all zones; vessels dilated only in upper lung fields (cefalization, redistribution or upper blood diversion); only the proximal vessels are dilated, the distal vessels are decreased in size and number (centralization)².

a) Plethora means uniform prominence of central and intrapulmonary vessels primarily due to increased flow, and indicates the presence of a shunt. In plethora there is an enlargement of the right lower lobe artery of over 16 mm in adult males and 15 mm in adult females⁴.

Plethora may or may not be associated with cyanosis. Plethora not associated with cyanosis is due to left-to-right, show in the following lesions: arterial septal defect, ventricular septal defect, patent ductus arteriosus (Fig. 3), atrio-ventricular canal, left ventricular-right-atrial defect, aorto-pulmonary septal defect⁴.

There is cyanosis only in the presence of veno-arterial mixing with bidirectional shunting. The bidirectional shunt lesions are the following: complete transposition, total anomalous pulmonary venous drainage (Fig. 4), truncus arteriosus, single atrium, single ventricle, double outflow right ventricle⁴.

b) Dilatation of upper lung vessels, redistribution or upper blood diversion occurs when there is pulmonary venous hypertension (PVH). The causes of PVH are: mechanical obstructive disease processes at or proximal to the mitral valve, primary mitral incompetence and left heart failure (Fig. 5).

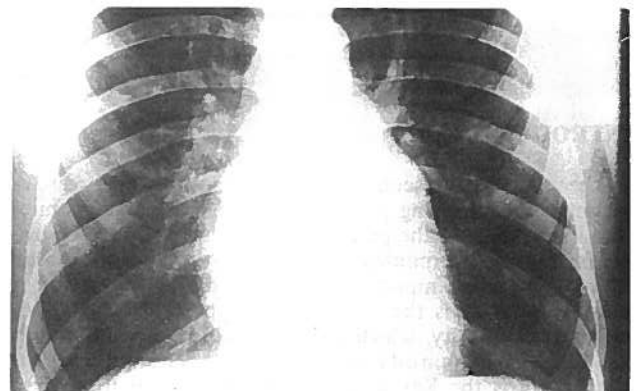


Fig. 5—Upper blood vessel dilatation, left appendage enlargement; mitral stenosis.

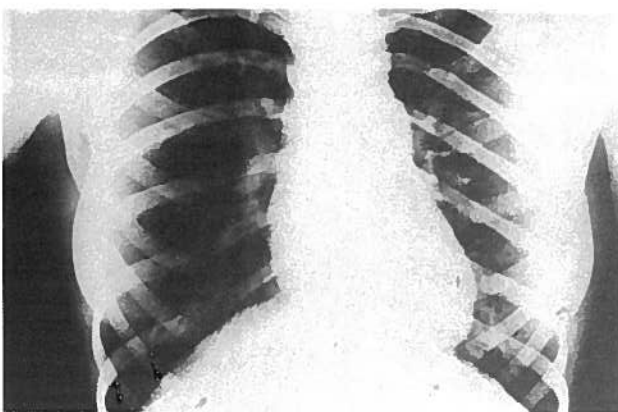


Fig. 3—Plethora, convexity between the aortic arch and the elongated pulmonary trunk; patent ductus arteriosus.

In these situations there is an increase in resistance to flow beyond the pulmonary capillaries, pressure increases in the pulmonary veins and thus post-capillary or pulmonary venous hypertension occurs and at that time the pulmonary capillary venous pressure measures 15 mm Hg or more. As this pressure increases the following radiological signs are shown: upper zone vessel dilatation, interstitial edema, pleural effusion and alveolar edema (fig. 6). It is possible to broadly relate these changes to the height of the pulmonary venous pressures⁶.

When the capillary pressure exceeds the normal plasma osmotic pressure of 25 mm Hg, fluid escapes into the interstitial tissues of the lung. The signs of interstitial edema are septal lines, perivascular and peribronchial edema, hilar edema, subpleural edema and generalized loss of translucency. The earliest sign of interstitial edema is enlargement of the hila, the outer margin of which is poorly defined and hazy. Another finding of interstitial edema is peribronchial cuffing due to edema forming around the bronchus and producing a thickening of the wall⁷.

The fluid that has entered the interlobular septa is expressed radiologically as thin, dense, straight horizontal lines bet-

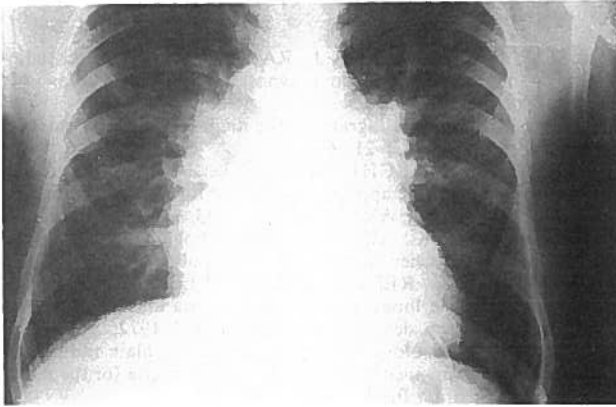


Fig. 6—Upper blood vessel dilatation, hila prominent and poorly defined, interstitial pulmonary edema, Kerley B lines in right base; mitral stenosis.

ter seen in costo-phrenic angles and they are called Kerley B lines. The straight lines in upper fields running towards the hilum, are called Kerley A-lines, they are also due to fluid in the interlobular septa and are usually seen in acute interstitial edema. Generalized decreased pulmonary lucency, decreasing of lung compliance with higher diaphragm domes are other signs of interstitial edema⁸.

Subpleural edema due to fluid between the lung and the visceral pleura may mimic thickened interlobular fissures. Small pleural effusion seen in costo-phrenic angles or in fissures may be the only sign of interstitial edema, with higher pulmonary venous pressure larger effusions can occur more commonly on the right side and can become loculated⁸.

When the pulmonary venous pressure is above 30 mm Hg, fluid is no longer kept in the interstitial tissues and escapes into the alveoli and results in alveolar edema.

Pulmonary haemosiderosis and pulmonary ossific nodules are associated with chronic pulmonary venous hypertension not with the height of that pressure⁹.

c — Central dilatation or Centralization — The increase in size of the pulmonary artery and its branches and of the lobar arteries associated with narrowing of distal pulmonary arteries mean arterial hypertension (PAH) (Fig. 7). In this situation the pulmonary artery pressure exceeds 30 mm Hg¹⁰.

The higher the pulmonary artery pressure the more the dilatation of the central vessels the peripheral constriction and the more central the transition zone. In such a situation the pulmonary vessels have the so called *pruned-tree appearance*.

As the pulmonary arterial pressure increases there is constriction of the muscular arteries that develop medial hypertrophy thickening of the intima and at the same time there is dilatation of the elastic arteries. On the plain chest film the hila become more prominent, due to dilatation of the pulmonary trunk and lobar arteries (elastic arteries) poorly defined, and there is narrowing of the distal segmental arteries (muscular arteries). The small peripheral vessels in the distal and middle third of the lung appear reduced in size and number and consequently there is decreased vascularity in the periphery. Calcification in the pulmonary trunk and lobar branches may be present in longstanding PAH and when the pulmonary arterial pressure is equal or greater than the systemic arterial pressure (Fig. 8)^{4,5}.

The main causes of PAH are: pulmonary venous hypertension, central shunts, embolism (thrombus, tumor, parasite), arteritis (polyarteritis, lupus), hypoxia (high altitude, respiratory infection in children), respiratory disease (cor pulmonale), primary pulmonary hypertension⁴.

Sustained pulmonary venous hypertension may cause obstructive changes in the small pulmonary arteries leading to

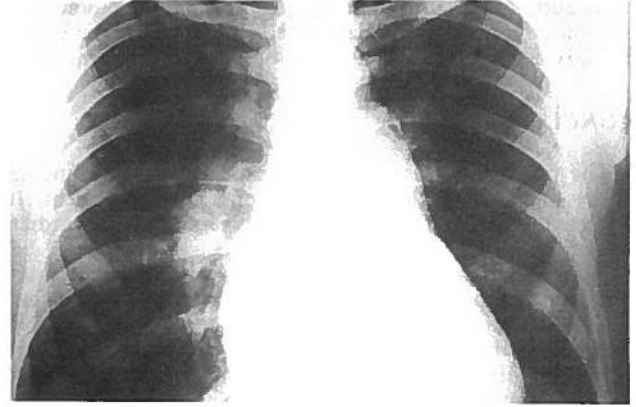

Fig. 7—Enlargement of the pulmonary trunk, with a small calcification and of the right descending pulmonary artery, with narrowing of the peripheral vessels; essential arterial pulmonary hypertension.

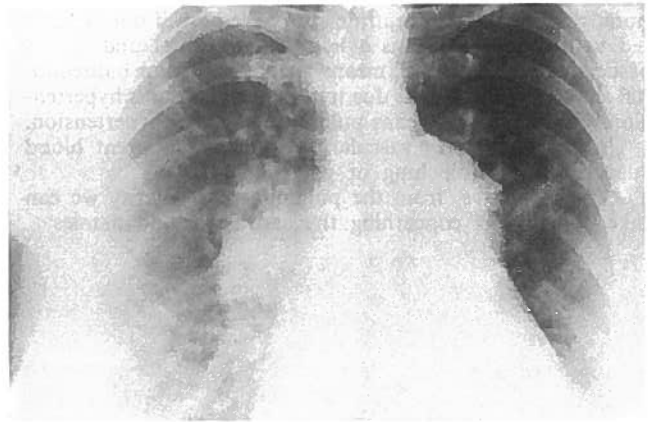


Fig. 8—Enlargement of the main pulmonary artery and of the right descending pulmonary artery associated with peripheral vessel constriction; atrial septum defect type "secundum" with pulmonary arterial hypertension.

an increase in pulmonary vascular resistance^{4,5}.

In left-to-right shunt, when the vascular resistance is very high the shunt is small or reversed and the radiological picture is that of pulmonary arterial hypertension.

Uneven pulmonary vascularity. Uneven pulmonary vascularity means the presence of vessels of a different size in a lung or a part of a lung. They are either too small or too large. It may be unilateral or patchy.

a) — Unilateral difference in vessel pattern — In this situation the vessels in one lung are smaller or larger than in the other lung. The lung with small vessels is hypertranslucent or reduced in volume with mediastinal displacement, elevated diaphragm and narrow intercostal spacing. The cardiovascular causes are the following: congenital absence of one pulmonary artery, congenital pulmonary valvular stenosis, systemic-pulmonary shunt operation (e.g. Blalock shunt), extrinsic pressure (aneurysm, tumor, aberrant left pulmonary artery), massive embolism, hemitruncus arteriosus^{4,5}.

b) — Uneven vascularity of a patchy nature — There is an increase in local irregular perfusion of one lung, either by the pulmonary arteries or by a systemic arterial supply from tho-

racic aorta or this branches. The main causes are: pulmonary atresia, peripheral pulmonary arterial stenosis, multiple pulmonary arteriovenous fistula, multiple pulmonary emboli^{4,5}.

CONCLUSION

The pulmonary vascularity is the most important finding to be observed in the plain chest of a cardiac patient. It reflects the pathophysiology and hemodynamics of the cardiac anomaly.

Normal pulmonary vascularity means that the cardiac output, and the pulmonary venous and arterial pressures are normal. In valvular stenosis the pulmonary vascularity is normal, unless the proximal ventricle is in failure. In this situation the left lesions are shown as pulmonary venous hypertension and the right ones as oligoemia.

Decreased pulmonary vascularity means that there is an obstruction in the right ventricle outflow associated with right-to-left shunt. In such condition the right ventricle cannot increase the intraventricular pressure above the left ventricle pressure due to intraventricular septal defect, and there is oligoemia.

Increased pulmonary vascularity can be uniform or plethora, cephalization and centralization. Plethora if not associated with cyanosis, means a left to right shunt and if it is associated with cyanosis, means a right to left or bidirectional shunt. Cephalization is due to pulmonary venous hypertension. Centralization means pulmonary arterial hypertension.

Uneven pulmonary vascularity is due to different blood supply for a whole lung or part of it.

As show above, from the pulmonary vascularity we can take conclusions concerning the cardiac hemodynamics.

BIBLIOGRAPHY

1. PISCO J.M., SALDANHA J., RAPOSO J.S.: Valor da radiografia simples do tórax no diagnóstico das cardiopatias. *Act Méd Port* 1984; 5: 179.
2. CHEN J.T.: Plain radiograph in the diagnosis of cardiovascular disease. *RCNA* 1983; 21: 609.
3. ELLIOTT L.P.; SCHIABLER G.L.: A roentgenologic-electrocardiographic approach to cyanotic forms of heart disease. *Pediatr Clin North Am* 1971; 108: 1133.
4. JEFFERSON B.K.: The plain chest radiograph in congenital heart disease. Review article. *Br J Radiol* 1970; 43: 753.
5. JEFFERSON K., REES S., SOMERVILLE J.: Systemic arterial supply to the lungs in pulmonary atresia and its relation to pulmonary artery development. *Br Heart J* 1972; 34: 418.
6. MILNE E.: Physiological interpretation of the plain radiograph in mitral stenosis, including a review of the criteria for the radiographic estimation. *Br J Radiol* 1963; 36: 902.
7. MILNE E.N.C.: Correlation of physiologic findings with chest roentgenology. *Radiol Clin North Am* 1973; 11: 17.
8. SIMON G.: The value of radiology in critical mitral stenosis. *Clin Radiol* 1972; 23: 145.
9. PISCO J.M.: The plain chest film findings in pulmonary venous and arterial hypertension — In: ME Silvestre, F Abecassis, JA Veiga Pires (Eds.). *Excerpta Médica, Radiology* 1987; 25-27.
10. PISCO J.M., CORREIA M.G.: Sequential approach to heart disease by plain chest film — In: ME Silvestre, F Abecassis, JA Veiga Pires (Eds.). *Excerpta Médica, Radiology* 1987; 29-31.

Pedido de Separatas:
 João M. Pisco
 Serviço de Radiologia
 Hospital de Santa Marta
 Rua de Santa Maria
 1100 LISBOA