

# HERPES ZOSTER AND CONTRALATERAL HEMIPLEGIA IN AN AFRICAN PATIENT INFECTED WITH HIV-1

ANTÓNIO VAZ CARNEIRO, JOSÉ FERRO, CRISTINA FIGUEIREDO, LAURA COSTA, JORGE CAMPOS, EVARISTO FERREIRA E FERNANDO DE PÁDUA

Serviços de Medicina IV, Neurologia e Radiologia. Hospital Universitário de Santa Maria. Lisboa.

## SUMMARY

One of the neurologic complications of human immunodeficiency virus infection are cerebrovascular accidents. In HIV infected patients, ischemic strokes have been reported secondary to nonbacterial thrombotic endocarditis and cerebral arteritis. We describe an unusual cause of stroke in HIV-1 infection: Herpes Zoster ophthalmicus with contralateral hemiplegia.

## RESUMO

Herpes Zoster e hemiplegia controlateral num doente infectado pelo HIV-1

Entre as complicações neurológicas descritas na infeção pelo Vírus da Imunodeficiência Humana destacam-se os acidentes vasculares cerebrais. Nos doentes com esta infeção, os acidentes vasculares cerebrais isquémicos são normalmente secundários a endocardites trombóticas não bacterianas ou a arterites dos vasos cerebrais. Apresenta-se um caso raro de acidente vascular cerebral em doente infectado pelo HIV-1: Herpes Zoster oftálmico com hemiplegia controlateral.

## INTRODUCTION

The usual neurologic manifestations of AIDS include viral and non-viral infections with a variety of agents, central nervous system (CNS) neoplasms and cerebrovascular accidents<sup>1</sup>. In this report we describe an unusual neurological complication in a patient infected with HIV-1: Herpes Zoster ophthalmicus with contralateral hemiplegia.

## CASE REPORT

A 32 year old black woman was admitted to our hospital with a nine month history of left Herpes Zoster ophthalmicus, and a five month history of sudden contralateral hemiplegia. She was born in Angola, but had lived most of her life in Zaire. Past medical history included malaria. There was no history of intravenous drug abuse, transfusion of blood products, the practice of traditional scarification or contact with multiple sexual partners.

On admission to our Hospital, her physical exam disclosed a normal blood pressure and heart sounds, hepatomegaly, splenomegaly and generalized lymphadenopathy. She exhibited sequelae of left Herpes Zoster ophthalmicus, with ptosis bulbi and mottled discoloration of the skin on the distribution of the first division of the left trigeminal nerve. Neurologic exam disclosed spastic right hemiparesis.

She had a hypochromic, microcytic anemia with a hemoglobin value of 8.7 g/dl, a total white blood cell count of 5400/mm<sup>3</sup> with a differential of 45 percent neutrophils, 48 percent lymphocytes and 4 percent monocytes, a platelet count of 250,000/mm<sup>3</sup> and an erythrocyte sedimentation rate (Westergren) of 90 mm/hr. Serum iron was 48 mg/dl and total serum iron-binding capacity was 350 mcg/dl. Hemoglobin electrophoresis revealed no diminished or abnormal hemoglobin patterns. Serum glucose was 96 mg/dl. Serum alanine aminotransferase (SGPT) was 17 IU/L, serum aspartate aminotransferase (SGOT) was 12 IU/L, gamma glutamyl transpeptidase was 12 IU/L, alkaline phosphatase was 57 IU/L, total bilirubin was 1,1 mg/dl and direct bilirubin was 0,4 mg/dl, and lactic dehydrogenase

was 389 IU/L. Serum sodium was 139 mEq/L, serum potassium was 4,4 mEq/L, serum chloride was 105 mEq/L and serum bicarbonate was 22 mEq/L. Total cholesterol and triglycerides levels were 196 mg/dl and 95 mg/dl, respectively. Results of VDRL, antinuclear antibody, and RA tests were negative. Examination of the peripheral blood smear for malarial parasites was also negative, and fecal occult blood tests done at three different occasions were all negative.

The serum protein electrophoresis showed hypoalbuminemia (2,8 mg/dl) and a polyclonal hypergammaglobulinemia (3,5 gr/dl). IgG and IgM levels were 3770 mg/dl and 723 mg/dl, respectively. Cytomegalovirus titer was 1:10, herpes simplex viral titer was 1:10, Epstein Barr virus-viral capsid antibody titers were IgG > 16 and an IgM > 8, hepatitis B surface antigen and antibody were negative, but antibodies to hepatitis B core antigen and e antigen were positive. Herpes Zoster virus and toxoplasmosis serologic studies were negative. Results of repeated cultures of blood, urine, and sputum for bacteria were negative. Examination of stool for ova and parasites identified trichuris trichiura eggs and giardia lamblia cysts.

The enzyme-linked immunosorbent assay for antibodies to HIV-1 were strongly positive on two occasions, confirmed with the Western blot analysis (assays for antibodies to HIV-2 were unavailable at the time). Phenotypic analysis of T lymphocyte subsets showed an absolute helper T cell of 952/mm<sup>3</sup>, suppressor T cell number of 1056/mm<sup>3</sup>, and a helper/suppressor T cell ratio of 0.9. The blastogenic response of the patient's mononuclear leukocytes to pokeweed mitogen and tetanus toxoid were markedly diminished. Recall antigen skin tests showed that she was anergic.

The bone marrow biopsy specimen was moderately hypercellular with an myeloid/erythroid ratio of 2:1, and was without plasmodium or leishmania; cultures for tuberculous bacilli were negative. Cervical lymph node biopsy disclosed an effaced architecture, with poorly defined germinal centres and marked vascular proliferation. She had a normal chest X-ray and electrocardiogram, and an echocardiogram disclosed no morphologic abnormalities or intra-cavitary thrombus.

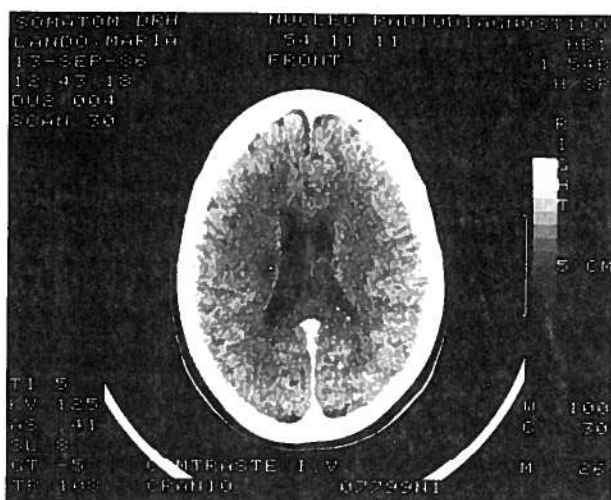


Fig. 1—Enhanced CT left hemispheric capsular infarct.

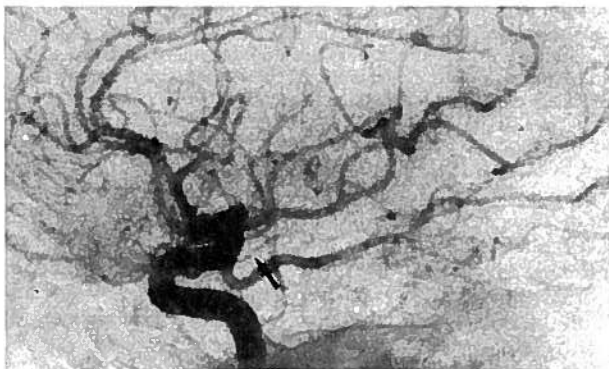

Fig. 2—Left carotid angiogram: segmental stenosis of the anterior choroidal artery.

Cerebrospinal fluid analysis showed a clear sample with a low glucose concentration, and a cell count of 16 mononuclear cells/mm<sup>3</sup>; bacterial, viral and fungal cultures were all negative. Slow anterior temporo-parietal teta activity was seen on electroencephalogram. Computed tomography of the head disclosed an old left capsular infarct (Figure 1). Cerebral angiography showed arteritis of the anterior left choroidal artery with occlusion (Figure 2). Metronidazole and mebendazole were administered. Patient underwent surgery for removal of the left eye followed by a prosthetic replacement, and was discharged in stable condition.

## DISCUSSION

This patient presented with a rare neurologic complication of the human immunodeficiency virus infection: Herpes Zoster ophthalmicus and contralateral hemiplegia due to ischemic stroke. Cerebrovascular accidents are one of the neurological complications that can occur in HIV infected subjects<sup>1</sup>. Strokes are often hemorrhagic and fatal and can be secondary to clotting disorders, and to invasion of cortical veins or dural sinus by fungal infections. Multiple cerebral emboli due to infectious and thrombotic non-infectious endocarditis can also occur<sup>1</sup>. An homosexual man developed a progressive, multifocal, cerebral granulomatous angiitis associated with HIV central nervous system infection, without evidence

of immunodeficiency<sup>2</sup>. In our patient infected with HIV-1, a subcortical infarct occurred four months after the onset of HZ infection, the typical features of arteritis were documented by cerebral arteriogram, and other causes of stroke were excluded by appropriate laboratorial and imaging investigations.

The acute onset of hemiplegia contralateral to Herpes Zoster ophthalmicus is a rare complication of HZ infection<sup>3</sup>. Affected patients usually have some systemic malignancies or are immunocompromised. The virus is thought to spread to the branches of the internal carotid artery via nerve fibers of the first division of the trigeminal nerve, producing a granulomatous arteritis. In a few AIDS patients ischemic stroke has been related to arteritis. Snider et Al. reported a patient who had bilateral basal ganglia infarcts temporally related to the development of Ramsay-Hunt syndrome<sup>4</sup>. In a preliminary report, Zaraspee-Yoo et Al. described a patient with AIDS and left HZ ophthalmicus who suddenly experienced aphasia and right hemiplegia. One year after the onset of HZ infection, preceded by transient aphasia and right facial weakness 10 months before<sup>5</sup>. Recently, Petito et Al. reported one patient whose postmortem study showed an endarteritis of the leptomeningeal arteries, with immunohistochemical staining for HZ in intimal cells<sup>6</sup>. It is possible that HZ angiitis underlies most cases of ischemic stroke in HIV-1 infected patients. This complication has not been previously reported in African or European cases<sup>7-9</sup>.

## BIBLIOGRAFIA

1. LEVY R.M., BREDESEN D.A., ROSENBLUM M.L.: Neurological manifestations of the acquired immunodeficiency syndrome (AIDS): Experience at UCSF and review of the literature. *J Neurosurg* 1985; 62: 475-495.
2. YANKNER B.A., SKOLNIK P.R., SHOUKIMAS G.M., GABUZDA D.H., SOBEL R.A., HO D.D.: Cerebral granulomatous angiitis associated with isolation of human T-lymphotropic virus type III from the central nervous system. *Ann Neurol* 1986; 20: 362-364.
3. HILT D.C., BUCHOLTZ D., KRUMHOLTZ A., WEISS H., WOLINSKI J.S.: Herpes Zoster ophthalmicus and delayed contralateral hemiparesis caused by cerebral angiitis: Diagnosis and management approaches. *Ann Neurol* 1983; 14: 543-553.
4. SNIDER W.D., SIMPSON D.M., NIELSEN S., GOLD J.W.M., METROKA C.E., POSNER J.B.: Neurological complications of acquired immunodeficiency syndrome: Analysis of 50 patients. *Ann Neurol* 1983; 14: 403-418.
5. ZARASPE-YOO E., MILETICH R., TOURTELLOTTE W.W.: Herpes Zoster Ophthalmicus with contralateral hemiplegia in a patient with autoimmune deficiency syndrome (AIDS). *Neurology* 1984; 34 (suppl): 229.
6. PETITO C.K., CHO E.S., LEMANN W., NAVIA B.A., PRICE R.W.: Neuropathology of acquired immunodeficiency syndrome (AIDS): an autopsy review. *J Neurol Exp Neuropath* 1986; 45: 635-646.
7. FENELON G., BOLGERT F., DEHEN H.: Les manifestations neurologiques du syndrome d'immuno-depression acquise. *Rev Neurol (PARIS)* 1986; 2: 97-106.
8. HO D.D., BREDESEN D.E., VINTERS H.V., DAAR E.S.: The acquired immunodeficiency syndrome (AIDS) dementia complex. *Ann Int Med* 1989; 111: 400-410.
9. HOLLAND G.N., KREIGER A.E.: Neuro-ophthalmology of the acquired immunodeficiency syndrome. In: *AIDS and the Nervous System*, edited by ROSENBLUM M.L., LEVY R.M., BREDESEN D.E. New York: Raven Press, 1988, p. 103-120.

Pedido de Separatas:  
António Vaz Carneiro  
Clínica Médica - Piso 2  
Hospital de Santa Maria  
Av. Prof. Egas Moniz  
1600 Lisboa