

SIDE-TO-SIDE CHOLEDOCHODUODENOSTOMY IN THE MANAGEMENT OF CHOLEDOCHOLITHIASIS AND/OR ASSOCIATED PATHOLOGY—FACTS AND FICTION

ANTÓNIO MENDES DE ALMEIDA, ANTÓNIO GINESTAL CRUZ,
FERNANDO JOSÉ ALDEIA

University Hospital of Santa Maria. University of Lisbon Medical School. Surgery I. Lisbon. Portugal

SUMMARY

Ascending cholangitis, the *sump* or *blind-sac* syndrome and alkaline reflux gastritis are drawbacks commonly ascribed to this surgical procedure. Most surgeons look down at this operation as a last resort measure to be utilized only on elderly patients and only on ducts wider than 15 mm. Trying to verify the pertinency of such, alleged, inconveniences and limitations a personal series is analysed, retrospectively until 1976 and prospectively from then on. A total of 61 of these operations were performed (1973-81), on 47 women and 14 men, 25% below 50 years of age, 33% over 70, 14 of them as Resurgery. Intravenous cholangiography was obtained, preoperatively, for evaluation of the duct width, which was less than 15 mm in 20 patients (32%). The follow-up period, surpassing 2 years in 26 (43%), includes clinical interviews and Liver biochemistries every 6 months and ERCP 12-18 months after surgery. One patient died during the immediate postoperative period and significant morbidity developed in 5 others (8.1%), the postoperative hospital stay averaging 7 days. The long term results on the survivors are classified as EXCELLENT in 48, GOOD in 8, FAIR in 3 and POOR in 1. It is concluded that this is a safe and very effective therapeutical measure, even when carried down on ducts less than 15 mm wide, provided a few technical requirements are respected. It does not carry the inconveniences usually ascribed to it. The excellent long term results of this series allow us to liberalize its utilization, even more so on young patients.

RESUMO

A Coledocoduodenostomia lado-a-lado no tratamento da litíase do colédoco e/ou patologia associada — Factos e Mítos

Colangite ascendente, o Síndrome *Sifão* e Gastrite por refluxo alcalino são alguns dos inconvenientes habitualmente atribuídos a esta atitude cirúrgica. A grande maioria de cirurgiões encaram esta operação com reservas, como devendo ser utilizada apenas em última instância, em doentes idosos e em colédocos extremamente dilatados, acima de 15 mm de diâmetro. Numa tentativa de verificar a pertinência ou menor validade de tais inconvenientes ou limitações, propusémo-nos analisar, retrospectivamente até 1976 e prospectivamente a partir dessa data, a nossa experiência pessoal. Um total de 61 destas operações foi efectuado (1973-81) em 47 mulheres e 14 homens, 25% dos quais com menos de 50 anos, 33% acima dos setenta, 14 em Recirurgia. Colangiografia intravenosa foi obtida, preoperatoriamente, para avaliação correcta do calibre ductal, o qual se verificou ser abaixo dos 15 mm em 20 doentes (32%). O período de *follow-up*, que ultrapassa os 2 anos em 26 doentes (43%) inclui entrevistas clínicas e estudo da bioquímica hepática 1 a 2 vezes por ano, e CPRE 12-18 meses após cirurgia. Um doente (74 anos de idade) morreu no período postoperatório imediato (1.7%) e significativa morbidade ocorreu em 5 outros (8.1%). A permanência hospitalar média, post cirurgia, foi de 7 dias. Os resultados a longo prazo são considerados EXCELENTE em 48, BOM em 8, ACEITÁVEL em 3 e MAU em 1. Conclui-se que esta operação é uma atitude terapêutica extremamente eficaz e segura, ainda que efectuada em colédocos de calibre inferior a 15 mm, sempre que alguns requisitos técnicos sejam rigorosamente observados. Não tem os inconvenientes que, habitual e erroneamente, lhe são atribuídos. Os excelentes resultados a longo prazo, na nossa série, permitem-nos liberalizar a sua utilização, por maioria de razão em doentes jovens.

INTRODUCTION

After its description by RIEDEL,¹ in 1888, this operation met a discrete wave of success in Continental Europe.^{2,3,4} Most Centers, though, hardly accepted this innovation. American and British surgeons, in particular, remained rather reluctant, SANDERS being the first one to, positively, report upon this procedure in 1946.⁵ Over the past 20 years, though, several papers erupted, in the anglo-saxonic literature, praising it and, clearly, demonstrating that the so-cal-

led *sump* syndrome and/or ascending cholangitis are, in all truth, pure fiction, provided a wide enough anastomosis is carried down on a wide enough duct.^{6,7,8,9,10,11}

Though an ever increasing number of surgeons are accepting it, as a safe tool in their armamentarium, they keep looking down to it as a second rate, last resort measure to be undertaken only on hugely dilated ducts, over 15 mm wide, on reoperations for recurrent stones or else on elderly, poor risk surgical cases, who would shortly outlive the operation, any how.

TABLE 1 Primary Surgery for Biliary Lithiasis and/or associated pathology (January 1973 — December 1981)

Operations	Nr.	Operat. Morbid	Operat. Mortal.	Mean postop. hospit. stay
Cholecystectomy, simple	177	4 (2.3 %)	1 (0.6 %)	7 days
Cholecystectomy, CBDE	68	6 (8.8 %)	1 (1.5 %)	11 days
Total	245	10 (4.1 %)	2 (0.8 %)	9 days

Among 68 CBDE's (27.7 % of 245 Cholecystectomies), stones were, actually, detected in 51 (75 %), for a total positivity rate of 20.8 %.

It was, recently, reported that 9, out of 15 choledochoduodenostomies evaluated via ERCP, displayed evidence of severe abnormal duodenogastric reflux with gastritis, the bilio-digestive anastomosis being blamed as the culprit.¹²

Encouraged by our early results, we set out to, retrospectively until 1976 and prospectively from then on, investigate the safety and long term outcome of this procedure. It is the purpose of this paper to report the answers we obtained to questions, such as: 1) Does our experience confirm that of previous authors in what concerns the so much talked about *sump* syndrome and/or cholangitis? 2) Is it safe to carry it down upon ducts less than 15 mm wide? 3) Does it lead, on the long run, to any significant impairment of the Liver function? 4) Should it be utilized, as a passive attitude, only on elderly patients, or else as a dynamic, active approach, the patient's age notwithstanding, aiming to maximize the benefits of primary surgery and, contrarily, minimize the need for further hospital admissions, due to residual or recurrent calculi? 5) Is it fair to think of it as a significant cause of duodenogastric reflux?

CLINICAL MATERIAL, METHODS

From January 1973 through December 1981, one of the authors (A.M.A.) performed 69 of these operations, 7 of which intended to bypass malignant obstructions of the terminal duct and 1 to drain a biliary tree communicating with an infected hydatid cyst cavity. Present discussion will relate, solely, to 61 pathological CBD's, consequent to lithogenic biliary diathesis and/or associated pathology. Both primary and second surgical cases are included. Our overall experience in the management of this disease entity is summarized on Tables 1, 2 and 3, while Table 4 displays the most significant data specifically related to the operation being discussed.

Preoperative work-up, as outlined before,¹³ includes IVC, unless contraindicated, for purposes of functional evaluation of the *Common Duct - Papilla* unit, and ERCP, as well, meant to rule out morphological changes of this unit and/or its contents. An increasing opacity of the common duct until 2 hours after the intravenous administration of the contrast material or its persistence beyond that time period and/or 10 minutes after sublingual administration of 0.6 mg of nitroglycerin serve as useful definition criteria of *Papillary Stenosis*. Radiocholangiomanometry, thought, at one time, to be of value in evaluating this controversial problem, has not proven to be so.^{14, 15} The CBD width is the single most crucial parameter to help us decide as to whether, or not, a permanent decompression of the biliary tree is in order.¹³ Therefore, its calibration, under physiological conditions of interplay between the secretory pressures of bile flow at the hepatocyte level, on one side, and the systolic and diastolic phases of the sphincter action, on the other side, is mandatory. The artificial intra-ductal pressures, as induced during manual injection of contrast material, both on ERCP and intraoperative cholangiogram, render the readings of the measured CBD diameter, so obtained, totally unreliable for that purpose. We, thereby, evaluate this parameter on the preoperative IVC and/or with a caliper or a ruler, within the operative field. A duct wider than 10 mm surely means emptying difficulties, the chances being that it will develop complications requiring further, aggressive, therapy and should, therefore, be permanently decompressed, whether stones are, actually, found within or not.¹³ Dilated (over 10 mm), poorly draining ducts where stones could not be found were classified, in this discussion, as *papillary stenosis* cases. SAHARIA's¹⁶ and MADDEN's⁹ criteria were used to distinguish among residual, retained or overlooked stones, usually considered as originating within the gallbladder and, posteriorly, migrat-

TABLE 2 Primary CBDE's for Biliary Lithiasis and/or associated pathology (January 1973 — December 1981)

Operations	Nr.	Operat. Morbid	Operat. Mortal.	Mean postop. hospit. stay
L-L Choledochoduodenostomy	47	4	1	8 days
Sphincteroplasty	6	1	0	13 days
Y-loop Hepaticojejunostomy	1	0	0	10 days
Choledocholithotomy, T-tube	14	0	0	13 days
Total	68	5 (7.3 %)	1 (1.5 %)	11 days

Choledochal stones 51; Papillary Stenosis 11; Pancreatitis Nodule 3; Cholangitis 3.

TABLE 3 Reoperations for Biliary Lithiasis and/or associated pathology (January 1973 — December 1981)

Operations	Nr.	Operat. Morbid	Operat. Mortal.	Mean postop. hospit. stay
<i>L-L Choledochoduodenostomy</i>	14	1	0	8 days
Sphincteroplasty	3	1	0	14 days
Y-loop Hepaticojejunostomy	4	2	1	14 days
Choledocholithotomy, T-tube	1	0	0	12 days
Total	22	4 (18.2 %)	1 (4.5 %)	12 days

Residual Stones 3; Recurrent Calculi 8; Papillary Stenosis 5; Pancreatitis Nodule 2; Iatrogenic Stenotic Lesions (elsewhere) 4.

ing down to the duct, on one side, and recurrent or primary ones, thought to form *de novo* within the CBD itself, on the other.

All patients are, thoroughly, followed-up, this surpassing 1 year in 43 (75 %) and 2 years in 26 (46 %). A clinical interview, prospectively oriented (Table 5), is carried out, by independent observers, every 6 months, and Liver biochemistries (Table 6) once a year or whenever deemed advisable. For correct evaluation of the anastomotic width and patency, the presence or absence of food *debris*, overlooked or reformed stones, duct mucosal inflammatory signs, as well as the possibility of abnormal duodenogastric reflux and gastroduodenal mucosal changes, an ERCP is obtained 12-18 months after surgery. This study was performed in 25 patients. UGI series are requested with the same aim, alternatively, if the patient refuses endoscopy.

Figure 1 depicts some of the technical guidelines utilized by us. A wide Kocher manoeuvre is indispensable. Dissection is carried down between the duodenal and duct walls as low as possible, until the retropancreatic arterial arcade, stemming off the gastroduodenal artery, is visualized and, carefully, avoiding it. This technical detail allows for the longitudinal choledochotomy (2.5 cm long) to be carried down retroduodenally on its lower third. By so doing the tension across the anastomosis is minimal, leading to a healthy, non fibrosed, non stenotic stoma. The longitudinal

choledochotomy carries another additional advantage, allowing the maintenance of an optimum blood supply to the duct wall.¹⁷ A single layer of interrupted stitches (000 or 0000) of Polyglycolic Acid, which is resorbed by hydrolysis and, consequently, with minimal or no inflammatory reaction,¹⁸ is carried down, both posterior and anteriorly.

IMMEDIATE RESULTS

There was one hospital death among 61 of these operations (1.6 %). This occurred on a 74 year old lady, after primary surgery, on the 7th postop day, as a consequence of massive UGI bleeding, the post-mortem exam. showing an intact stoma. Five patients (8.1 %) had their postoperative period marred by complications, 3 minor and 2 major. One patient developed superficial wound infection, one a minimal, self-containing, biliary drainage and another one an episode of CHF, responding quickly to digoxin and diuretics. Major morbidity aroused in 2 patients, one of them an anastomotic-cutaneous, high output (over 500 ml/24 hrs) fistula, closing spontaneously, after 3 weeks of TPN and another one a septic course, requiring intensive antibiotic therapy, with Liver biochemistries remaining within normal limits. These last 2 cases were the sole ones staying in the hospital over 10 days, after surgery. The average postoperative hospital stay was 7 days, ranging from 5-25.

TABLE 4 Summary of data relating to *L-L Choledochoduodenostomy* (Jan. 1973 — Dec. 1981), Primary and Secondary Surgery.

61	Nr. of patients	•	Duct width < 15 mm	20 (33.0 %)
14	Male	•	Operative Morbidity	5 (8.1 %)
47	Female	•	Operative Mortality	1 (1.6 %)
60	Mean age (yrs)	•	Mean postop. Hosp. stay	7 days
15 (25 %)	< 50 Yrs	•		
20 (33 %)	> 70 Yrs	•	<i>Pancreatitis Nodule</i>	5 (8.1 %)
14 (23 %)	Reoperations	•	<i>Papillary Stenosis</i>	9 (14.7 %)
47 (77 %)	Primary Surgery	•	<i>Choledochal Stones</i>	47 (77.0 %)

* Among 14 reoperated ducts, calculi were detected within 8 (57 %), classified as *Recurrent or Primary* (9,16) in 7 (87.5 %).

* Out of 47 ducts, primarily fenestrated, stones were found within 39 (83 %), in 5 of which the calculi, classified as *Primary* (9,16), could only be detected within the CBD.

TABLE 5 Questionnaire obtained, during personal clinical interviews, by independent observers, every 6-12 months

Syndrome	Signs and Symptoms
* Cholangitis, Hepatic Dysfunction	* Fatigability, Fatty food intolerance, Pruritus, Colicky pains with chills and fever, Urine and/or stool discoloration
** «Sump» or «Blind-Sac»	** <i>Dyspepsia, Diarrhoea, Steatorrhoea, Malnutrition</i>
*** Alkaline Reflux Gastritis, Esophagitis	*** Heartburn, Upper abdominal pain, Anorexia, UGI bleeding, Bile vomiting, Weight loss

TABLE 6 Biological, Radiographic and Endoscopic studies, to be carried out on all patients, as described on the text.

Hematocrit and Hemoglobin levels,
Serum Iron, TIBC, Transferrin,
Total Serum Proteins, Albumin and Globulins
SGOT and SGPT, Bilirubins, Alkaline Phosphatase, Gamma-glutamyltranspeptidase, Prothrombin Time, Serum Amylase, Urinary Bile Pigments
<i>Intravenous Cholangiography</i>
<i>Endoscopic Retrograde Cholangiopancreatography</i>

LONG TERM RESULTS

A widely patent, oval or round shaped, anastomosis was observed in all 25 patients undergoing postoperative ERCP study, without any ductal or duodenal mucosal changes being detected. No residual or reformed stones were seen, including 2 patients, knowingly left with irretrievable calculi, at the time of surgery. In 3 others food *debris* were, in fact, uncovered, lying on the terminal duct, though, easily floating, in and out, through the stoma. Macroscopic evidence, confirmed by histological examination, of gastritis with abnormal duodenogastric reflux was seen in 3 patients. Based on the data collected, as outlined, a classification of the long term results was elaborated (Table 7). EXCELLENT (grade I) was defined as freedom of any symptomatology, even remotely related to the biliary or UGI tracts, to the operation or a complication of the CBDE, GOOD (grade II) when occasional, minor, GI upsets, psychosomatic complaints or wound imperfections were present, with normal LFT's, FAIR (grade III) when significant complaints, such as those ascribable to the *sump* syndrome, abnormal LFT's or endoscopic evidence of pathological enterogastric reflux could be documented and POOR (grade IV) in patients with residual or recurrent stones, cholangitis, jaundice, severely disturbed LFT's, requiring reoperation.

DISCUSSION

All patients included in this series were evaluated and operated upon by one of the authors (A.M.A.) or under his direct guidance, lending a rather uniform set of criteria to

the decision-making process. Similarly, all endoscopic evaluations were carried out by the same author (A.G.C.). Clinical interviews and Liver biochemistries were interpreted by independent observers. Most patients (52 out of 60) were, in fact, prospectively followed up, searching specific answers to specific questions. These are features of this study allowing us to draw a few valid suggestions, despite the absence of a control series.

A foreseeable setback of this surgical procedure, as opposed to the more common and, apparently simpler, temporary T-tube decompression, after choledocholithotomy, would be its, allegedly, higher morbidity and mortality rates. However, the hospital death rates of this type of approach has been reported as ranging between 2.4-4.3%^{19, 20, 21} while it is no greater in published choledochoduodenostomy series, where both lithogenic diathesis and malignant obstruction cases are included^{6, 7, 8, 10} but significantly lower when only lithiasis cases are considered, as reported by LYGIDAKIS¹¹ and on our own, present, series (Tables 2, 3, 4). It seems quite reasonable to assume that it should not be, indeed, any higher. A common argument against this technical modality is that it would lead, on the long run, to hepatic dysfunction, as a consequence of repeated bouts of cholangitis and to a clinical picture of significant GI complaints, namely persistent episodes of diarrhoea, severe enough to cause nutritional impairment and commonly designated as the *sump* or *blind-sac* syndrome.

TABLE 7 Classification of Long Term results of 60 L-L Choledochoduodenostomies (Jan. 73 — Dec. 81)

Grade	Number
Excellent (Grade I)	48
Good (Grade II)	8
Fair (Grade III)	3 *
Poor (Grade IV)	1 **

* Three patients with endoscopic evidence of Alkaline Reflux Gastritis.

** Patient with Iatrogenic Stenosis of the Left Hepatic Duct, at the Hilum, submitted to an ill advised Choledochoduodenostomy, eventually corrected with a Y-loop Hepaticojejunostomy.

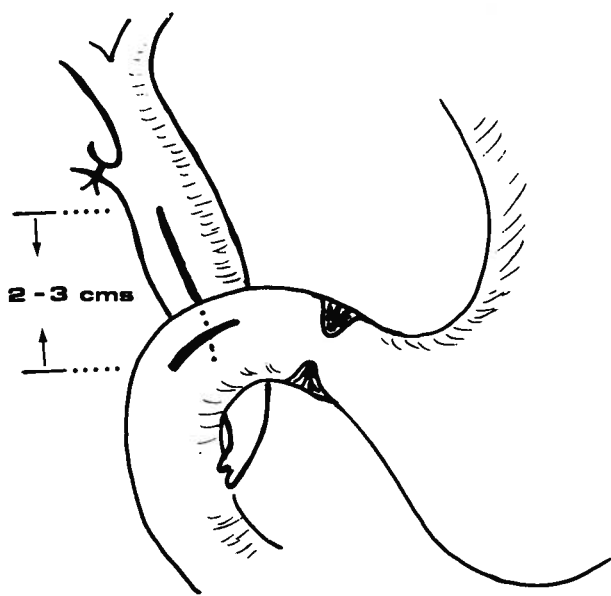


Figure 1: Schematic drawing of the technique utilized while performing a side-to-side choledochoduodenostomy.

Both these clinical entities are considered to be the result of stagnant bile and duodenal contents on the terminal segment of the common duct, between the newly formed stoma and an ill functioning papilla. The resulting bacterial proliferation could, easily, lead to cholangiolymphatic and/or cholangiovenous bacteria laden reflux, whenever the intrabiliary pressure would surpass the 20 and 25 cm of water barriers, respectively.²² This same proliferation, particularly of anaerobes, leading to an abnormal intestinal flora, much the same way as on the classical blind-loop syndrome, anywhere on the GI tract, enhancing bile salt deconjugation, would be at the origin of the so-called *sump* syndro-

me.^{23, 24, 25} In the present series only one patient went on to repeated bouts of cholangitis, eventually corrected by a Y-loop hepaticojejunostomy, our first operation having been an ill advised choledochoduodenostomy, since the source of this patient's troubles was an iatrogenic stenosis, inflicted elsewhere, of the left hepatic duct, at the hilum. Similarly, only one of our patients developed, two months post surgery, severe episodes of diarrhoea, eventually responding to oral administration of Metronidazol (see Table 7). It seems that the key point is the construction of a technically correct, wide enough (around 2.5 cm) anastomosis, allowing for free entrance and egress of bile and duodenal contents, avoiding any stasis or pressure build-up and stone retention, as well. The fact that a completely free CBD could be found, on ERCP, 1 year after surgery, on 2 patients of this series, known to have been left with retained stones, considered irretrievable at that time, supports our contention.

The necessity of a sizable anastomosis is the main reason why most surgeons believe that the duct should be, at least, 15-20 mm wide, so an adequate stoma would be technically feasible. We have been able, though, to, safely, perform a technically correct anastomosis in 20 patients (32%) whose duct width ranged between 10-15 mm, all of them classified as EXCELLENT long term results (Table 7). Endoscopic examination in 9 of these patients did show a widely patent and functional stoma. Figure 2 shows a cholangiographic sequence (pre, intra and 18 months postoperatively) of one of these patients. It is, indeed, quite feasible the construction of a 25 mm long stoma on a duct 12 mm wide, taking advantage of a longitudinal choledochotomy.

The hypothetical possibility that destroying, definitively, the sphincteric action might lead, on the long run, to hepatic dysfunction remains an unsettled question. To our knowledge no experimental evidence has ever been produced, in either sense. Published, clinical, series of choledochoduodenostomies^{6, 7, 8, 10, 11} fail to show any significant, long term, impairment of the Liver function. On our own series only 1 patient, for reasons other than the choledochoduodenostomy (Table 7) did show evidence of severely dis-

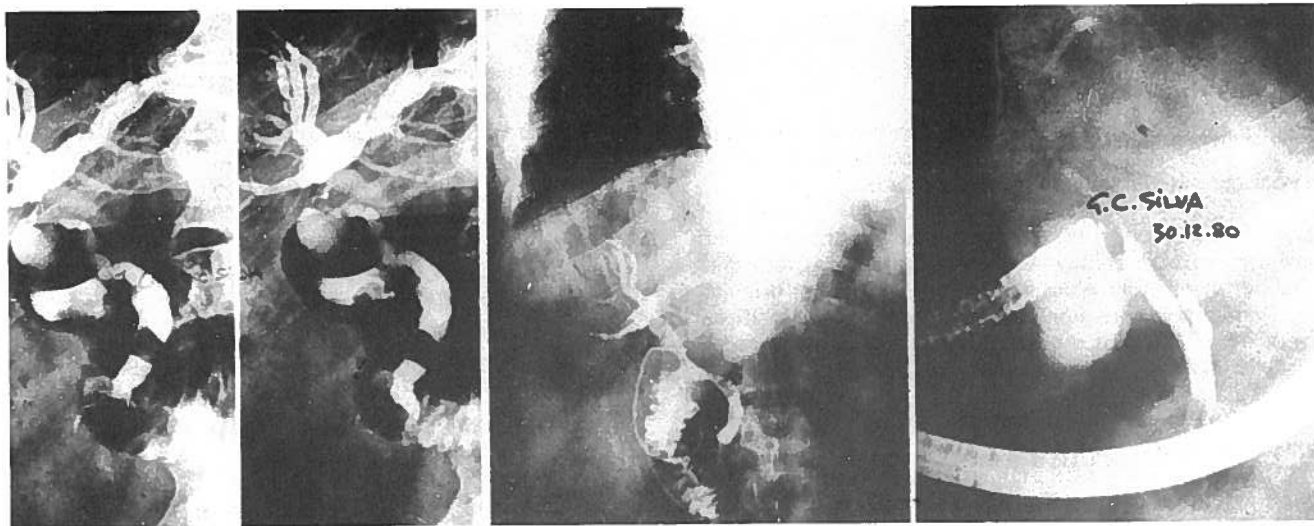


Figure 2: Cholangiographic sequence (Pre, Intra and 18 months Postoperative) of a patient whose CBD was 12 mm wide, as demonstrated during laparotomy.

turbed LFT's and 2 others slightly elevated alkaline phosphatase values, shortly after surgery, eventually returning down to normal.

There are, after all, no real valid reasons to look down at this procedure as a last resort, passive, measure. On the contrary, our experience allows us to look upon it as the best primary approach, to be actively utilized, in the management of choledocholithiasis and/or associated pathology,¹³ provided we are facing a dilated (over 10 mm), poorly draining duct, even when stones can not be found and in the absence of obvious contraindications, such as a thick walled, narrow lumen duct and/or duodenal ulcer disease might be considered. The younger a patient is found, harboring choledochal stones, the more aggressive the lithogenic diathesis is to be expected, justifying a similar aggressiveness in trying to control its consequences.

Over the past ten years much attention has been paid to the pathological significance of an ill defined, abnormal, enterogastric alkaline reflux, which has been described in several clinical situations.^{26, 27} The explanations for this occurrence go from, vaguely documented, disturbed motility patterns of the *Antro-Pyloro-Duodenal* unit to neurohormonal dysfunction or to purely mechanical reasons as it might be thought of on patients submitted to Bilroth I or II types of distal gastrectomy, where the most severe patterns have been described.^{28, 29} An unregulated bile flow into the duodenum, as it might be expected after any procedure abolishing the sphincteric action, could be a reasonable explanation for this abnormal reflux, which was found in 9, out of 15 choledochoduodenostomies, by AKIYAMA.¹² This same explanation could well justify the occurrence of this syndrome in cholecystectomized patients, even if the sphincter is not surgically destroyed.³⁰ However, in none of these two analysis is it stated whether this abnormal reflux was present, or not, before the operation, supposedly originating it, was performed. In our experience, 3 patients, out of 25 endoscopically examined, were found exhibiting this pathological entity, but the only one presenting significant clinical complaints, attributable to the duodenogastric reflux, had it present, already, when the preoperative ERCP was carried out.

Though it is conceivable that choledochoduodenostomy might cause or exacerbate an already present pathological reflux, no scientific evidence has been produced as to what might predispose to it: the removal of the gallbladder, the bilio-digestive or none of these, at all. The reported experience does not allow any conclusion, as well.

CONCLUDING REMARKS

Our experience with side-to-side choledochoduodenostomy in the management of choledocholithiasis and/or associated pathology allows us to conclude:

1) It is a safe and easy to do operation, carrying a very low operative morbidity and mortality rates. Confirming findings of other surgeons,^{6, 7, 8, 9, 10, 11} it does not originate ascending cholangitis nor can it be blamed as a significant cause of the so-called *sump* syndrome, provided a few technical requirements are respected, among which a correct, wide anastomosis is a major one.

2) There is no evidence, at all, that it might lead to a long term hepatic malfunction.

3) It is perfectly safe and technically feasible even on ducts less than 15 mm wide, but still dilated over 10 mm.

4) It can and should be envisaged as an active approach in dealing with choledocholithiasis cases, even more so in

young patients, where a more aggressive diathesis is prone to lead to enhanced further development of intra-ductal stones.

5) No answer could be found as to the relationship between the construction of this type of anastomosis and the causation of pathological duodenogastric reflux and corresponding clinical, alkaline reflux gastritis, syndrome.

Abbreviations

(by order of appearance on the Summary and Text):

ERCP - Endoscopic Retrograde Cholangio Pancreatography
 CBD - Common Bile Duct
 IVC - Intra Venous Cholangiography
 UGI - Upper Gastro Intestinal
 CHF - Congestive Heart Failure
 TPN - Total Parenteral Nutrition
 LFT - Liver Function Test

REFERENCES

1. RIEDEL, H.: Über den Zungenfoermigen fortstz des rechten Leberlappens und seine pathognostische bedeutung für die erkrankungen der Gallenblase nebst bemerkungen über Gallensteinoperationen. *Berl. Klin. Wschr.* 1888; 25: 577 and 602.
2. FLÖRCKEN, H.: Frei vereinigung Frakfurter Chirugen. 22. Sitzung vom 24 November 1927 in der Chir. Abt. des Diakonissen Hauses. *Zentralbl. Chir.* N.º 3, 1928.
3. SASSE F.: Über Choledochoduodenostomy. *Arch. Klin. Chir.* 1913; 100: 969.
4. MALLET-GUY, P.: Huit Choledochoduodenostomies d'indication relative (Lithiase Choledocienne, Angiocholite). *Lyon Chir.* 1939-40; 715: 723.
5. SANDERS, R. L.: Indications and value of Choledochoduodenostomy. *Ann. Surg.* 1946; 123: 847-855.
6. CAPPER, W. M.: External Choledochoduodenostomy. An evaluation of 125 cases. *BR. J. Surg.* 1961; 49: 292-300.
7. DEGENSHEIN, G. A.: Choledochoduodenostomy: An 18 years study of 175 consecutive cases. *Surgery.* 1974; 76: 319-324.
8. MADDEN, J. L.; CHUN, J. Y.; KANDALAF, S.; PAREK, H. M.: Choledochoduodenostomy: An unjustly «maligned» surgical procedure. *Am. J. Surg.* 1970; 119: 45-54.
9. MADDEN, J. L.: Common Duct Stones. Their origin and Surgical Management. *Surg. Cl. N. America.* 1973; 53: 1095-113.
10. SCHEIN, C. J.; SHAPIRO, N.; GLIEDMAN, M. L.: Choledochoduodenostomy as an adjunct to Choledocholithotomy. *Surg., Gyn., Obs.* 1978; 146: 25-32.
11. LYGIDAKIS, N. J.: Choledochoduodenostomy in Calculous Biliary Tract Disease. *Br. J. Surg.* 1981; 68: 762-765.
12. AKIYAMA, H.; IKEZAWA, H.; KAMEYA, S. and al.: Unexpected problems of External Choledochoduodenostomy. *Am. J. Surg.* 1980; 140: 660-665.
13. ALMEIDA, A. M.; GRACIAS, C. W.; SANTOS, N. M.; ALDEIA, F. J.: Choledocholithiasis — A Plea for Biliary Fenestration. *Acta Med. Portug.* 1981; 3: 113-124.
14. McCARTHY, J. D.: Radiomanometry during Biliary Operations. *Arch. Surg.* 1970; 100: 424-428.
15. SCHEIN, C. J. and BENEVENTANO, T. C.: Biliary Manometry: Its value in Clinical Surgery. *Surgery.* 1970; 67: 255-260.
16. SAHARIA, P. C.; ZUIDEMA, G. D. and CAMERON, J. L.: Primary Common Duct Stones. *Ann. Surg.* 1977; 185: 598-602.

17. NORTHOVER, J. M. A. and TERBLANCHE, J.: A new look at the arterial supply of the Bile Duct in man its surgical implications. *Br. J. Surg.* 1979; 66: 379-384.
18. HERRMAN, J. B.; KELLY, R. J. and HIGGINS, G. A.: Poliglycolic Acid Sutures. *Arch. Surg.* 1970; 100: 486-490.
19. JOHNSTON, E. V.; WAUGH, J. M. and GOOD, C. A.: Residual Stones in the Common duct: The question of operative cholangiogram. *Ann. Surg.* 1954; 139: 293-301.
20. GOLDSMITH, N. A. and RANSOM, H. K.: Choledochotomy, a Follow-up report. *Surgery.* 1958; 44: 868-876.
21. LARSON, R. E.; HODGSON, J. R. and PRIESTLEY, J. T.: The early and long term results of 500 consecutive explorations of the Common Duct. *Surg., Gyn., Obst.* 1966; 122: 744-750.
22. HUANG, T.; BASS, T. A. and WILLIAMS, R. D.: The significance of Biliary pressure in cholangitis. *Arch. Surg.* 1969; 98: 629-634.
23. GORBACH, S. L. and TABAQCHALLI, S.: Bacteria, Bile and the Small Bowel. *GUT.* 1969; 10: 963-972.
24. TABAQCHALLI, S.; HATZIOANNOU, J. and BOTH, C. C.: Bile salt deconjugation and Steatorrhoea in patients with the stagnant-loop syndrome. *Lancet.* 1968; 2: 12-16.
25. THOMAS, E.; KERRY GRANT, A.; HOLFORD, M. and al.: Bacterial Flora in the duodenum of patients after Biliary Fenestration. *Br. J. Surg.* 1973; 60: 107-111.
26. RHODES, J.; BARNARDO, D. E.; PHILLIPS, S. F. and al.: Increased reflux of Bile into the stomach in patients with Gastric Ulcer. *Gastroenterology.* 1969; 57: 241-244.
27. RITCHIE, Jr W. P.: Bile Acids, the «Barrier» and reflux-related Clinical disorders of the Gastric mucosa. *Surgery.* 1977; 82: 192-200.
28. DRAPANAS, T. and BETHEA, M.: Reflux Gastritis following Gastric surgery. *Ann. Surg.* 1974; 179: 618-626.
29. VAN HEERDEN, J. A.; PHILLIPS, S. F.; ADSON, M. A. and al.: Postoperative Reflux Gastritis. *Am. J. Surg.* 1975; 129: 82-88.
30. WARSHAW, A. L.: Bile Gastritis without prior gastric surgery: Contributing role of Cholecystectomy. *Am. J. Surg.* 1979; 137: 527-530.

Address for reprints: A. Mendes de Almeida
Rua das Praças, 43, 3.º-E.
1200 Lisboa - Portugal