

CARDIAC DIGITAL SUBTRACTION ANGIOGRAPHY

The modification of digital radiographic techniques has produced new means of cardiac examination. The digitized format of this method allows the simultaneous acquisition of anatomic images and functional data. The physiologic component of the study reflects a relative quantification of the direction, appearance, accumulation and clearance of intravenously injected contrast media in the cardiac chambers and great vessels. The clinical validity of the results from IV-D.S.A. on more than 100 patients with a wide array of cardiac disorders was challenged by comparison with the results obtained from conventional cardiac catheterization and nuclear medicine studies on the same patients as well as their clinical courses.

DISCUSSION

Less invasive examination techniques are available that have significantly added to the clinicians' ability to diagnose complicated cardiac disorders. Nuclear medicine, first pass and gated studies, and ultrasonic two-dimensional and M-mode techniques have had considerable impact on cardiac diagnosis. Each of these techniques have significant draw-backs despite their proven complementary value to the overall assessment of cardiac disease.

Ultrasonic examinations of the heart enjoy superb spatial resolution in rapid real-time acquisition at low cost and no known hazard. It has become the established optimal method for examination of the cardiac valves and gives an excellent assessment of anatomic relations of ventricular chambers and great vessels. Its disadvantages include highly skilled operator dependence and thin-slice images with limited segmental views resulting in poor global functional information.

Nuclear medicine techniques are also essentially without hazard. The injected isotope, although giving a minimal radiation dose, produces no hemodynamic changes. The signal intensity generated corresponds to the amount of isotope in the area of interest. The relative low photon output requires large area determinations to produce statistically valid data. The isotopic images have poor spatial resolution and are inadequate for anatomic detail. Despite these deficiencies, cardiac isotopic studies have become a standard for the retrieval of physiologic cardiac information. Shunt analysis, wall motion and ejection fraction determinations with isotopic studies have compared favorably with that obtained in cardiac angiography.

The pixel values from cardiac D.S.A. studies correspond to the intensity of radiation transmitted through a specific region. The pixel scale is determined so that the greater amount of contrast media in an area produces a higher value. The pixel scale number correlates with the amount of iodine within a region multiplied by the diameter of the chamber.

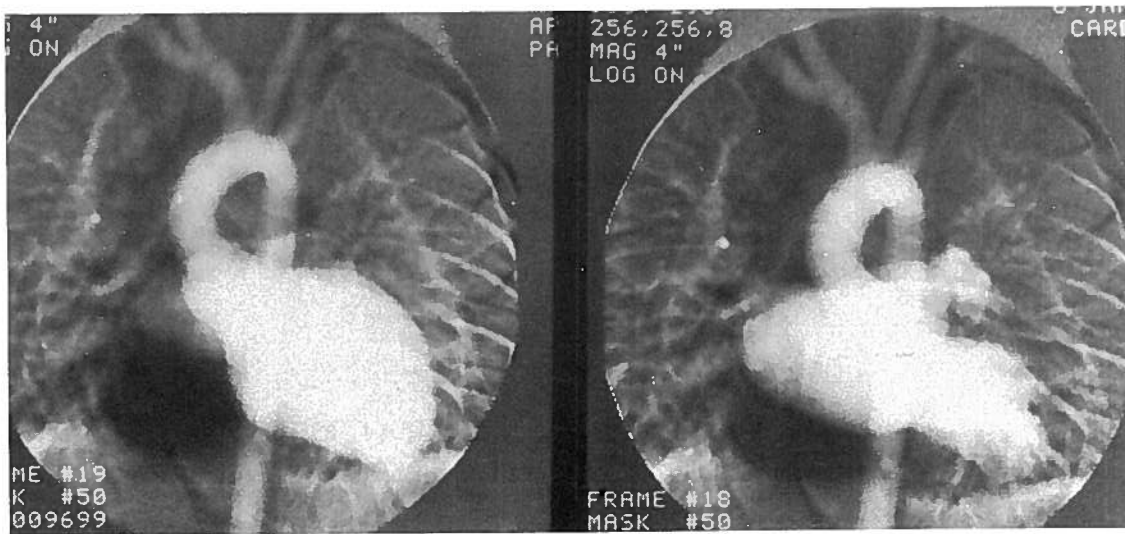


Fig. 1 Normal levophase of cardiac D.S.A. identifying diastole and systole of the left ventricle and atrium after intravenous injection of contrast media into the arm. (15 cc of 76% Renografin at 12 cc/sec.)

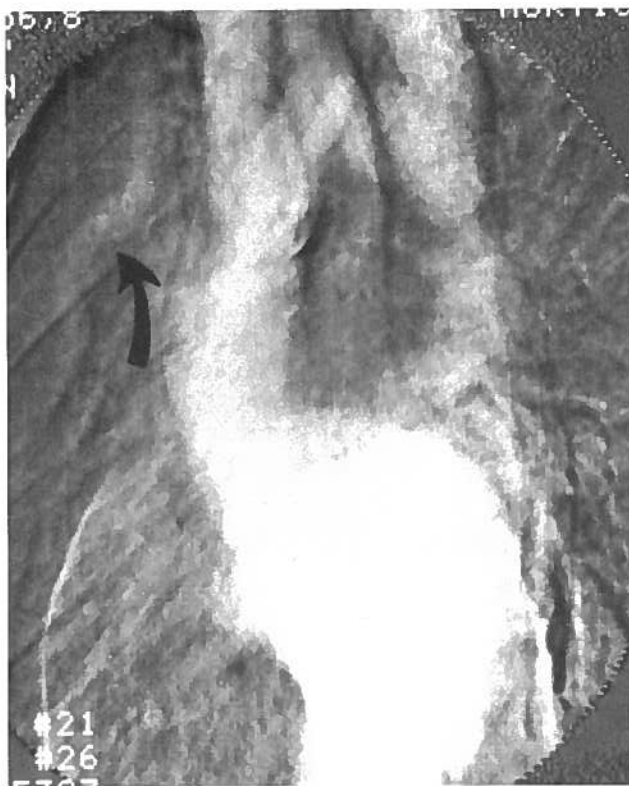


Fig. 2 Eighteen year old boy complaining of headaches. Hypertension in the upper extremities was identified. Intravenous cardiac digital subtraction angiogram in the left anterior oblique projection identifies coarctation of the proximal descending thoracic aorta. Note the enlarged right internal mammary artery (arrow).

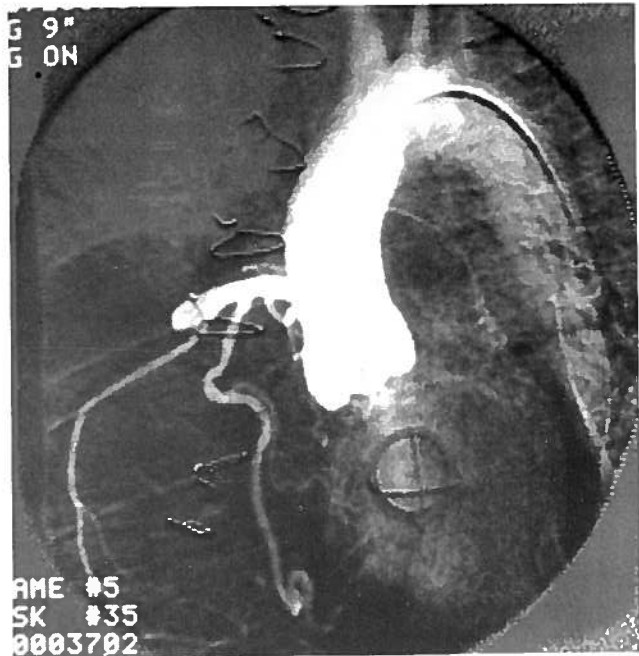


Fig. 3 Intra-aortic injection and cardiac digital subtraction angiogram for identification of the coronary arteries. 30 cc of contrast of 76% Renografin injected at 15 cc/sec. Subtraction technique with smaller volumes of contrast media is helpful for identifying finer arterial structures after intra-arterial injections. Left coronary artery in this patient originally arose from the left pulmonary artery and was ligated. Study was done for the evaluation of the right coronary artery. Note the small coronary artery branches over the posterior left ventricle.

The efficient utilization of the abundant x-ray photons generated in a digital subtraction angiography study eliminates the statistical problems of nuclear medicine. This allows smaller region of interest with smaller pixel sizes to be accurately determined with marked improvement in spatial resolution and image quality. Segmental functional information becomes available.

Although I.V.-D.S.A. is relatively safe and requires only peripheral intravenous injection, the use of contrast media produces certain disadvantages. The potential for idiosyncratic reactions, hemodynamic cardiovascular changes, renal toxicity and direct toxic effects on the peripheral vein are possible hazards. In addition, further disadvantages of I.V.-D.S.A. include the potential sources of diagnostic error. These include the relative high specific gravity of contrast media which may prevent optimal mixing in the right sided cardiac chambers and the relatively large bolus (in comparison to isotopic studies) that may produce artifactually induced elongated appearance and clearance time.

The potential sources of errors did not appear to significantly degrade the D.S.A. studies. This was evidenced by the satisfactory correlation with the results of isotopic and cardiac catheterization studies on the same patients. Region of interest plots were made over the superior vena cava to document the size of the injected bolus. Only studies with spike configurations of the plots over the superior vena cava were used.

Various methods for shunt analysis using I.V.-D.S.A. were compared to those from nuclear medicine. This included small regional plots over the right atrium, right ventricle, pulmonary artery and large areas over the entire lung. In each instance, similar data curves were retrieved which would indicate that incomplete mixing of contrast media was not a significant factor. The distal main left pulmonary artery was found to be the easiest area to flag and gave the most reproducible results since overlapping cardiac structures was less likely in this area.

The nonlinearity of pixel values relating to the amount of iodine in the area of interest has been addressed. The most pertinent reasons for nonlinearity include x-ray generator output inconstancy, veiling glare, x-ray scatter, limited dynamic range and log amplitude linearity. In this study, corrections were made only for the x-ray output inconstancy. There is no question that improved results would be obtained if scatter correction were utilized as described by Shaw and Mistretta. Experiments by Pavlicek have indicated that in regions with low pixel values (below 70), there is a satisfactory correlation between iodine content and pixel determinations. The curves generated without scatter correction were proven to be clinically valid and compared favorably to those obtained from nuclear medicine and cardiac catheterization on the same patients.

Evaluation of more than 100 patients with cardiac digital subtraction angiography, our index of confidence is high that the cardiac images are of adequate quality with good spatial resolution and sufficient anatomic detail. In 85 % of the examinations, the cardiac D.S.A. examination gave clinically useful diagnostic information when compared to cardiac catheterization. The complementary value of the quantitative assessment has had its greatest value in affording reproducible results and constancy between observers and in temporal comparisons after repeated studies. Segmental areas of the heart may be selectively analyzed for their contribution to overall function. In general, the digitized quantitative data has complemented the image analysis.

Cardiac catheterization with selective angiography remains the standard for examination with selective and high spatial resolution cardiac images. The results of this study indicate that cardiac I.V.-D.S.A. yields functional information similar to that of nuclear medicine but with superior image quality. The safety and ease of D.S.A. allows examination on out-patients, eliminates the need for basic functional studies and aids to tailor the approach and need for cardiac catheterization.

Edward Buonocore

Chairman of the Department of Hospital Radiology
The Cleveland Foundation.
9500 Euclid Avenue, Cleveland,
Ohio 44106
U.S.A.