

# MICROCIRCULATION AND HEMORHEOLOGY

P. S. RAMALHO

Department of Ophthalmology. Hospital Sta. Maria. Lisbon. Portugal.

Microcirculation and hemorheology may neither be considered apart nor be separated from the clinical setting in which they are embraced. Whenever blood-flow is compromised by a reduction of the caliber of the vessels, so hampering circulation and tissue nourishment, the best therapy will be decreasing blood viscosity and improving the quality of the blood flowing through these vessels.

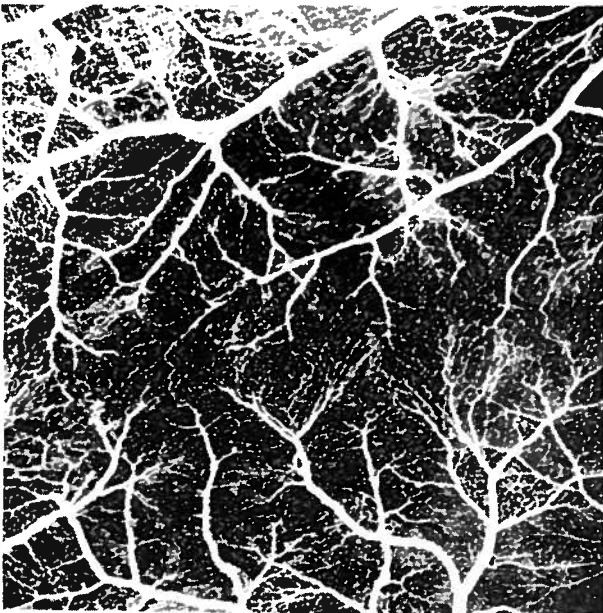

Fig. 1 — Fluorescein angiography of a retina (arterio-venous phase) of the pig, displaying the whole of the capillary network.

It could be said that microcirculation necessarily encompasses hemorheology since the bloodflow through the capillary vessels not only depends on the vascular caliber and on the physical characteristics of the vessel wall but is also largely influenced by physico-chemical properties, of the blood, mainly its viscosity. Although bloodflow through the vascular system is related to the heart's pumping force, it also depends, to a great extent, as far as microcirculation is concerned on physico-chemical properties of the blood, taking the caliber of the sclerosed small vessels as a constant. This mechanism has been well known for long but the role played by hemorheologic abnormalities in vascular disorders is not yet generally accepted, maybe because of defective knowledge and difficulties of the evaluation methods available, what seriously hinders the correction of these situations in clinical practice.

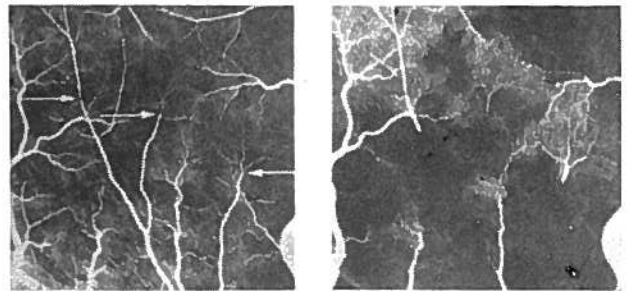


Fig. 2 — Angiography after experimental arteriolar spot (arrows) occlusion showing (left) lack of bloodflow beyond the occluded (arrows) and (right) already filled ischemic areas seconds after several cycles of retinal circulation in an experimental embolisation (platelet emboli in the pig).

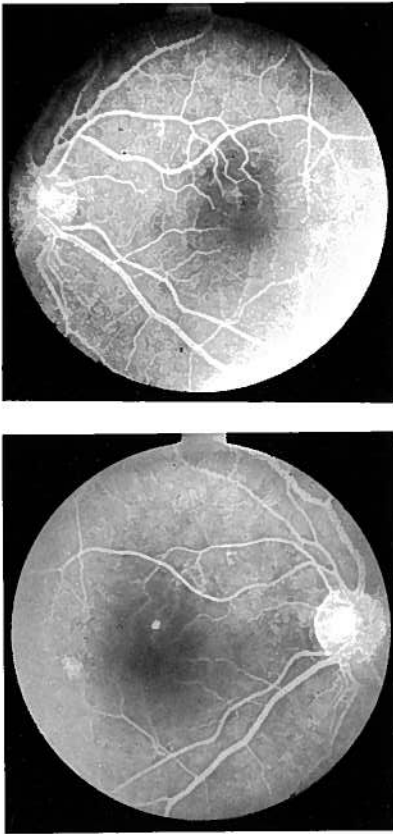


Fig. 3 — Retinal angiographic evaluation in a patient with increased permeability and disruption of the external blood-retinal barrier (pigment epithelium) (Note the absence of leakage from the blood in the early transact phase).

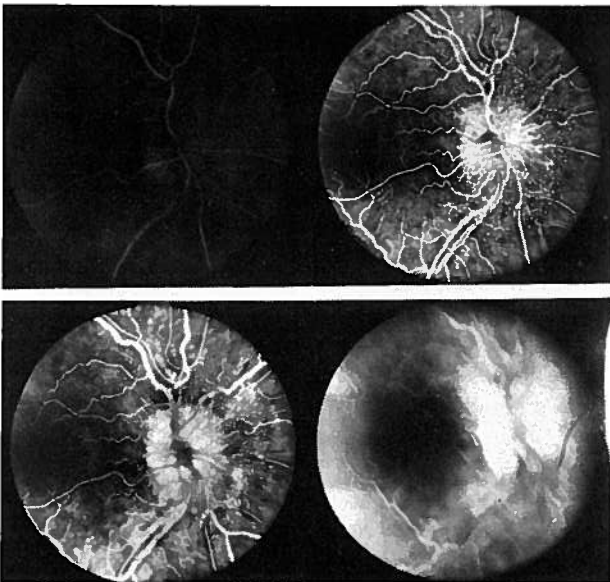


Fig. 4 — Fluorescein angiography of human retine (4 phases) showing besides morphologic aspects abnormal blood vessels and capillary dilatations in the area of the optic disc and still in the late phase, the leakage and staining of the retinal tissue (morphology, circulatory dynamics and vascular permeability in a case of papilloedema).

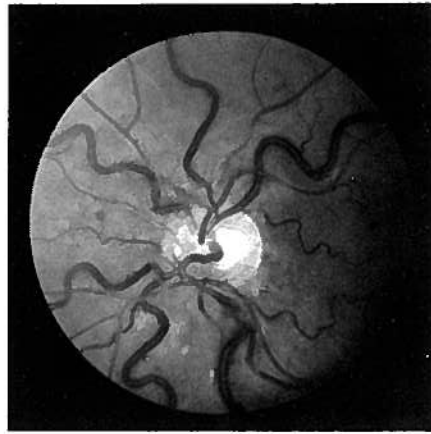

Fig. 5 — Photograph of the retina showing dilatation and tortuosity of the venules (venous stasis) in a patient with Waldenstrom's macroglobulinemia.

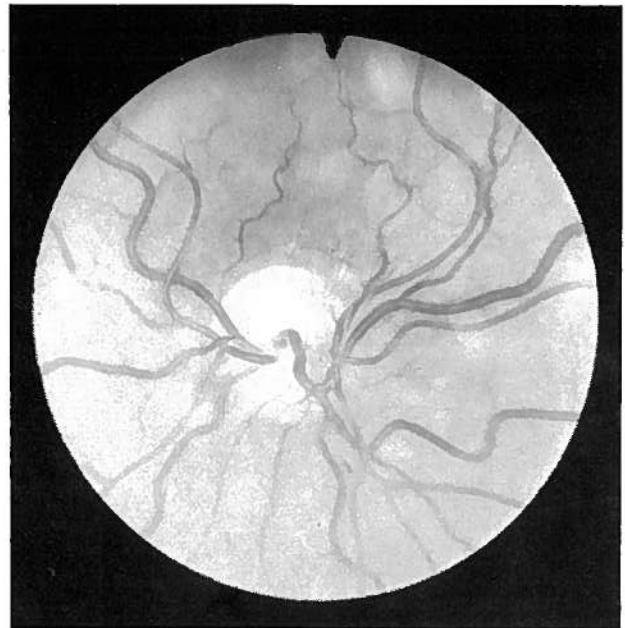


Fig. 6 — Photograph of the same retina after plasmapheresis and reduction of the macroglobulins to normal levels. Note the decrease in venular caliber (about 25%). A similar reduction of the caliber and normalization of retinal aspects was also observed in the same patient after administration of penicillamine in the course of another rise in macroglobulin levels.

In the last few years blood viscosity, red cell rigidity and other physico-chemical properties of the blood have been subjected to increased clinical interest either by the general practitioner or by the specialists. Several papers have been published and discussed in international meetings, dealing with the influence of hemorheologic abnormalities in cardiovascular diseases, diabetes, pregnancy, skin disorders and general thrombo-embolic pathology.<sup>1-5</sup>

The study of the microcirculation comprising direct examination of the small vessels under physiologic conditions, by means of non-invasive techniques, is difficult. The retina with its transparent structure, terminal vascularization and small thickness (100-400 micra), combines exceptional conditions for the evaluation of small blood vessels resorting to the particular optic characteristics of the eyeball that allow a 14 fold magnification of all the structures without the need of microscopy. Both in animal experiments and in human practice the whole capillary network may be observed and the morphology, dynamics and vascular permeability characteristics may be studied with the help of fluorescein angiography of the retina, and fluorophotometry (Fig. 1, 2, 3, 4).

Clinical hemorheology already has and shall have in the future even more pharmacological and therapeutic implications. Plasmapheresis or pharmacological reduction of macroglobuline<sup>6</sup> is a therapy used in the disorders that course with hyperviscosity, clearly improving hemorheological parameters within a short while. Retinal abnormalities in Waldenström's macroglobulinemia are rapidly controlled after plasmapheresis or administration of penicillamine (Fig. 5 and 6). Drug therapy of the disorders of hyperviscosity syndromes has strong implications in the oxygen transport and its dissociation.

## REFERENCES

1. DORMANDY, A.; HOARE, E.; COOLLEY, J.; ARROWSMITH, D. E. and DORMANDY, T. L.: (1973): *Brit. Med. J.* IV: 576.
2. DORMANDY, J. A.: (1980): *Brit. J. Haematol.*, 45: 519.
3. DORMANDY, J. A.: (1982): *J. Roy. Soc. Med.* 75: 561.
4. HUMPHREY, P. R. D.; DUBOULAY, J. H. and MARSHALL, J.: (1979): *Lancet*, ii: 873.
5. LETCHER, R. L.; CHIEN, S.; PICKERING, T. G.; SEALEY, J. E. and LARAGH, J. H.: (1981): *Amer. J. Med.* 70: 1195.
6. RAMALHO, P. S.: (1969) *Proc. Int. Symp. Fluorescein Angiography Albi*, P. Amalric (ed.), Karger-Basel 1971, pp. 675.

Address for reprints: P. S. Ramalho  
Department of Ophthalmology  
Hospital Sta. Maria  
Lisbon. Portugal