

Vulvar Lipoma: A Rare Diagnosis

Lipoma Vulvar: Um Diagnóstico Raro

Carla NUNES¹, Vera OLIVEIRA², Jorge RIBEIRO²
Acta Med Port 2013 Jan-Feb;26(1):70-70

Keywords: Lipoma; Vulvar Neoplasms.

Palavras-Chave: Lipoma; Neoplasias da Vulva.

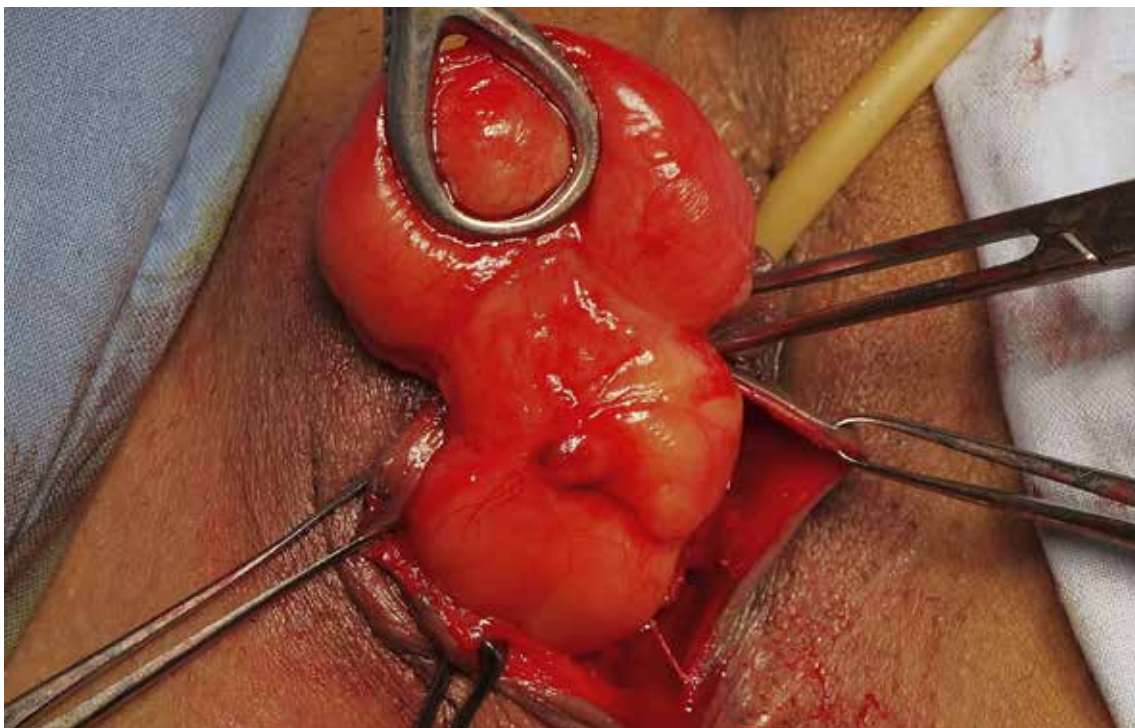


Figure 1 - Surgical excision of a large vulvar lipoma.

A 51-year-old healthy caucasian female was referred with a 1-year history of a sessile tender vulvar mass affecting the Bartholin's gland and the right labia majora, suggesting a lipoma. A complete surgical excision was undertaken (Fig. 1). Histological examination confirmed the presence of a vulvar lipoma, with the biggest diameter of 13 cm. The patient was found to be clinically asymptomatic three months after surgery.

Lipomas are frequent tumours, yet rarely occur in the vulva.¹⁻⁵

In 2004, there were approximately 70 reported cases

worldwide.¹

These slow growing tumours have a benign clinical evolution, but may reach moderate dimensions.^{3,5} Clinical manifestations depend on the specific vulvar location and dimension⁵, being more frequent on the right side.⁵

In order to optimize clinical and management approach, although it is a rare and benign tumour, it must be recognized from other entities that constitute its differential diagnosis. These include a Bartholin gland's cyst, an inguinal hernia, a liposarcoma and other vulvar tumours^{3,5}.

REFERENCES

1. Agarwal U, Dahlya P, Sangwan K. Vulval lipoma: a rare occurrence. *Arch Gynecol Obstet*. 2004;270:59-60.
2. Sherer DM, Gorelick C, Wagreich A, Lee YC, Serur E, Zigalo A, et al. Sonographic findings of a large vulvar lipoma. *Ultrasound Obstet Gynecol*. 2007;30:786-7.
3. Kehagias DT, Smymiotis VE, Karvounis EE, Gouliamos AD, Creatsas G. Large lipoma of the vulva. *Eur J Obstet Gynecol Reprod Biol*. 1999;84:5-6.
4. Cheng CC, Ho CM, Liu CY. Atypical lipomatous tumors of the vulva. *Taiwan J Obstet Gynecol*. 2011;50:379-80.
5. Oh JT, Choi SH, Ahn SG, Kim MJ, Yang WI, Han SJ. Vulvar lipomas in children: an analysis of 7 cases. *J Pediatr Surg*. 2009;44:1920-3.

1. Department of Gynaecology and Obstetrics, Santa Maria Hospital, Lisbon, Portugal.

2. Department of Gynaecology and Obstetrics, Caldas da Rainha Hospital Center, Caldas da Rainha, Portugal.

Recebido: 11 de Setembro de 2012 - Aceite: 02 de Novembro de 2012 | Copyright © Ordem dos Médicos 2013

