

## COMPOSITE VALVED APICO-AORTIC CONDUITS FOR LEFT VENTRICULAR OUTFLOW OBSTRUCTION

*Denton A. Cooley and John C. Norman*

Division of Surgery and Cardiovascular Surgical Research Laboratories, Texas Heart Institute of St. Luke's Episcopal and Texas Children's Hospitals, Houston, Texas.

### SUMMARY

Problems related to the left ventricular outflow tract are not always amenable to conventional surgical methods, and in some cases may be solved with the creation of a double outlet left ventricle, using a composite rigid pyrolytic left ventricular apex outlet prosthesis and a fabric valve-containing conduit.

The primary indication for apico-aortic conduits is severe left ventricular outlet obstruction that is not correctable by conventional surgical techniques. Failure to relieve ventricular hypertension causes persistent physiologic derangements that include increased left ventricular work and oxygen consumption, decreased cardiac output, and compromise of coronary perfusion.

Our clinical experience in excess of 48 months with valved apicoaortic conduits for primary or recurrent left ventricular outflow tract obstructions has been promising and is described in this report.

The basic mechanical defects in left ventricular outflow tract obstructions include supraventricular, valvular, subvalvular and cavitary stenoses. These lesions present a spectrum of decreased cross-sectional areas and increased impedances to left ventricular outflow. They result in higher intra- or supraventricular pressures proximally, and lower systolic and pulse pressures distally. The major physiologic derangements are limited cardiac output, increased left ventricular work and oxygen consumption, and lowered coronary artery perfusion pressures. Without surgery, the pathologic results are left ventricular hypertrophy, angina pectoris and, on occasion, sudden death. Conventional surgical management for most such lesions is satisfactory, but in certain instances, the results achieved by standard methods are less than optimal. The surgeon may be limited by anatomic features, the presence of adhesions from previous procedures, or the possibility of producing heart block, aortic regurgitation, or perforation of the interventricular septum.

### CONCEPTS

The use of a composite valve-containing conduit to relieve left ventricular hypertension is not a new concept, but clinical applications required the evolution and refinement of certain techniques of total cardiopulmonary bypass. These include (Carrel 1910) use of cardioplegic solutions; (Jeger 1923) diagnostic radiography and echocardiography; (Sarnoff et al 1953) the fabrication of low porosity synthetic grafts; (Hufnagel 1951) the availability of stabilized glutaraldehyde-processed porcine aortic valved (Hancock) prostheses, or more reliable synthetic valve prostheses such as the Cooley-Cutter prosthetic valves; and (Templeton) the development of a reliable, durable thromboresistant, biocompatible material (L. T. I. Pyrolyte<sup>R</sup> Carbon) for the fabrication of a special rigid apex outlet prosthesis.

As early as 1910, Alexis Carrel described experiments in which bypasses were established from the left ventricle to the thoracic aorta with the use of vein grafts

(Carrel 1910). Prior to 1923, Jeger undertook similar studies (Jeger 1923). In 1955, Sarnoff, Donovan and Case (Sarnoff et al 1953) used a Lucite tube containing a modified Hufnagel (1951) ball-and-seat valve to direct the entire cardiac output from the left ventricle to the descending thoracic aorta. In dogs so treated, the ascending aorta could be totally and permanently occluded with apparent impairment of the circulation. Postoperatively, these animals ran, jumped and swam. In 1962-63, Templeton implanted prostheses similar to those described by Sarnoff in five patients with severe aortic valvular stenoses; one patient survived more than 10 years. Al-Naaman (1963) reported similar experimental approaches in 1962, as did Detmer, Johnson and Braunwald in 1971. Some of our relevant work was reported in 1972 (Norman et al) and further experimental studies were reported by Brown, Meyerowitz, Cann, McIntosh and Morrow (1974). In 1975, Bernhard and co-workers reported an operation in which a stainless steel conduit was connected from a patient's left ventricle to the descending thoracic aorta, and in the same year, we reported our clinical trials of a different technique based upon the same concept (Cooley et al 1975). Other more complex techniques have been evolved (Cooley et al 1976; Norman et al 1977; Blank et al 1976; Jones et al 1978).

## STATE-OF-THE-ART

At the time of this report, we have implanted our composite prosthesis in 27 pediatric and adult patients with various forms of primary or recurrent left ventricular outflow tract obstructions (Cooley et al 1975; Worman 1978; Worman et al 1976; Igo et al 1974). Many other institutions have used our rigid Pyrolite<sup>R</sup> left ventricular apex outlet prostheses with good results.

The absolute and relative indications and contraindications remain evolutionary. The specific instances in which we have used this approach are included in Table I. In general, primary or recurrent left ventricular outflow tract obstructions of any etiology, in any age group, seem amenable to these approaches (Norman et al 1976; Igo et al 1974).

## METHODS

### *Preoperative Preparation, Anesthesia and Intraoperative Monitoring*

Adults and children are prepared in the usual manner for cardiopulmonary bypass surgery. The preoperative medications may include digitalis and antiarrhythmic agents. Because all of these patients have primary or recurrent obstructions to left ventricular outflow, the major objectives of anesthetic management are to assure and maintain a relatively constant heart rate and blood pressure. For these reasons, Atropine and Scopolamine are not used. Premedication includes light sedation with diazepam or morphine and light general anesthesia is induced and maintained with halothane or narcotics (morphine/Demerol/fentanyl) in conjunction with N<sub>2</sub>O and Thiopental, based on heart rate and blood pressure.

### *Initial Operative Techniques*

Initially, a pre-clotted, tightly-woven graft\* was anastomosed to the left ventricular apex, brought through the subjacent diaphragm and anastomosed to an approx-

---

\* Meadox Medicals. 6 Raritan Road. Oakland. New Jersey 07346.

priately-sized porcine valve-bearing Hancock prosthesis\* previously anastomosed to the supraceliac abdominal aorta. The necessity of a rigid, thromboresistant left ventricular outlet prosthesis was subsequently appreciated. This requirement was substantiated by the observation of near obliteration of the graft inlet during peak systole and led to the fabrication, testing, modification, and incorporation of a special polished Pyrolite<sup>R</sup> carbon left ventricular apex outlet prosthesis with an integral Teflon\*\* sewing ring and low porosity graft extension, into the current composite prosthesis\*\*\*.

The initial technical considerations were related to: (Carrel 1910) the ease of extending a median sternotomy into the upper abdomen to expose the supraceliac abdominal aorta reentry, thereby avoiding the left pleural cavity to gain access to the descending thoracic aorta (Jager 1923); the avoidance of prosthetic valving mechanisms which would require chronic (Coumadin) anticoagulation; and (Sarnoff et al 1953) the positioning of the porcine valving mechanism superficially in the upper abdomen to facilitate subsequent replacement if necessary, without reentering the mediastinum.

### *Current Operative Techniques*

A median sternotomy is made and cannulations of the venae cavae and ascending aorta are performed in the usual manner (Fig. 1).

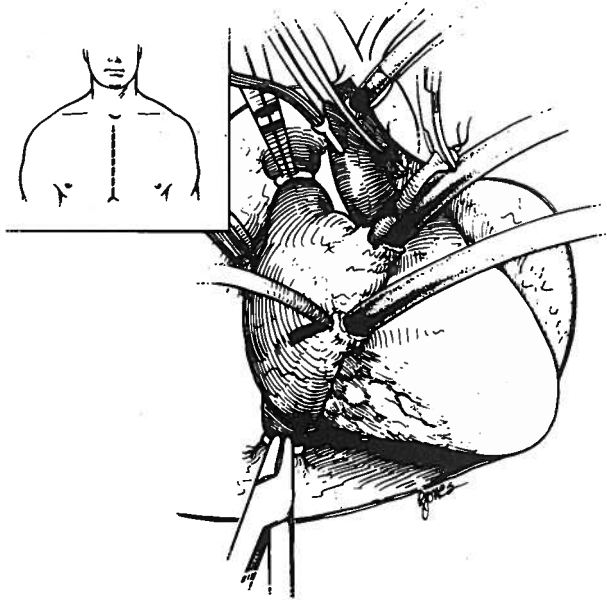


Fig. 1 — To determine the necessity, or advantages of creating a double outlet left ventricle, the patient is placed on total cardiopulmonary bypass via a median sternotomy with cannulation of the superior and inferior vena cavae and the ascending aorta. Special partially occluding caval clamps are used to assure capture of venous return. The ascending aorta is cross-clamped, cardioplegic solution with fresh propranolol infused and topical hypothermia induced.

\* Hancock Laboratories, Inc., 4633 La Palma Avenue, Anaheim, California 92807.

\*\* USCI: A Division of C.R. Bard, Inc., Box 566, Billerica, Massachusetts 01821.

\*\*\* Texas Technology Transfer Laboratories, Inc., 17 Charleston Park = 2920, Houston, Texas 77025.

Total cardiopulmonary bypass with hemodilution is used. Propranolol (0.5-1.0 mg) may be injected with the institution of bypass depending upon the degree of left ventricular hypertrophy. The left atrium is vented via the right superior pulmonary vein. The ascending aorta is crossclamped, just proximal to the origin of the innominate artery, and 500 ml of cardioplegic solution\* (to which 1.0 mg of light sensitive Propranolol is added) is infused in the aortic root. Topical hypothermia is induced with iced saline (4° C) and, after the heart stops, the proximal ascending aorta, the aortic valve, and the left ventricular outflow tract are examined to determine the necessity of advantages of fashioning a double-outlet left ventricle.

Once a decision is made, the median sternotomy is extended into the upper abdomen (Fig. 2). The transverse colon and stomach are retracted downward and to the right. After division of the triangular ligament, the left lobe of the liver is mobilized and retracted to the right (Fig. 3). The right crus of the diaphragm is then incised to expose a generous portion of the supraceliac abdominal aorta (Fig. 4). This segment of

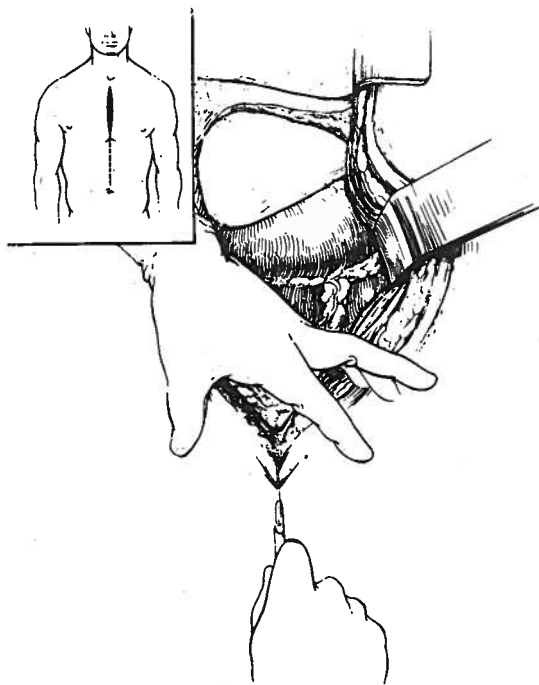


Fig. 2 — After examining the ascending aorta, the aortic valve and left ventricular outflow tract via an ascending aortotomy and reaching a decision, the median sternotomy is extended into the abdominal linea alba to the level of the umbilicus.

\* THI Cardioplegic Solution: 500 ml 5% Dextrose and 0.45% NaCl containing:  
 Potassium Chloride 20 mM (20 mEq) [1492.0 mg];  
 Magnesium Chloride 7.5 mM (15 mEq) [713.9 mg];  
 Sodium Bicarbonate 2.5 mM (2.5 mEq) [210.0 mg];  
 Calcium Chloride 1.0 mM (2.0 mEq) [147.14 mg].

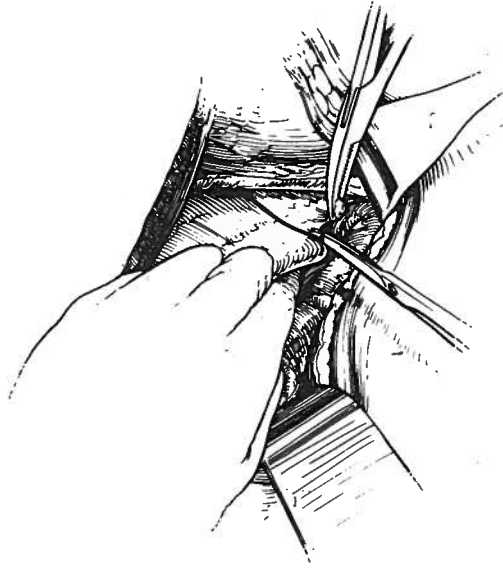


Fig. 3 — The stomach is retracted downward and to the left; the left lobe of the liver is retracted toward the right and the triangular ligament is divided to expose the supracoeliac abdominal aorta, beneath the diaphragm.

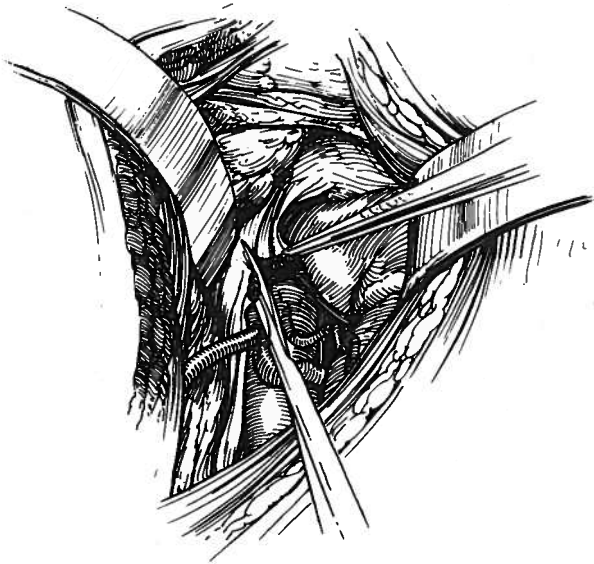


Fig. 4 — The right crus of the diaphragmatic hiatus is divided to expose a generous portion of the supracoeliac abdominal aorta. With adequate dissection, a 5-8 cm. segment of the supracoeliac abdominal, intradiaphragmatic and distal thoracic aorta can be exposed.

the abdominal aorta, just beneath the diaphragm, is encircled with umbilical tapes and a portion is isolated with a partial occluding vascular clamp. The distal end of an appropriately-sized Dacron graft containing a valve is anastomosed end-to-side to the abdominal aorta with a continuous 4-0 or 3-0 braided polyester suture (Fig. 5). An aperture is made in the left ventricular apex with a circular knife, adjacent to the left of the terminal radicles of the left anterior descending coronary artery (Fig. 6).

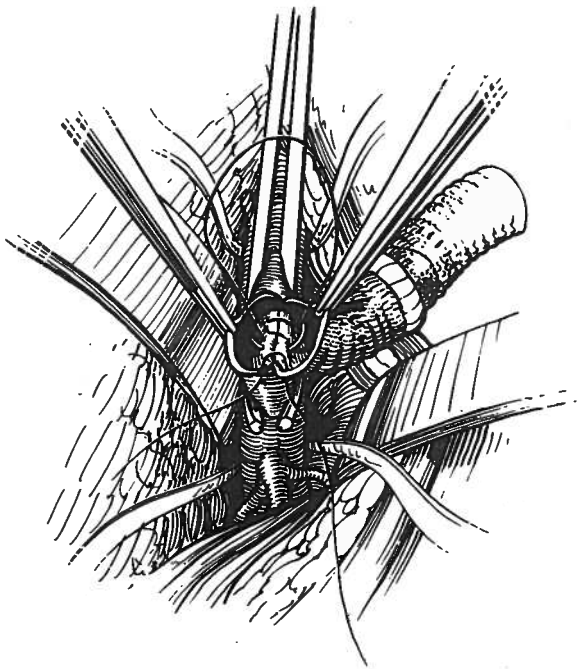
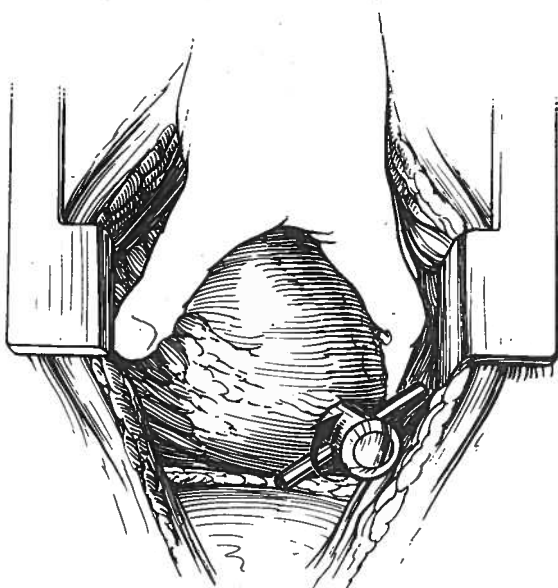


Fig. 5 — Umbilical tapes are passed around the exposed segment of the aorta, proximally and distally. A partial occluding vascular clamp is applied and an appropriate linear aortotomy is made. The distal end of the valve bearing graft is anastomosed end-to-side to the aorta with a running suture of 4-0 or 3-0 braided polyester.

Fig. 6 — The left ventricle is elevated and a circular aperture cut in the apex with a special knife, just to the left of the terminal radicles of the left anterior descending coronary artery. The circular segment of the left ventricular apex is removed and the left ventricular cavity examined and explored digitally to assure an unobstructed apical outflow tract.



The special polished Pyrolite<sup>R</sup> carbon rigid inlet prosthesis is then inserted into the left ventricular cavity with the longer extension positioned against the ventricular septum (Fig. 7).

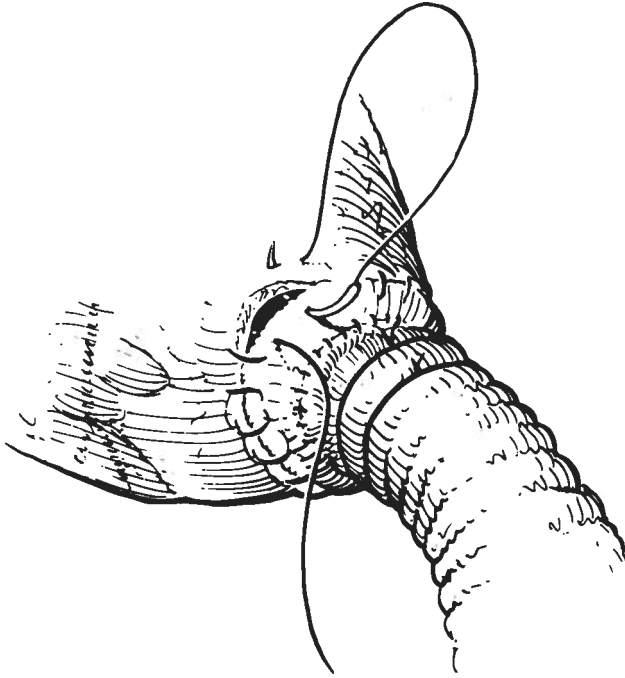


Fig. 7 — The proximal end of a special, rigid, polished Pyrolite<sup>®</sup> left ventricular apex outlet prosthesis is inserted into the apex with its longer extent positioned against the septum. The sewing ring of the prosthesis is secured to the left ventricular apex with a continuous suture of braided polyester reinforced with interrupted mattress sutures with felt pledgets.

The Teflon sewing ring is secured to the apex with a continuous suture of braided polyester and reinforced with interrupted mattress sutures, buttressed with felt pledgets. The graft extension of the prosthesis is then passed through an opening made in the diaphragm and tailored (in length) to result in a gentle curve for anastomosis to the abdominal valve-bearing segment (Figs. 8 and 9). Prior to releasing the ascending aortic cross-clamp, precautions are taken to evacuate any residual air from the composite conduit, proximal and distal to the valve, the left ventricle, and the ascending aorta. Depending upon the time required for performing the procedure, the entire operation may be accomplished during cold cardioplegic ischemic arrest. Intermittent coronary perfusion with release of the aortic clamp may also be used. In the presence of adequate cardiac hypothermia with pharmacologically induced cardioplegia, a period of circulatory arrest of more than 60 minutes is well tolerated.




Fig. 8 — The distal portion of the graft attached to the left ventricular apex outlet prosthesis is passed through the aperture in the diaphragm and anastomosed to the abdominal valve bearing segment.

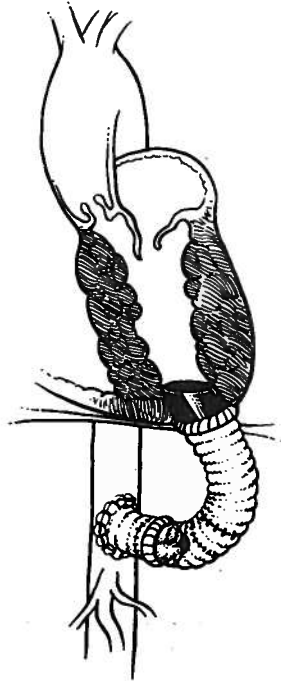


Fig. 9 — Schematic illustration of the rigid Pyrolite® apical left ventricular outlet prosthesis anastomosed to a valve-bearing conduit in a patient with left ventricular outflow tract obstruction and a deformed aortic valve.



After the cannulae have been removed, pressures are measured in the left ventricle, in the conduit proximal and distal to the valve and in the ascending aorta. In most patients we have temporarily occluded the ascending aorta to determine the effect upon the systemic circulation. Generally, after a brief fall in blood pressure of approximately 20 percent, the systemic pressure rises to a normal level, indicating that the conduit could, if necessary, conduct the entire left ventricular output.

### *Alternative Techniques*

We currently prefer the aforementioned methods. There are alternative methods that can be employed. For example, situations could be encountered where the composite conduit could be implanted within the mediastinum to course from the left ventricular apex to the ascending aorta or the undersurface of the aortic arch. This would avoid entry into the abdomen, but would require re-entry into the mediastinum for subsequent replacement of the conduit valve. Or, the composite conduit could be implanted to course from the left ventricular apex to the descending thoracic aorta. This would require left thoracotomy and cardiopulmonary bypass from that approach. We have implanted such a composite conduit from the left chest without cardiopulmonary bypass by employing short periods (< 3 minutes) of induced ventricular fibrillation. This approach does not facilitate examination of the ascending aorta, the supra- and subvalvular areas. In other circumstances, the conduit could be implanted to course from the apex of the left ventricle to the infrarenal abdominal aorta. Its chronic presence within the free peritoneal cavity could, however, result in visceral encroachment, intestinal erosion or obstruction.

### *Other Approaches*

Figures 10, 11 and 12 depict the utility of variations in these approaches that we have used in three different circumstances. In the first, calcification of the ascending aorta and a calcific stenosed aortic valve in a patient with coronary artery occlusive disease precluded conventional methods. The L. V. apical polished Pyrolite<sup>R</sup> prosthesis was used, and two saphenous vein grafts from the conduit, distal to the heterograft valve, were brought back through the diaphragm and anastomosed to the left anterior descending and first obtuse marginal branches of the circumflex. The results were good for both lesions (calcific aortic stenosis and coronary artery occlusive disease). In the second instance, the patient had undergone aortic and mitral valve replacement and had residual aortic (prosthetic) valvular stenosis with hemolysis. (Cooley and Worman 1977). Implantation of the composite valved conduit resolved both problems. In the third instance, the patient had a deformed, stenotic aortic valve in association with coarctation of the aorta and cerebral ischemia. Staged implantation of the composite conduit and, subsequently, a 12-mm graft from the conduit distal to the valve, beneath the diaphragm to the ascending aorta resolved both problems.

### *Postoperative Care*

For the most part, these patients have not presented any special problems other than those experienced by other patients undergoing openheart operations. After 48 hours in the Intensive Care Unit, where vital signs are monitored continuously and appropriate pharmacologic and respiratory support measures are utilized, they are returned to routine care in the hospital. Dismissal from the hospital has occurred on an average of 10 days after operation.

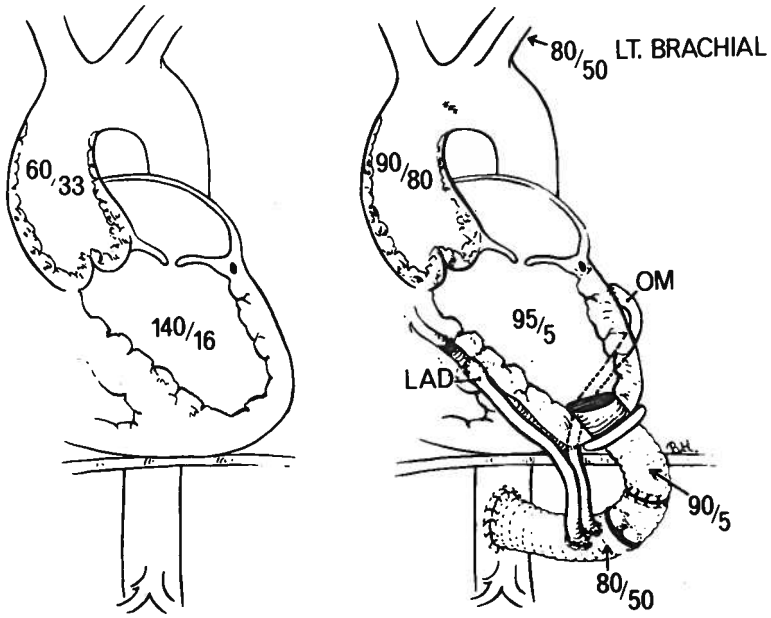


Fig. 10 — Diagram of the procedure in Case 5 (Table 1)

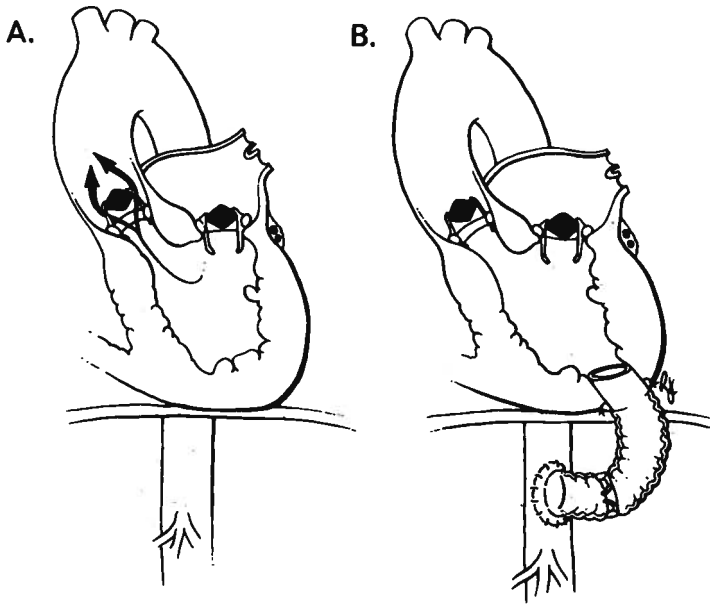


Fig. 11 — Diagram of the procedure in Case 21 (Table 1)

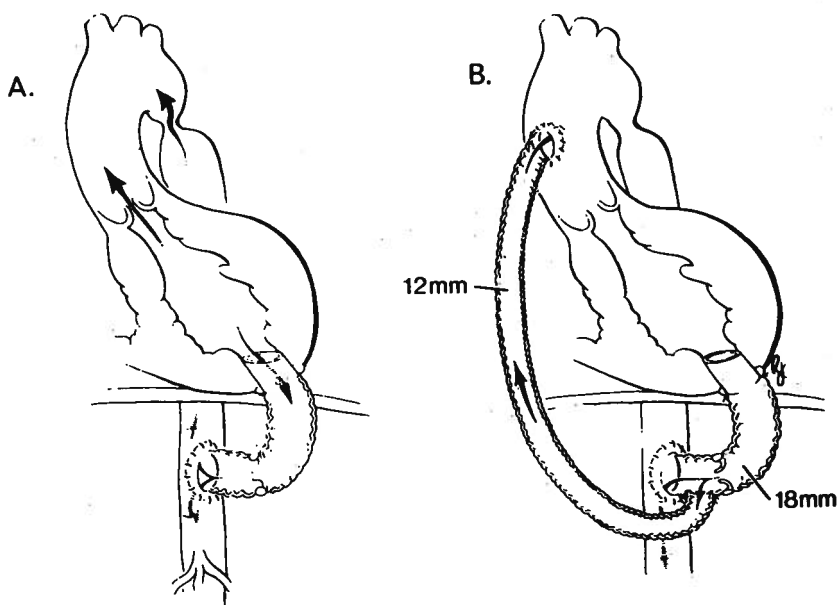


Fig. 12 — Diagram of a procedure in which the conduit was inserted elsewhere and a graft from the conduit, distal to the valve, to the ascending aorta was inserted in our institution to alleviate symptoms of cerebral ischemia.

### *Anticoagulants*

For most patients in whom the conduit contained a heterograft valve, no long-term anticoagulants have been used. In some, aspirin and Persantine were started on the third postoperative day. Coumandin was continued in those patients who already had a synthetic prosthetic valve in the aortic or mitral annulus. In only one patient was a synthetic valve prosthesis (Cooley-Cutter) used in the conduit. She already had a similar small diameter valve in the aortic annulus and was re-operated upon because of hemolysis and residual left ventricular hypertension. Antibiotic coverage during the early postoperative period has been used in all patients.

### EXPERIENCE OF OTHERS

In New Haven, Stansel has employed this technique in five patients (Stansel). In one, a 2-year-old boy with aortic insufficiency, the aortic valve was closed and the valved left ventricular apical conduit became the sole egress for left ventricular output. We have not yet done this, but suggested its feasibility a number of years ago (Fig. 13).

In St. Louis, Weldon has reported good results in two patients in whom used a stainless steel apical prosthesis of his own design (Weldon). In treating an infant with aortic atresia, he reported an unsuccessful attempt to fashion a new apical outlet with a reversed saphenous vein, which was the original experimental technique used by Carrel in 1910. We have sent small (12mm O. D.) L. V. apical polished Pyrolite<sup>R</sup> prostheses to others for use in infancy.

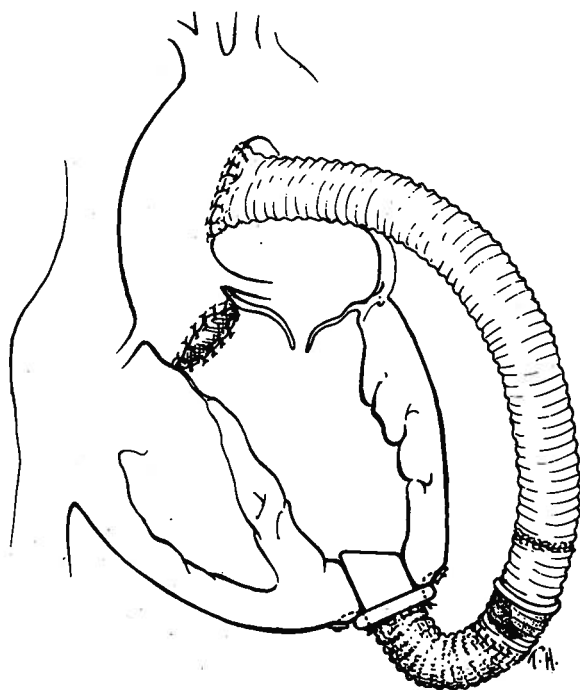


Fig. 13—Diagram of composite conduit extending from the left ventricular apex to the undersurface of the aorta with closure of the aortic annulus.

## RESULTS

We have employed these evolving methods in 27 patients. Their diagnoses, ages, sex, preoperative peak left ventricular systolic pressures, and left ventricular-ascending aortic gradients are summarized in Table 1. Their postoperative peak left ventricular systolic pressures and left ventricular-ascending aortic gradients are also summarized, as are the ratios of the antegrade flows (via the aorta) and retrograde flows (via the conduits). Some of the results are further summarized in figures 14 and 15. In figure 14, the data in nine patients are shown; the outflow tract-ascending aortic gradients were decreased approximately 85% or an average of 80 mmHg. In figure 15, the left ventricular pressures (mm Hg) are plotted against normalized systolic times, preoperatively and postoperatively. From such expressions of the data, mean left ventricular systolic pressures were derived. Postoperatively, time tension indices were reduced approximately 45% and calculated oxygen consumptions (MVO<sub>2</sub>'s) were decreased approximately 18%.

There were three early and three late mortalities in this series of 27 patients. These are summarized along with the corresponding diagnoses in Table 2. Two of the three who succumbed early were undergoing operation for supravalvular aortic stenosis and died immediately after surgery, raising the question of whether, in that anomaly, diverting blood away from the coronary ostia compromises the coronary circulation. These were the only patients who did not have an immediately favorable hemodynamic response to operation. One patient with idiopathic hypertrophic subaortic stenosis

(IHSS) who had undergone previous unsuccessful conventional ventricular septectomy did not obtain a satisfactory reduction in intracavitary ventricular pressure. The third early death was due to left ventricular failure and was not related to the conduit. One of three late deaths occurred at three months; it was caused by bacterial endocarditis on the porcine valve of the conduit with sepsis and empyema, which was conduit related. One patient died after six months of a cerebral vascular accident, which was not conduit related. And after 44 months, one patient died of coagulopathy, which was not conduit related.

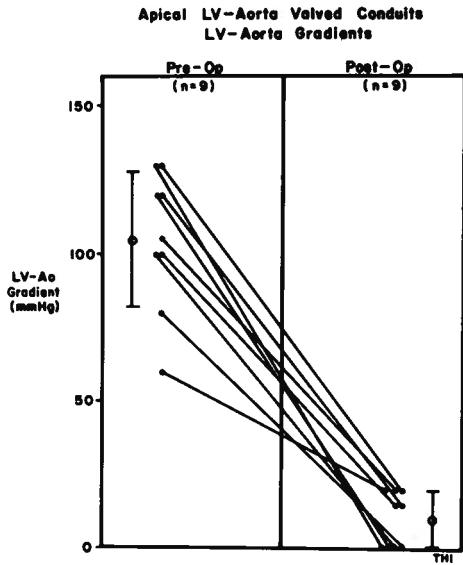


Fig. 14 — Left ventricular-ascending aortic gradients, before and after composite conduit implantation in nine patients. The gradients were reduced approximately 85% or an average of 80 mmHg.

Fig. 15 — Left ventricular peak systolic pressures vs. normalized systolic time plots in nine patients before and after composite conduit implantation. From these curves, indirect time-tension indices and MVO's were calculated. Both TTI's and MVO's were reduced approximately 45% and 18%, respectively.

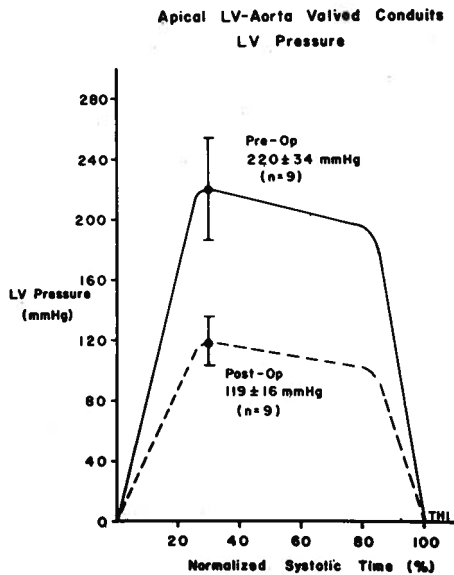


Table I  
*Specific Instances of Implantation of the Composite Prosthesis in 27 Patients*

Dx.	Age	Sex	PREOPERATIVE		POSTOPERATIVE			
			LVP (mm Hg)	LV-Ao Gradient (mm Hg)	LVP (mm Hg)	LVP-Ao Gradient (mm Hg)	AoQ (%Co)	Conduit Q (%Co)
(1)	11	F	250	120	130	15	71	29
(2)	7	M	200	80	135	10	59	41
(3)	15	F	220	130	120	10	66	34
(4)	36	M	250	130	130	20	76	24
(5)	72	M	140	40	130	20	60	40
(6)	39	F	220	80	100	0	---	---
(7)	15	M	260	90	170	20	68	32
(8)	18	F	230	130	180	60	84	16
(9)	4	M	205	100	100	0	---	---
(10)	5	F	180	80	---	---	---	---
(11)	9	M	240	150	---	---	---	---
(12)	8	F	185	65	---	---	---	---
(13)	27	F	150	54	120	5	67	33
(14)	16	F	285	150	120	15	55	45
(15)	18	M	240	60	180	50	85	15
(16)	28	M	150	40	100	0	---	---
(17)	20	M	---	---	---	---	---	---
(18)	8	M	180	60	100	10	---	---
(19)	15	M	230	94	---	---	---	---
(20)	12	M	200	120	120	10	---	---
(21)	49	M	220	100	---	---	---	---
(22)	9	M	220	115	---	---	---	---
(23)	66	M	240	40	---	---	---	---
(24)	15	M	210	105	110	0	---	---
(25)	23	F	230	100	130	0	---	---
(26)	65	M	---	---	---	---	---	---
(27)	8	F	200	100	---	---	---	---
Mean:			213+36	93+33	128+26	14+17	69+10	31+10

(1) Congenital AS-AI, previous valvotomy; (2) Supravalvular AS, previous aortoplasty; (3) Supra and subvalvular AS, previous aortoplasty; (4) Subvalvular AS, previous resections; (5) Calcific AS, calcific annulus and ascending aorta; (6) Calcific AS, previous AVR\* with small annulus; (7) Supravalvular AS, previous aortoplasty; (8) IHSS; (9) Congenital AS; (10) Subvalvular AS; (11) Congenital supravalvular AS, pulmonary branch stenosis; (12) Subaortic stenosis, MI, previous coarctation, previous resections, previous ventriculotomy; (13) AS, previous AVR,\* small annulus and hemolytic anemia; (14) Congenital supravalvular AS; (15) Congenital AS with small annulus, previous AVR\*; (16) Congenital AS with small annulus, previous valvotomy and commissurotomy; (17) Congenital subvalvular AS-AI, previous resections, PDA ligation and valvotomy; (18) Supra and valvular AS, branched pulmonary stenosis, previous resection and valvotomy; (19) AS-AI with small annulus, previous coarctation, valvotomy and AVR\*; (20) Congenital supra and valvular AS with small annulus, previous valvotomy; (21) Chronic hemolysis with small aortic annulus, previous calcific AS, noncalcific MS, AVR,\* and MVR\*\*; (22) Congenital supravalvular AS-MI, previous resections, AVR\*; (23) Calcific AS-AI and hemolytic anemia, previous AVR\*; (24) Congenital AS, small annulus, previous AVR,\* previous valvotomy; (25) Supravalvular aortic stenosis, previous aortoplasty; (26) prosthetic AS, previous AVR\* x 2, ACB x 1, pericardiectomy + pacemaker insertion (LV not entered at cath); (27) tunnel subaortic stenosis, AI, previous resection, VSD repair, MPA banding.

\*AVR = aortic valve replacement; \*\*MVR = mitral valve replacement

Table 2

*Apico-Aortic Conduit Grafts*

Diagnosis	No. Patients	Early Deaths	Late Deaths
<b>Congenital Aortic Stenosis</b>			
primary operation .....	3		1
previous valvotomy .....	3		
previous AVR .....	2		
previous valvotomy, subsequent AVR .....	1		
<b>Supravalvular stenosis</b>			
Valvular and Supravalvular stenosis	4	2	
primary operation .....	1		
previous valvotomy .....	1		
<b>Tunnel stenosis and IHSS</b>			
previous operation .....	1		
<b>Subaortic stenosis</b>			
previous operation(s) .....	5		2
<b>Previous AVR for RHD</b>			
with hemolytic anemia .....	4	1	
<b>Aortic stenosis and CAOD</b>			
previous operation(s) .....	1		
Total .....	27	3 (11%)	3 (11%)

## CONCLUSIONS

Our clinical experience with valved apico-aortic conduits for primary or recurrent left ventricular outflow tract obstruction has been promising. Fourteen of the patients in this report have been studied with the use of cardiac catheterization within 10 days following operation and six months postoperatively. Analyses of pressure, angiographic, and arterial velocity patterns have shown that the left ventricular-ascending aortic pressure gradients have been relieved, that left ventricular function has been preserved or improved, that blood flow is distributed normally throughout the systemic circulation, and that flow through the conduit is a function of the degree of the native left ventricular outflow tract obstruction in relation to conduit size and its inherent impedance. Follow-up of some of these patients to periods in excess of 48 months has shown that the procedure is well-tolerated and permits normal exercise, growth and development in children. In both children and adults, the operation relieves signs and symptoms of left ventricular outflow tract obstruction. Additionally, the hemolytic manifestations of increased sheer stress and turbulence due to aortic valve replacement in the adult with a small aortic annulus have been reversed. We have recently reoperated upon a patient wherein a direct fabric graft to the L. V. apex anastomosis with a conduit was utilized in another institution. This patient developed an aneurysm at that site. Reoperation with the use of the rigid Pyrolite L. V. outlet prosthesis resolved the problem and suggests that direct anastomosis of fabric grafts to the left ventricular apical myocardium should be avoided. A rigid Pyrolite carbon prosthesis provides a more satisfactory long-term result (Ugorjictal).

## RESUMO

**TRATAMENTO CIRÚRGICO DA OBSTRUÇÃO DA CÂMARA DE SAÍDA DO VENTRÍCULO ESQUERDO COM TUBOS APICO-AÓRTICOS VALVULARES**

Os problemas relacionados com a obstrução da câmara de saída do ventrículo esquerdo não são sempre passíveis de tratamento cirúrgico com métodos convencionais, e, em alguns casos, podem ser resolvidos com o estabelecimento de um ventrículo esquerdo com dupla câmara de saída usando uma prótese de *Pyrolite* rígida adaptada à ponte do ventrículo e ligada a um conduto valvulado.

A indicação primária dos condutos apico-aórticos é a obstrução grave da câmara de saída do ventrículo esquerdo não corrigível por meios cirúrgicos convencionais. A persistência de hipertensão articular provoca alterações fisiológicas persistentes com aumento do trabalho ventricular, do consumo de oxigênio, diminuição do débito cardíaco e compromisso da perfusão coronária.

A nossa experiência clínica, em mais de 48 meses, com condutos apico-aórticos valvulados para tratamento da obstrução da câmara de saída do ventrículo esquerdo, primária ou recidivante, tem sido prometedora e é descrita nesta comunicação.

## REFERENCES

- A. L. NAAMAN YD: Bypass procedure for aortic stenoses simplified. *Med Tribune* 4: 27, 1963.
- BERNHARD WF, POIRIER V, LA FARGE CG: Relief of congenital obstruction to left ventricular outflow with a ventricular-aortic prosthesis. *J Thorac Cardiovasc Surg* 19: 312, 1975.
- BLANK RH, PUPELLO DF, BESSONE LN, HARRISON EE, SBAR S: Method of managing the small aortic annulus during valve replacement. *Ann Thorac Surg* 22: 356, 1976.
- BROWN JW, MEYEROWITZ PD, CANN MS, McINTOSH CL, MORROW AG: Apical-aortic anastomosis: Experimental evaluation of a method for relief of diffuse left ventricular outflow obstruction. *Surg Forum* 25: 147, 1974.
- CARREL A: On the experimental surgery of the thoracic aorta and the heart. *Ann Surg* 52: 83, 1910.
- COOLEY DA, NORMAN JC: Severe intravascular hemolysis after aortic valve replacement: Reversal by left ventricular apico-abdominal aortic composite conduit. *J Thorac Cardiovasc Surg* 74: 322, 1977.
- COOLEY DA, NORMAN JC, MULLINS CE, GRACE RR: Left ventricle to abdominal aorta conduits for relief of aortic stenosis. *Cardiovasc Dis* 2: 376, 1975.
- COOLEY, DA, NORMAN JC, REUL GJ, KIDD JN, NIHILL MR: Surgical treatment of left ventricular outflow tract obstruction with apicoaortic valved conduit. *Surgery* 80: 674, 1976.
- DETMER DE, JOHNSON EH, BRAUNWALD NS: Left ventricular apex-to-thoracic aortic shunts using aortic valve allografts in calves. *Ann Thorac Surg* 11: 417, 1971.
- HUFNAGEL CA: Aortic plastic valvular prosthesis. *Bull Georgetown Univ Med Center* 4: 128, 1951.
- IGO SR, HUGHES DA, DALY BDT, HUFFMAN FN, NORMAN JC: Effects of retained blood pump inflow tubes on left ventricular function. *Proc 27th ACEMB* 16: 125, 1974.
- JEGER, cited by KUTTNER H: *Chirurgische Operationslehre*, 5th edition, Vol. 2, Barth, Leipzig, 1923.
- JONES EL, CRAVER JM, MORRIS DC, KING SB, DOUGLAS JS, FRANCH RH, HATCHER CR, MORGAN EA: Hemodynamic and clinical evaluation of the Hancock xenograft bioprosthesis for aortic valve replacement (with emphasis on management of the small aortic root). *J Thorac Cardiovasc Surg* 75: 300, 1978.
- NORMAN JC: Double-outlet left ventricles for primary or recurrent left ventricular outflow tract obstruction. *Practical Cardiol* 4: 143, 1978.
- NORMAN JC, COOLEY DA, HALLMAN GL, NIHILL MR: Left ventricular apical-abdominal aortic conduits for left ventricular outflow tract obstruction. *Circulation* 56: 62, 1977.
- NORMAN JC, NIHILL MR, COOLEY DA: Creation of double-outlet left ventricles for left ventricular outflow obstructions: Initial clinical results in six patients. *Trans Amer Soc Artif Intern Organs* 22: 332, 1976.
- NORMAN JC, WHALEN RL, DALY BDT, MIGLIORE J, HUFFMAN FN: An implantable abdominal left ventricular assist device (ALVAD). *Clin Res* 20: 855, 1972.



SARNOFF SJ, DONOVAN TJ, CASE RB: The surgical relief of aortic stenoses by means of apical-aortic valvular anastomoses. *Circulation* 11: 564, 1953.

STANSEL HC: Personal communication.

TEMPLETON JY: Personal communication.

WELDON CS: Personal communication.

UGORJI CC, COOLEY DA, NORMAN JC: Post-traumatic apical left ventricular aneurysm in a patient with left ventricular apicalabdominal aortic conduit: A case presentation. *Cardiovas Dis*, 6: (in press).

Adress for reprints: *Denton A. Cooley*  
*Cardiovascular Surgery*  
*P. O. Box 20345*  
*Houston, Texas 77025*  
*U.S.A.*