

TRAUMATIC BRAIN INJURY AND SHAKEN BABY SYNDROME

Wellingson S. PAIVA, Matheus S. SOARES, Robson L. O. AMORIM,
A. Ferreira DE ANDRADE, Hamilton MATUSHITA, Manoel J. TEIXEIRA

SUMMARY

Shaken baby syndrome is a serious form of physical child abuse, which is frequently overlooked. It is defined as vigorous manual shaking of an infant who is being held by the extremities or shoulders, leading to whiplash-induced intracranial and intraocular bleeding and no external signs of head trauma. This syndrome is seen most commonly in children under 2 years, mainly in children under 6 months. This article summarizes issues related to clinical presentation, diagnosis, risk factors, and interventions for healthcare professionals.

RESUMO

SHAKEN BABY SYNDROME E TRAUMATISMO CRANIANO

Shaken baby syndrome é uma forma grave de maus-tratos físicos, que é frequentemente negligenciado. É definida como agitação manual vigorosa de uma criança que está sendo realizada pelos ombros ou extremidades, causando hemorragias intracranianas e intra-ocular, sem sinais externos de traumatismo craniano. Esta síndrome é vista mais comumente em crianças menores de dois anos, principalmente em crianças menores de seis meses. Este artigo resume as questões relacionadas com a apresentação clínica, diagnóstico, fatores de risco e intervenções para os profissionais de saúde.

W.S.P., M.S.S., R.L.O.A., A.F.A.,
H.M. M.J.T.: Division of Neuro-
surgery. University of São Paulo
Medical School. São Pulo. Brasil

© 2011 CELOM

INTRODUCTION

Head trauma is the most frequent cause of morbidity and mortality in children who have suffered abuse. Billmire and Myers¹ report that, excluding uncomplicated skull fractures, 95% of serious intracranial injuries and 64% of all skull injuries in children under 1 year of age are consequences of child abuse^{1,2}. Besides that, 80% of all deaths due to head trauma in children under 2 years are provoked by the same trauma mechanism². In British surveys the annual incidence of inflicted subdural hemorrhage was 21.0 and 24.6 per 100 000 children under 1 year^{3,4}. Most children were aged less than 6 months⁴.

The syndrome of head injury due to child abuse was originally described by Caffey in 1972 in children under 2 years of age and it is more common in children under 6 months who had acute subdural hematoma, traumatic subarachnoid hemorrhage, and retinal bleeding associated with fractures of long bones, mainly⁵⁻⁷. The mechanism of intracranial lesions commonly found were postulated as a result of repeated episodes of acceleration / deceleration angle of short duration, in most cases. Many children with intracranial findings of the syndrome show little evidence of external injury to the physical examination^{8,9}.

When the history of trauma is reported, it is usually related to mild trauma (table 1).

The frequent lack of external injuries may be explained by the fact that the dissipation of angular acceleration of the force through a large surface and light^{9,10}. When the clinical history is complete it shows that the child's head was projected against a surface, causing a high deceleration force required to cause subdural hemorrhage and parenchymal serious injuries. To this sum, the frequent findings in patients with long-bone fractures, fractures of ribs, skin bruises, fractures of skull and contusions of focal cerebral parenchyma, without an accidental mechanism¹⁰⁻¹².

Clinical Aspects

This syndrome is seen most commonly in children under 2 years old, mainly in children under 6 months. These children are brought to the hospital because of irritability, inappetence, or sleepiness in mild cases, or due to seizures, apnea, or they are unresponsive in most serious cases^{13,14}. The history is often vague, and who brings the child to the doctor often is not the child's caregiver. In most cases, no history of trauma is present and the diagnosis can be elucidated when an asymptomatic subarachnoid hemorrhage (SAH) is diagnosed by CT scan of skull¹³ (Figure 2). Sometimes it is informed that the child was subjected to maneuvers of reanimation¹⁵.

A specific history of all providers is carried out. These lesions can occur in children of all social classes, commonly in families that the child has multiple caregivers, the parents are young, and caregivers have few financial resources, or others psychosocial disorders¹⁵. Abuse of alcohol and illicit drugs may be involved.

On neurological examination, a range of abnormalities can be found from mild irritability and drowsiness to deep coma¹⁶. Even in severe cases, children may show no specific neurological findings, but can be distinguished from normal children by a decrease of crying and little mimic with painful stimulus. The bregmatic fontanel may be curved. A careful inspection may reveal minor injuries, most often on the parieto-occipital region or less commonly, in the frontal region, which may be visible after several days. Retinal hemorrhages are frequent^{15,16}.

Radiological images

A skull radiograph may provide evidence of impact. As fractures heal without callus they cannot be dated. The American Academy of Pediatrics recommends computed tomography¹⁷. A skull CT scan may reveal acute subdural hematoma which may vary from small collections with little mass effect to lesions with noticeable expansive effect that requires neurosurgical removal. The hemorrhage may be unilateral or bilateral and it is located in a specific area,

Table 1 - Brazilian guidelines for Shaken Baby syndrome - Clinical conditions for suspect of Shaken Baby Syndrome

Should be suspected of abuse under the following conditions:
1. TBI with no history of trauma (sensitivity of 65-73% and specificity of 93-100%) ^{12,24}
2. History of TBI low impact (mainly occurring in children with persistent deficits)
3. Changes in the initial history
4. Providers who blame the brothers
5. Bruises in various stages of development
6. Multiple retinal hemorrhages, and bilateral extension to periphery
7. Subdural hemorrhages in different locations and with different densities or associated with diffuse brain swelling ¹⁸

TBI - Trauma Brain Injury

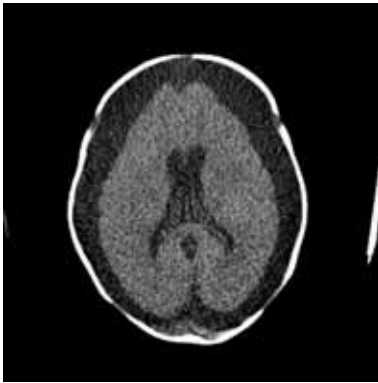


Fig. 2 - Patient 2 months yo, admitted in our service. CT scan demonstrating chronic subdural hematoma. Child underwent to hematoma drainage, without Social service has confirmed child abuse by provider.

as a result of the head impact, with displacement of the bones through the lambdoid suture causing stretching of the underlying venous sinus and deep cerebral veins^{15,17}.

MRI is generally superior to CT scan to show laminar subdural hematomas, especially in the posterior fossa and small cerebral contusions. MRI is also useful in the diagnosis of arteriovenous malformations or other vascular anomalies when there is no history or radiographic evidence of trauma but the child has an acute intracranial hemorrhage. When it is possible, computed tomography should be complemented by MRI 2–3 days later¹⁸. Now the MRI diffusion weighted imaging has assumed an important role in the diagnosis of shaken baby syndrome. The fastest, most sensitive and specific method of determining a shaking injury is diffusion weighted MRI^{18,19}. However CT scan with clinical history and physical findings are used more frequently to diagnosis in clinical practice.

Pathophysiological Mechanism

When an infant is violently shaken the subsequent traumatic axonal damage has been described in clinic-pathological terms as diffuse axonal injury or axonal shearing^{15,20}. In severe cases, the brain may lose its differentiation between gray and white matter and have the appearance of a large unilateral or bilateral supratentorial infarction on CT. This finding may be visible on initial CT or develop during the first 2 days after TBI¹⁷. Children with this finding are commonly unresponsive in the admission and have a neurological prognosis bleak. The pathophysiology of this *black brain* is still controversial, but should occur by the synergistic effects of hypoxia, the mechanism of trauma, and subdural hemorrhage^{11,21}. In some children, spinal cord injury can be found, contributing to the apnea and worse outcome observed^{11,14}.

According to more recently theory, infants possess certain predisposing factors for head injury, such as relatively

bigger skull size and weight, cervical musculature flaccidity, nervous system vasculature fragility, weaker skull and vulnerability of the bridging veins due to larger subarachnoid spaces¹⁵. The combination of these predisposing factors, when the child is shaken while being held by the limbs or trunk would lead to subarachnoid hemorrhage, subdural and retinal hemorrhages, diffuse axonal injury and cerebral edema. This pathophysiological mechanism should be suspected especially in the absence of evidences of external trauma^{11,22}.

Management

Since the initial steps have been taken care of, a diagnostic evaluation should be performed to identify associated lesions and to establish the etiology. An overall assessment for other occult injuries should be performed²³. In Brazilian guidelines for shaken baby syndrome adopted by Brazilian Medical Association elaborated for us²⁴, we recommend routine laboratory tests for anemia, thrombocytopenia, and coagulopathies are needed, and when they are normal the lesion may occur due to severe TBI, and as amended, does not necessarily indicate a pre-existing condition. The evaluation is mandatory and the skeleton of bone X ray and Skull CT scan may be useful in doubtful cases. When possible, computed tomography should be complemented by MRI 2–3 days later. A formal ophthalmologic evaluation, when possible, should be made for documentation of retinal hemorrhages, as these are frequent in this syndrome. Its occurrence should produce great suspicion for non-accidental trauma; in this case routine assistance for trauma must be performed and should be necessarily reported to social service of the hospital²⁵.

INSTRUCTIONS FOR ABUSE

IN CHILDREN REPORT ADOPTED IN BRAZIL

According to Brazilian law Number 1968, elaborated at 25 October 2001, cases of suspected or confirmed of abuse against children and adolescents should be necessarily reported to Guardianship Councils or court of Childhood and Adolescence in Communication plug defined by the Ministry of Health.

As in the United States, in Brazil physicians are obliged by law to report the incidence of child abuse to the government, even where there is only suspicion²⁵. Child assaulted has higher risk of fatal injury and therefore no one is free to transmit. The system protects the doctor's legal liability resulting from the identification of confirmed or suspected abuse in children. Despite the notification

procedures vary from state to state in Brazil, it is generally made by Social Services or the Brazilian Department of Health and Human Services.

CONCLUSIONS

Shaken baby syndrome represents a specific form of the abused child syndrome. This relatively unknown syndrome can produce multiple lesions in the victim. The incongruence between clinical history and physical findings in child abuse cases defies even the most skilled clinicians.

Conflito de interesses:

Os autores declaram não ter nenhum conflito de interesses relativamente ao presente artigo.

Fontes de financiamento:

Não existiram fontes externas de financiamento para a realização deste artigo.

REFERENCES

1. BILLMIRE ME, MYERS PA: Serious head injury in infants: accident or abuse? *Pediatrics* 1985;75:340-2
2. BRUCE DA, ZIMMERMAN RA: Shaken impact syndrome. *Pediatr Ann* 1989;18:482-494
3. JAYAWANT S, RAWLINSON A, GIBBON F et al: Subdural haemorrhages in infants: population based study. *BMJ* 1998;317:1558-61
4. BARLOW K, MINNS RA: Annual incidence of shaken impact syndrome in young children. *Lancet* 2000;356:1571-2
5. CAFFEY J: Multiple fractures in the long bones of infants suffering from subdural hematomas. *AJR* 1946;56:163-173
6. CAFFEY J: On the theory and practice of shaking infants: its potential residual effects of permanent brain damage and mental retardation. *Am J Dis Child* 1972;124:161-9
7. CAFFEY J: The whiplash shaken infant syndrome: manual shaking by the extremities with whiplash-induced intracranial and intraocular bleedings, linked with residual permanent brain damage and mental retardation. *Pediatrics* 1974;54:396-403
8. Committee on Child Abuse and Neglect: Shaken baby syndrome: inflicted cerebral trauma. *Del Med J* 1997;69:365-370
9. COODY D, BROWN M, MONTGOMERY D, FLYNN A, YETMAN R: Shaken baby syndrome: identification and prevention for nurse practitioners. *J Pediatr Health Care* 1994;8(2):50-6
10. SPAIDE RF, SWENGEL RM, SCHARRE DW, MEIN CE: Shaken baby syndrome. *Am Fam Physician* 1990;41(4):1145-52
11. BONNIER C, MESPLES B, CARPENTIER S, HENIN D, GRESSENS P: Delayed white matter injury in a murine model of shaken baby syndrome. *Brain Pathol* 2002;12(3):320-8
12. MUNGAN NK: Update on shaken baby syndrome: ophthalmology. *Curr Opin Ophthalmol* 2007;18(5):392-7
13. BELLEMARE S: Shaken baby syndrome vs inflicted brain injury. *Am J Emerg Med* 2007;25(9):1080
14. DUHAIME A, CHRISTIAN CW, RORKE LB et al: Nonaccidental head injury in infants—the “shaken-baby syndrome”. *N Engl J Med* 1998;338:1822-9
15. Blumenthal I. Shaking baby syndrome. *Postgrad Med J* 2002;78(926):732-5
16. CARBAUGH SF: Understanding shaken baby syndrome. *Adv neonatal Care*. 2004;4(2):105-114
17. American Academy of Pediatrics, Committee on Child Abuse and Neglect: Shaken baby syndrome: rotational cranial injuries. Technical report. *Pediatrics* 2001;108:206-210
18. SUH DY, DAVIS PC, HOPKINS KL et al: Nonaccidental pediatric head injury: diffusion-weighted imaging findings. *Neurosurgery* 2001;49:309-320
19. BIOUSSE V, SUH DY, NEWMAN NJ et al: Diffusion-weighted magnetic resonance imaging in shaken baby syndrome. *Am J Ophthalmol* 2002;133:249-255
20. CASE M, GRAHAN MA, HANDY TC et al: Position paper on fatal abusive head injuries in infants and young children. *Am J Forensic Med Pathol* 2001;22:112-122
21. FELDMAN KW, BETHEL R, SHUGERMAN RP, GROSSMAN DC, GRADY MS, ELLENBOGEN RG: The cause of infant and toddler subdural hemorrhage: a prospective study. *Pediatrics* 2001;108:636-646
22. DATTA S, STOODLEY N, JAYAWANT S, RENOWDEN S, KEMP A: Neuroradiology aspects of subdural haemorrhages. *Arch Dis Child* 2005;90:947-951
23. JENNY C, HYMEL KP, RITZEN A, REINERT SE, HAY TC: Analysis of missed cases of abusive head trauma. *JAMA* 1999;281:621-6
24. DE ANDRADE AF, MARINO R, CIQUINI O, FIGUEIREDO EG, MACHADO AG: Guidelines for neurosurgical trauma in Brazil. *World J Surg* 2001;25:1186-201
25. DE ANDRADE AF, PAIVA WS, AMORIM RL, FIGUEIREDO EG, TEIXEIRA MJ: Brazilian Guidelines for Traumatic Brain Injury. In Bernardo WM. Guidelines of the Brazilian Medical Association, *Braz Med Assoc* 2010