

# Foreign Body Ingestion: Rare Cause of Cervical Abscess



## Ingestão de Corpo Estranho: Causa Rara de Abscesso Cervical

Liliana COSTA<sup>1,2</sup>, João LARANJEIRO<sup>1,2</sup>, Carla PINTO MOURA<sup>1,2</sup>, Margarida SANTOS<sup>1</sup>  
*Acta Med Port* 2014 Nov-Dec;27(6):743-748

### ABSTRACT

**Introduction:** Foreign body ingestion is a frequent emergency occurrence. Serious complications, although rare, include pharyngo-oesophageal perforation, aorto-oesophageal fistula and deep neck infection.

**Material and Methods:** A retrospective review was performed of all cases of foreign body ingestion requiring hospitalization between 1989 and 2011, in a tertiary Hospital. Cases complicated by deep cervical abscess were selected and their clinical presentation, results of diagnostic exams, therapeutics and clinical evolution are presented.

**Results:** Among a total of 1679 cases, 319 were related to pediatric patients and 1360 to adults. Two cases were reported (0.12%): an adult, 41 years-old, with parapharyngeal abscess subsequent to fishbone ingestion, and a child, 13 months-old, with retropharyngeal abscess consequent to chicken bone ingestion. Complications appeared three and four days after foreign body removal, respectively. In both situations cervical computerized tomography scan with contrast and surgical drainage were accomplished; the child was also submitted to rigid esophagoscopy for residual foreign body removal and closure of the associated pharyngeal laceration.

**Discussion:** Deep cervical abscesses are an uncommon but possible complication of foreign body ingestion and constitute a diagnostic challenge, particularly in children. Previous oesophageal manipulation by flexible endoscopy may be considered a risk factor for such complication. Imagiological studies proved to be crucial for diagnosis and therapeutic planning.

**Conclusion:** Although a rare complication, given a recent history of foreign body ingestion/removal and the presence of compatible symptoms, cervical abscesses should be taken into account, highlighting their potential morbimortality in the absence of an appropriate therapeutic approach.

**Keywords:** Foreign Body; Abscess; Esophagoscopy; Neck.

### RESUMO

**Introdução:** A ingestão de corpo estranho é um motivo frequente de recurso à urgência hospitalar. As complicações graves, embora raras, incluem perfuração faringo-esofágica, fistula aorto-esofágica e infecção cervical profunda.

**Material e Métodos:** Foram analisados, retrospectivamente, os casos de ingestão de corpo estranho com internamento num hospital terciário, entre 1989 e 2011. Seleccionaram-se os casos complicados por abscesso cervical profundo, descrevendo-se a semiótica, resultados de meios complementares de diagnóstico, terapêutica efectuada e evolução clínica.

**Resultados:** Dos 1679 casos, 319 referentes a crianças e 1360 a adultos, reportam-se dois casos (0,12%): uma criança, 13 meses, com abscesso retrofaríngeo após ingestão de osso de frango e um adulto, 41 anos, com abscesso parafaríngeo após ingestão de espinha de peixe. As complicações manifestaram-se quatro e três dias após remoção do corpo estranho, respectivamente. Em ambos foram efectuadas Tomografias Computorizadas cervicais com contraste e drenagem cirúrgica dos abscessos; a criança foi ainda submetida a esofagoscopia rígida para remoção de corpo estranho residual e encerramento da perfuração esofágica associada.

**Discussão:** Os abscessos cervicais são uma complicação possível da ingestão de corpo estranho e constituem um desafio diagnóstico, principalmente em idade pediátrica. A manipulação esofágica prévia por fibroscopia poderá ser considerada um factor de risco. A imagiologia (Tomografia Computorizada cervical com contraste ou Ressonância Magnética Cervical) foi essencial para o diagnóstico e o planeamento cirúrgico.

**Conclusão:** Embora raros, perante a história recente de ingestão/remoção de corpo estranho esofágico e a presença de sintomas compatíveis, os abscessos cervicais devem ser tidos em consideração, dado o potencial de morbilidade e mortalidade na ausência de uma abordagem terapêutica adequada.

**Palavras-chave:** Corpo Estranho; Abscesso; Esofagoscopia; Pescoço.

### INTRODUCTION

Foreign body (FB) ingestion is a frequent emergency presentation. The location of the FB depends on the age of the patient, type of FB ingested and individual pathological conditions,<sup>1,2</sup> such as oesophageal stenosis or fistula, with direct influence in complications that may arise.

The most frequent lodged sites for FB are palatine tonsils, base of the tongue and oesophageal upper third.<sup>3-5</sup>

The majority of cases have a good prognosis, with removal of FB in the course of otolaryngological (ENT)

observation, by upper digestive endoscopy performed by Gastroenterology or, by rigid esophagoscopy under general anaesthesia.<sup>2,5</sup>

Serious complications resulting from FB ingestion, although rare, include pharyngo-oesophageal perforation, aorto-oesophageal fistula, carotid artery rupture and deep neck infection.<sup>6-10</sup> These complications are potentially fatal in the absence of a quick and proper intervention.<sup>11</sup>

Deep neck infections affect visceral spaces of the head

1. Department of Otorhinolaryngology. Centro Hospitalar São João. Porto. Portugal.

2. Porto Medical School. Porto University. Porto. Portugal.

Recebido: 23 de Março de 2014 - Aceite: 13 de Outubro de 2014 | Copyright © Ordem dos Médicos 2014



Table 1 - Comparison between cases

Case	Age	Sex	FB*	Flexible Endoscopy	Rigid Endoscopy	Days til symptoms	Abscess location	Bacteriology	Outcome
1	41 y <sup>†</sup>	♀	Fish spine	Yes	No	4	Parapharyngeal	–	Favorable
2	13 mo <sup>‡</sup>	♂	Chicken bone	No	Yes	3	Retropharyngeal	<i>K. pneumoniae</i> <i>S. maltophilia</i>	Favorable

\*FB – foreign body, †mo – months-old; ‡y – years-old

and neck and their contents.<sup>12,13</sup> Although the prevalence of deep neck infection has markedly decreased since antimicrobial drugs became available, these infections continue to be a cause of significant morbidity and mortality.<sup>12,14</sup> In addition to the systemic toxicity and the localized respiratory and digestive tract disturbance characteristic of these infections, more serious complications may result such as upper airway obstruction, descending mediastinitis, septic shock, internal jugular vein thrombosis, pleural empyema, pericarditis, pericardial effusion, aorto-pulmonary fistula, epidural abscess, carotid artery erosion, adult respiratory distress syndrome, acute renal failure and disseminated intravascular coagulopathy.<sup>13,14</sup> If any of these conditions occur, the results are ominous. The mortality rate can reach 40% to 50% in cases of mediastinitis.<sup>14</sup>

The aim of this work is to evaluate the cases of deep cervical abscess consequent to FB ingestion, namely relative incidence, kind of clinical presentation, associated bacteriology and predisposing factors. Additionally, therapeutic approach is also analysed.

## MATERIAL AND METHODS

A retrospective cohort of all consecutive cases of foreign body ingestion with hospitalization in a tertiary medical center - Centro Hospitalar São João (CHSJ) - between January 1989 and December 2011 was reviewed. The cases complicated by deep cervical abscess were selected, describing their clinical presentation, results of complementary diagnostic exams, performed therapeutics and clinical evolution.

## RESULTS

Within the 1679 cases hospitalized in CHSJ, 319 were pediatric patients, and 1360 were adults. Two cases (0.12%) complicated with deep cervical abscess: an adult, 41 years-

old, with parapharyngeal abscess subsequent to fish spine ingestion and a child, 13 months old, with a retropharyngeal abscess consequent to chicken bone ingestion (Table 1).

### Case 1

A 41 year old female, with a personal history of intermittent asthma and no regular medication, came to the emergency department in sequence of an intense left cervical pain and limitation of cervical mobility. She had recent history of esophageal FB removal, 3 days before, by upper digestive endoscopy performed by Gastroenterology. Since then she couldn't tolerate solids and liquids intake and the cervical mobility was progressively limited.

Cervical computerized tomography (CT) (Fig. 1) showed an uptake contrast area, with air, at the left lateral region of laryngo-tracheal transition, medial to the great vessels.

The patient underwent surgical drainage of the deep cervical abscess with collection of purulent exsudate for microbiological examination, and it was initiated intravenous empirical antibiotics with clindamycin and gentamycin. She presented an initial good evolution, and started oral feeding at the second post-operative day with good tolerance.

At fourth post-operative day, the patient complained of cervical pain and there was a purulent discharge through the drain and elevated C reactive protein in analytical control. It was performed a cervical CT scan that revealed left paratracheal abscess in relation to the percutaneous drain that was drained. It was maintained the medical treatment and the patient showed favorable clinical and analytical evolution. No bacterial agent was isolated in microbiological examination of the purulent exsudate.

The patient was discharged after 9 days of intravenous antibiotics. In the follow up visit, the patient was asymptomatic, without evidence of cervical infection and the cervical surgical wound was closed.

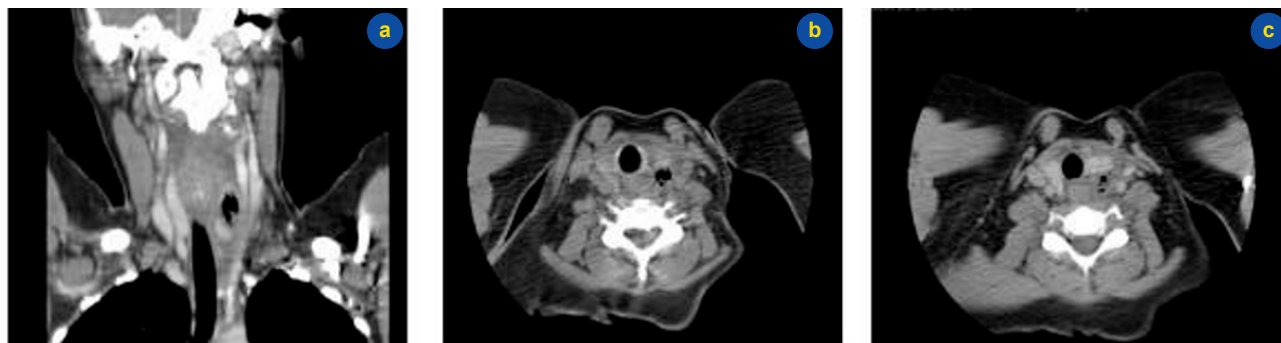


Figure 1 - Cervical CT: left cervical abscess. a) coronal cut; b) and c) axial cuts.

**Case 2**

A 13 months old male child, without significant pathological history, except an acute bronchiolitis in the neonatal period requiring hospitalization, presented an episode of choking with food (chicken) and was taken to the emergency department of the local hospital near home. The FB was considered totally expelled by the child. High fever and respiratory distress signs motivated a return to the emergency department four days after the initial episode. Physical examination revealed right cervical swelling and difficulty in cervical mobilization. At the oropharynx, it was observed a bulging of the posterior wall and a profuse salivary stasis. Analytical study only showed a slight increase in reactive C protein. Cervical CT scan revealed a FB with retropharyngeal location, suggestive of bone fragment and a retropharyngeal collection/abscess with 'air bubbles' extending from the oropharynx to the cervical-thoracic transition.

The child was transferred to ENT department of CHSJ and was submitted to rigid esophagoscopy under general

anesthesia, with FB removal (chicken bone) at the region of cricopharyngeal muscle.

He was admitted to the Pediatric Intensive Care Unit during the immediate post-operative period with endotracheal intubation and mechanical ventilation, feeding by nasogastric tube, intravenous antibiotics with vancomycin and imipenem, and systemic corticotherapy.

At the second post-operative day, it was performed a cervical CT scan control (Fig. 2) that showed a retropharyngeal collection with left tracheal deviation.

Despite the second surgery, the child persisted with respiratory distress signs. Imagiological reevaluation was performed (Fig. 3) and showed persistence of retropharyngeal gas forming collection, a clinical situation of difficult control. It was necessary another three re-interventions (exploratory cervicotomies) and, in the last

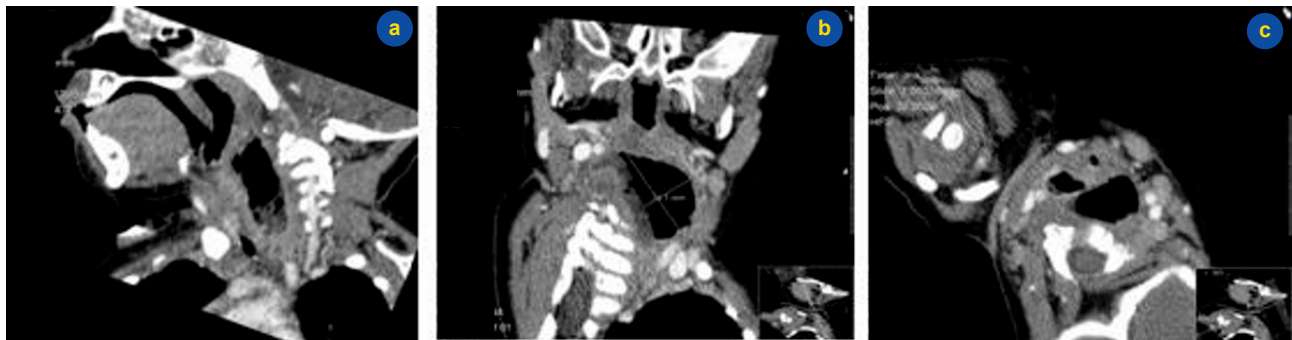

Figure 2 - Cervical CT: retropharyngeal collection with left tracheal deviation. a) sagittal cut; b) coronal cut; c) axial cut

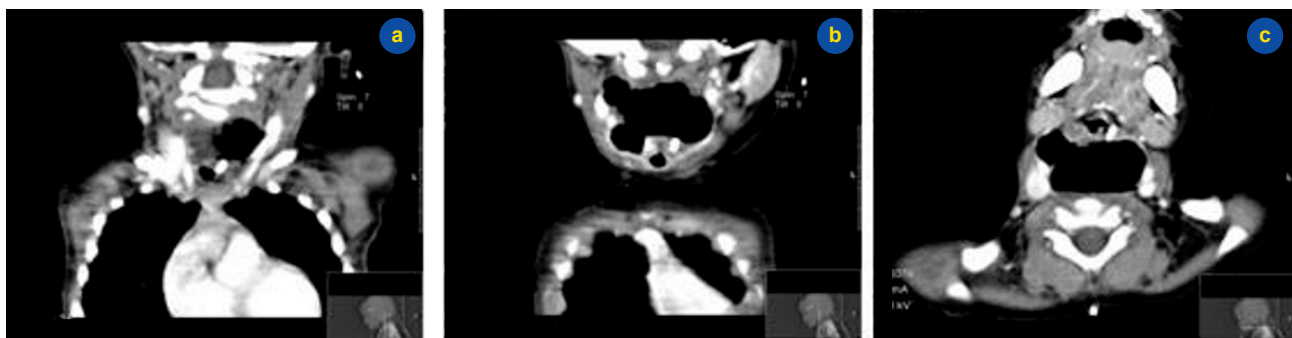


Figure 3 - Cervical CT: retropharyngeal gas forming collection. a) and b) coronal cuts; c) axial cut.

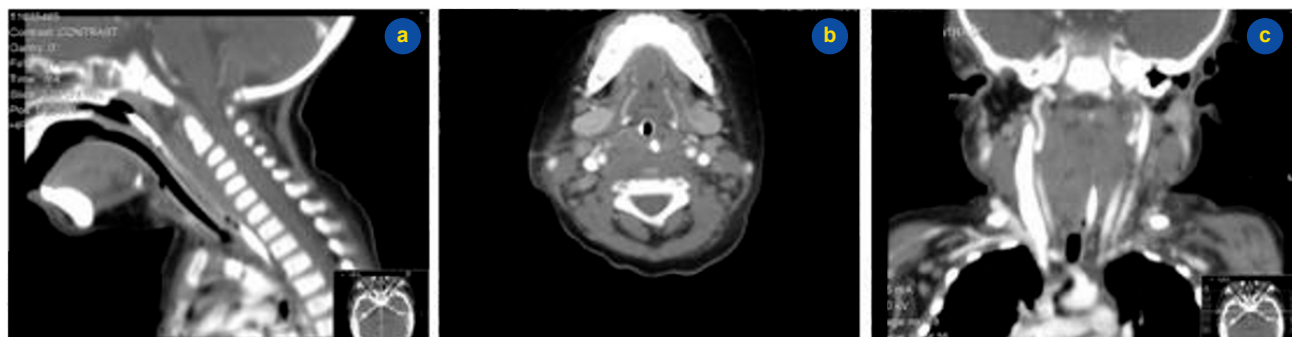


Figure 4 - Cervical CT after last surgery. a) sagittal cut; b) axial cut; c) coronal cut.

one, a rigid esophagoscopy was done with visualization and suturing of a minuscule mucosal laceration in left piriform sinus, with application of biological glue and packing of hypopharynx, which was gradually removed from 48 hours postoperative.

Since the last surgery, the child showed a favorable clinical and analytical evolution. A cervical CT was performed six days after the last surgery (Fig. 4) and it revealed remarkable improvement, only identifying a thin retropharyngeal exsudate layer.

Three days later, the child also performed a cervical MRI that identified only thickening of retropharyngeal space, reflecting inflammatory changes.

Bacteriological analysis of the purulent exsudate of the first surgery isolated *Klebsiella pneumoniae* sensitive to the antibiotics instituted. It was isolated from the purulent exsudate from the third and from bronchial secretions *Stenotrophomonas maltophilia* sensitive to co-trimoxazole.

During the time of hospitalization, the patient had several antibiotic schemes: vancomycin and imipenem for fifteen days, followed by piperacillin-tazobactam and clindamycin for fourteen days, and co-trimoxazole for ten days. The child was discharged at forty-third day from hospital in good general condition.

In the follow up ENT visit, the child was asymptomatic with normal physical examination.

## DISCUSSION

Ingestion of FB is a common clinical problem worldwide, despite the differences of cooking and regional eating habits. Children constitute 80% of the patients that seek medical care after ingesting an FB with the peak incidence of occurrence being between 6 months and 3 years of age.<sup>5</sup> This group is particularly prone to ingest/aspirate FB for several reasons, including behavioural and anatomic aspects, such as the tendency to explore their surrounding using the mouths and to talk and to run around while chewing; anatomical characteristics (incomplete dentition); and physiological features including immature swallowing coordination, poor chewing capacity and higher respiratory rates, compared with adults: once an object or food particle is in a child's mouth, it can lodge within the respiratory tract, be ingested in the gastrointestinal tract or end up in the nasopharynx.<sup>15,16</sup>

Nevertheless, serious complications due to FB ingestion, such as oesophageal perforation, deep neck abscess and aorto-oesophageal fistula are rare.

Predisposing factors to major complications are time to seek medical care (> 24 hours since the beginning of the symptoms), sharp FB like fishbone spines, mental diseases, immunosuppressed patients, diabetics and dental prosthesis.<sup>1</sup>

A report from Hong Kong<sup>7</sup> reported a rate of major complications of 0.21%, in a population of 5848 patients and, particularly, deep neck abscess had a rate of 0.09%, which is lower than in the present study (0.12%). In another paper from Taiwan, major complications were found in 22

of 225 patients (9.7%), but any patient developed cervical abscess.<sup>17</sup>

Although deep cervical abscess is a known possible complication due to ingested FB, it constitutes a diagnostic challenge, mostly at paediatric age,<sup>9,11,18</sup> because the symptoms of aspiration or ingestion of FB can simulate different paediatric diseases such as asthma, croup or pneumonia, delaying the correct diagnosis<sup>10</sup> or the development of abscesses in deep neck spaces can occur even in the absence of any clinical evidence of oesophageal perforation.<sup>7</sup> The first twenty-four hours after FB ingestion are crucial for the development of complications<sup>7</sup> but, as in the present two cases, the complications can also develop some days after the episode of FB ingestion. So there must be a high index of suspicion when compatible symptoms co-exist with recent history of FB ingestion/removal, mostly in very young children.<sup>19</sup>

The delayed onset of symptoms is associated with an increased risk of complications: retained oesophageal foreign bodies may cause a multitude of problems, including mucosal ulceration, inflammation or infection.<sup>9,20</sup> Any patient who had ingested a FB and who manifests cervical pain, fever and/or leucocytosis should be assumed to have a serious complication until proven otherwise.<sup>7</sup> In case 2, the persistence of FB impacted for four days was probably associated with a more serious clinical situation, requiring multiple surgical interventions, various antibiotics schemes and a longer time of hospitalization compared to case 1.

The best method for oesophageal FB extraction has been debated over the years. The choice of treatment is influenced by patient's age and clinical condition, size, shape and location of FB.<sup>16</sup> The endoscopy is the most used method: it allows direct visualization of FB and evaluation of oesophageal lesion.<sup>2</sup> Nowadays, flexible and rigid esophagoscopy are considered safe and effective in experienced hands. Flexible endoscopy is usually the first line of treatment, being cost-effective, as it use to be performed in an ambulatory regimen without general anaesthesia.<sup>16</sup> When the FB is sharp or penetrant, or when it is not possible to be removed by flexible endoscopy, then rigid endoscopy is an alternative therapeutic option.<sup>16</sup>

Previous oesophageal manipulation by flexible endoscopy may be considered a risk factor for this sort of complications.<sup>21</sup> Air insufflation, necessary to obtain a good observation, may cause further contamination if an oesophageal perforation is present.<sup>4</sup> Although the risk of perforation with esophagogastroduodenoscopy alone is only 0.03%, this risk can increase to 17% with therapeutic interventions.<sup>21</sup> In case 1, the patient had undergone an upper digestive endoscopy for FB removal three days before the diagnosis of cervical abscess. It is possible the previous oesophageal manipulation was associated with the development of deep neck infection.

The possibility of deep neck abscess must be investigated by imagiology (Cervical CT with contrast or cervical MRI), which is essential for diagnosis (being most FB radio-opaque) and programming of the therapeutic

intervention.<sup>22,23</sup>

CT scan is very effective in the evaluation of the deep structures of the neck and eventually identifying a retained FB,<sup>16</sup> allowing us to analyse the spread of the infection beyond what may be clinically evident. Furthermore, progression of infection from cellulitis to abscess can be traced, thereby optimizing a timely decision on the surgical procedure and planning of a surgical approach.<sup>24</sup> MRI may also be used in diagnosis and follow up of these infections with the advantage of an absence of radiation inflicted, especially on children.<sup>24</sup>

If an abscess is found, surgical intervention must be performed immediately, as well as the institution of intravenous broad-spectrum antibiotics.<sup>23</sup>

The bacteriology pattern of deep neck infections is usually polymicrobial, including aerobes, microaerophilics and anaerobes.<sup>7</sup> The most common organisms seem to be aerobic *Streptococcus viridans*,  $\beta$ -hemolytic streptococci, *Staphylococcus*, *Klebsiella pneumoniae* (especially in diabetics), anaerobic *Bacteroides* and *Peptostreptococcus*.<sup>25</sup> In our study, it was possible to isolate *K. pneumoniae* and *S. maltophilia* in case 2. In case 1 none microbial agent was isolated from purulent exudate. Some reasons are described in the literature as the use of antibiotics before admission and the high dose of intravenous antibiotics before surgical drainage of the abscess,<sup>25</sup> although any of these enumerated conditions was present in our case.

It is mandatory to guarantee the patency of the airway because of the risk of obstruction or aspiration in cervical abscesses.<sup>25</sup> There are even cases that a tracheotomy must be performed to protect airway.<sup>25</sup> In case 2, the child was admitted in the post-operative period in an intensive care unit with endotracheal intubation and mechanical

ventilation and feeding by nasogastric tube.

A rigid esophagoscopy under general anaesthesia should be undergone if there is clinical suspicion and/or imagiological confirmation of retained FB in the oesophagus.<sup>22</sup>

Our study presents some limitations such as the low number of cases (only two) with very different characteristics: case 1 refers to an adult with oesophageal perforation, while case 2 refers to a child, and as described above this population may differ considerably in clinical presentation. Another limitation is the reproducibility of the existent bibliography as the majority of the articles about deep neck infections consider all aetiologies and not only those caused by FB ingestion, and most studies arise from Asian populations with eating and behavioural habits that may influence type and frequency of FB ingestion in comparison with western population like Portuguese.

## CONCLUSION

Cervical abscesses, although a rare complication, should be taken into account in diagnostic hypothesis, given the recent history of foreign body ingestion/removal and the presence of compatible symptoms, due to their potential morbidity and mortality in the absence of an appropriate therapeutic approach.

## CONFLICTS OF INTEREST

The authors declared no conflicts of interest.

## FUNDING SOURCES

The authors declared that this original work was not financed in any way.

## REFERENCES

- Ashraf O. Foreign body in the esophagus: a review. Sao Paulo Med J. 2006;124:346-9.
- Kay M, Wyllie R. Foreign body ingestions in the pediatric population and techniques of endoscopic removal. Tech Gastrointest Endosc. 2012;15:9-17.
- Righini CA, Tea BZ, Reyt E, Chahine KA. Cervical cellulitis and mediastinitis following esophageal perforation: a case report. World J Gastroenterol. 2008;14:1450-2.
- Chee LW, Sethi DS. Diagnostic and therapeutic approach to migrating foreign bodies. Ann Otol Rhinol Laryngol. 1999;108:177-80.
- Chung S, Forte V, Campisi P. A review of pediatric foreign body ingestion and management. Clin Pediatr Emerg Med. 2010;11:225-30.
- Poluri A, Singh B, Sperling N, Har-El G, Lucente FE. Retropharyngeal abscess secondary to penetrating foreign bodies. J Cranio Maxillofac Surg. 2000;28:243-6.
- Lam HC, Woo JK, Van Hasselt CA. Esophageal perforation and neck abscess from ingested foreign bodies: treatment and outcomes. Ear Nose Throat J. 2003;82:789-94.
- Little DC, Shah SR, St Peter SD, Calkins CM, Morrow SE, Murphy JP, et al. Esophageal foreign bodies in the pediatric population: our first 500 cases. J Pediatr Surg. 2006;41:914-8.
- Chinski A, Foltran F, Gregori D, Ballali S, Passali D, Bellussi L. Foreign bodies in the oesophagus: the experience of the Buenos Aires. Int J Pediatr. 2010;pii490691.
- Wang S, Liu J, Chen Y, Yang X, Xie D, Li S. Diagnosis and treatment of nine cases with carotid artery rupture due to hypopharyngeal and cervical esophageal foreign body ingestion. Eur Arch Otorhino Laryngol. 2013;270:1125-30.
- Santander BC, Del Prado AP, Castillo M, Neth O, Santaella IO. Abscesos retrofaringeo y parafaringeo: experiencia en hospital terciario de Sevilla durante la última década. An Pediatr. 2011;75:266-72.
- Marra S, Hotaling AJ. Deep Neck Infections. Am J Otolaryngol. 1996;17:287
- Sakaguchi M, Sato S, Ishiyama T, Katsuno S, Taguchi S. Characterization and management of deep neck infections. In: J Oral Maxillo Fac Surg. 1997;26:131-4.
- Lee JK, Kim HD, Lim SC. Predisposing factors of complicated deep neck infection: an analysis of 158 cases. Yonsei Med J. 2007;48:55-62.
- Sebastian van As AB, Yusuf AM, Millar AJ, Susy Safe Working Group. Food foreign body injuries. Int J Pediatr Otorhinolaryngol. 2012;76:S20-5.
- Rodríguez H, Passali GC, Gregori D, Chinski A, Tiscornia C, Botto H, et al. Management of foreign bodies in the airway and oesophagus. Int J Pediatr Otorhinolaryngol. 2012;76:S84-91.
- Hung CW, Hung SC, Lee CJ, Lee WH, Wu KH. Risk factors for complications after a foreign body is retained in the esophagus. J Emerg Med. 2012;43:423-7.
- Gregori D, Scarinzi C, Morra B, Salerni L, Berchiappa P, Snideros S, et al. Ingested foreign bodies causing complications and requiring hospitalization in European children: Results from the ESFBI study. Pediatr Int. 2010;52:26-32.
- Hon KL, Chu WC, Sung JK. Retropharyngeal abscess in a young child due to ingestion of eel vertebrae. Pediatr Emerg Care. 2010;26:439-41.
- Woolley SL, Smith DR. History of possible foreign body ingestion in children: don't forget the rarities. Eur J Emerg Med. 2005;12:312-6.
- Bhatia NL, Collins JM, Nguyen CC, Jaroszewski DE, Vikram

- HR, Charles JC. Esophageal perforation as a complication of esophagogastroduodenoscopy. *J Hosp Med.* 2008;3:256-62.
22. Chen CY, Peng JP. Esophageal fish bone migration induced thyroid abscess: case report and review of the literature. *Am J Otolaryngol.* 2011;32:253-5.
23. Hedge A, Mohan S, Lim WE. Infections of the deep neck spaces. *Singapore Med J.* 2012;53:305-12.
24. Marques PM, Spratley JE, Leal LM, Cardoso E, Santos M. Parapharyngeal abscess in children: five year retrospective study. *Braz J Otorhinolaryngol.* 2009;75:1826-30.
25. Huang TT, Liu TC, Chen PR, Tseng FY, Yeh TA, Chen YS. Deep neck infection: analysis of 185 cases. *Head Neck.* 2004;26:854-60.

Liliana COSTA, João LARANGEIRO, Carla PINTO MOURA, Margarida SANTOS

## Foreign Body Ingestion: Rare Cause of Cervical Abscess

Acta Med Port 2014;27:743-748

Publicado pela **Acta Médica Portuguesa**, a Revista Científica da Ordem dos Médicos

Av. Almirante Gago Coutinho, 151

1749-084 Lisboa, Portugal.

Tel: +351 218 428 215

E-mail: [submissao@actamedicaportuguesa.com](mailto:submissao@actamedicaportuguesa.com)

[www.actamedicaportuguesa.com](http://www.actamedicaportuguesa.com)

ISSN:0870-399X | e-ISSN: 1646-0758



ACTA MÉDICA  
PORTUGUESA

