


“Apple Jelly” Sign: Diascopy in Cutaneous Sarcoidosis



Sinal “Apple Jelly”: Diascopia na Sarcoidose Cutânea

Diogo MATOS ¹, Ricardo COELHO¹
Acta Med Port 2015 May-Jun;28(3):394-394

Keywords: Diagnosis, Differential; Sarcoidosis; Skin Diseases.

Palavras-chave: Diagnóstico Diferencial; Doenças da Pele; Sarcoidose.

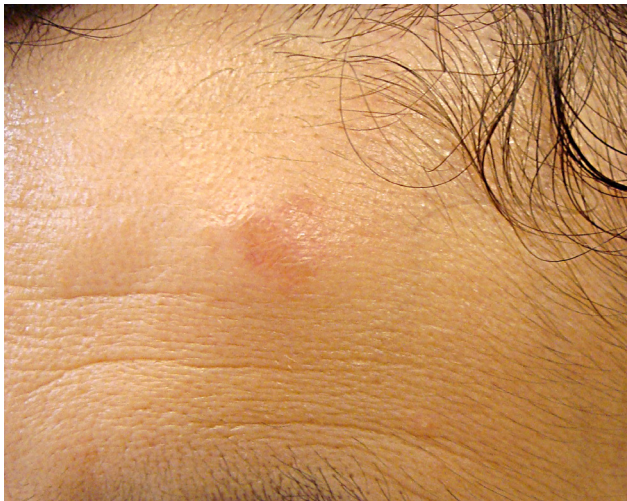

Figure 1 - Erythematous plaque on the forehead

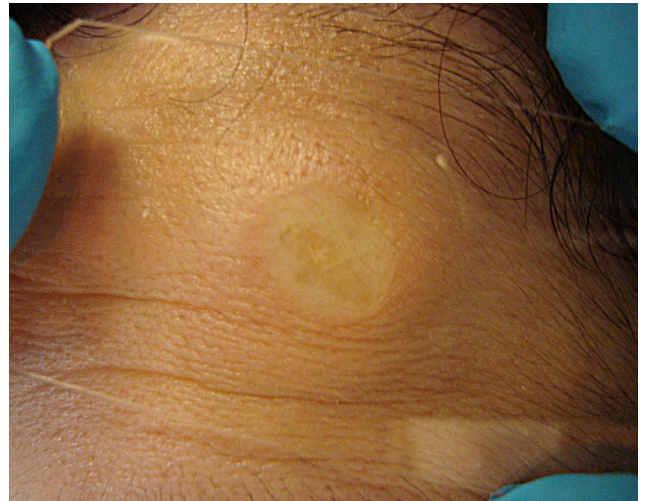


Figure 2 - Diascopy of the forehead plaque mitigating the erythema and revealing yellow-brown nodules on a lighter background

A 43-year-old woman presented with erythematous papules and plaques on the forehead evolving in the previous 3 months (Fig. 1). Diascopy, by showing a yellowish nodule-like aspect (Fig. 2), raised the hypothesis of cutaneous sarcoidosis, which was confirmed by histopathological examination.


Sarcoidosis is a multisystemic granulomatous disease, a histologically evident characteristic shared by its cutaneous lesions. This granulomatous nature can be elicited by diascopy. The pressure from the glass slide application

eliminates the characteristic erythema (Fig. 1), revealing a yellow-brown granulomatous appearance resembling apple-jelly (Fig. 2). Although not specific for cutaneous sarcoidosis, as it can also be seen on other granulomatous conditions such as granuloma annulare, this ‘apple jelly’ sign, classically described in association with sarcoidosis, can be a useful diagnostic tool. It is absent in the majority of sarcoidosis differential diagnosis, such as in lupus tumidus. Apart from its usefulness it also constitutes a curious clinical picture.^{1,2}

REFERENCES

1. Gawkrödger DJ. Sarcoidosis. In: Burns T, Breathnach S, Cox N, Griffiths C, editors. *Rook's Textbook of Dermatology*. 8th ed. Oxford: Wiley-Blackwell; 2010. p. 61.1-23.
2. Marchell RM, Judson MA. Cutaneous sarcoidosis. *Semin Respir Crit Care Med*. 2010;31:442–51.

1. Serviço de Dermatovenereologia. Hospital Garcia de Orta. Almada. Portugal.

 Autor correspondente: Diogo Matos. diogomatos.pt@gmail.com

Recebido: 01 de Abril de 2014 - Aceite: 04 de Agosto de 2014 | Copyright © Ordem dos Médicos 2014

Diogo MATOS, Ricardo COELHO

“Apple Jelly” Sign: Diascopy in Cutaneous Sarcoidosis

Acta Med Port 2015;28:394-394

Publicado pela **Acta Médica Portuguesa**, a Revista Científica da Ordem dos Médicos

Av. Almirante Gago Coutinho, 151
1749-084 Lisboa, Portugal.

Tel: +351 218 428 215

E-mail: submissao@actamedicaportuguesa.com

www.actamedicaportuguesa.com

ISSN:0870-399X | e-ISSN: 1646-0758



ACTA MÉDICA
PORTUGUESA

