

Multiple Liver Abscesses due to *Morganella morganii*



Abcessos Hepáticos Múltiplos devido a *Morganella morganii*

Ana PONTE¹, Cláudia COSTA²
Acta Med Port 2015 Jul-Aug;28(4):539-539

Keywords: Liver Abscess; *Morganella morganii*.

Palavras-chave: Abcessos Hepáticos; *Morganella morganii*.

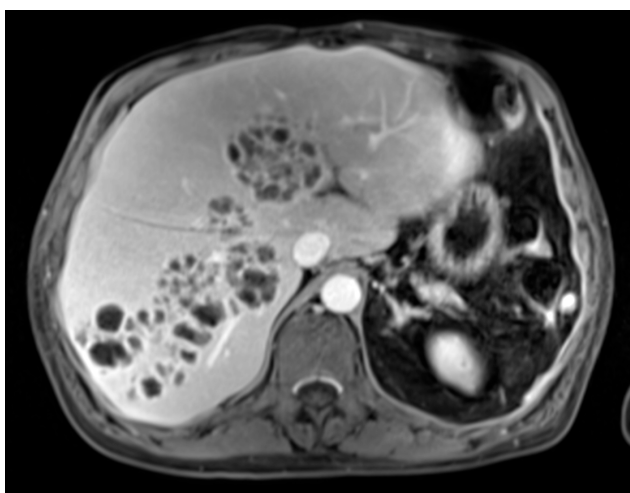


Figure 1 - Transverse section of magnetic resonance imaging

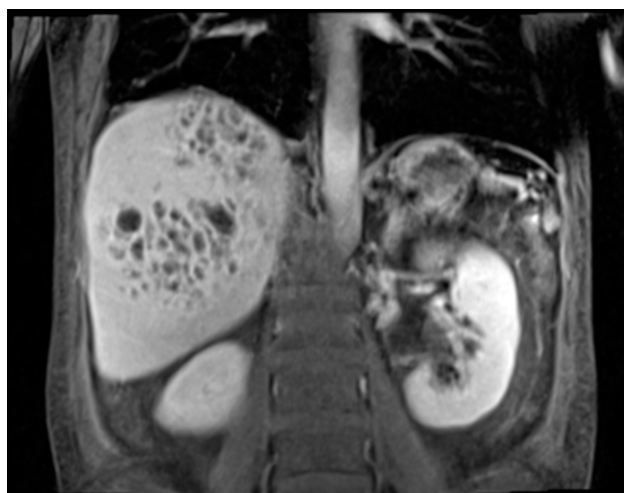

Figure 2 - Coronal section of magnetic resonance imaging

A 45-year-old man with alcoholic liver disease and chronic venous insufficiency presented an insidious history of dorsal pain, anorexia and weight loss. Physical examination revealed fever, jaundice and two skin ulcers in his left leg. Laboratory tests showed leucocytosis of 12 790/mm³, C-reactive protein of 24.9 mg/dL, total and direct bilirubins of 1.88 and 1.21 mg/dL, respectively. Abdominal ultrasound showed multiple hypoechoic liver lesions. Magnetic resonance imaging was further performed and revealed several lesions with wall enhancement in IV to

VIII liver segments, highly suggestive of multiple abscesses (Fig.s 1 and 2). Cultures of ulcer's base and blood all grew *Morganella morganii*. The patient was submitted to eight weeks of intravenous ceftazidime according to antibiogram, with complete resolution of symptoms, laboratory and imaging findings. Liver abscesses may result from haematogenous spread of systemic infection. *Morganella morganii* is a rare cause of liver abscesses and is mainly associated with cutaneous and urinary tract infections.^{1,2}

REFERENCES

1. Hakyemez IN, Sit M, Aktas G, Tas T, Mengeloglu FZ, Kucukbayrak A. A case of giant hepatic hydatid cyst infected with morganella morganii and the literature review. Case Rep Gastrointest Med. 2012;2012:591561.
2. Falagas ME, Kavvadia PK, Mantadakis E, Kofteridis DP, Bliiziotis IA, Saloustros E, et al. *Morganella morganii* infections in a general tertiary hospital. Infection. 2006;34:315–21.

1. Serviço de Gastroenterologia. Centro Hospitalar de Vila Nova de Gaia/Espinho. Vila Nova de Gaia. Portugal.

2. Serviço de Medicina Interna. Centro Hospitalar de Vila Nova de Gaia/Espinho. Vila Nova de Gaia. Portugal.

✉ Autor correspondente: Ana Ponte. ana.ilponte@gmail.com

Recebido: 13 de Junho de 2014 - Aceite: 14 de Julho de 2014 | Copyright © Ordem dos Médicos 2014

Ana PONTE, Cláudia COSTA

Multiple Liver Abscesses due to *Morganella morganii*

Acta Med Port 2015;28:539-539

Publicado pela **Acta Médica Portuguesa**, a Revista Científica da Ordem dos Médicos

Av. Almirante Gago Coutinho, 151
1749-084 Lisboa, Portugal.

Tel: +351 218 428 215

E-mail: submissao@actamedicaportuguesa.com

www.actamedicaportuguesa.com

ISSN:0870-399X | e-ISSN: 1646-0758



ACTA MÉDICA
PORTUGUESA

