

Metastatic Malignant Peripheral Nerve Sheath Tumor

Tumor Maligno da Bainha dos Nervos Periféricos Metastizado



Joaquim SOARES DO BRITO¹, Paulo ALMEIDA¹, José PORTELA¹
Acta Med Port 2016 Apr;29(4):290-290 • <http://dx.doi.org/10.20344/amp.6912>

Keywords: Nerve Sheath Neoplasms/secondary; Sarcoma.

Palavras-chave: Neoplasias da Bainha dos Nervos Periféricos/secundário; Sarcoma.

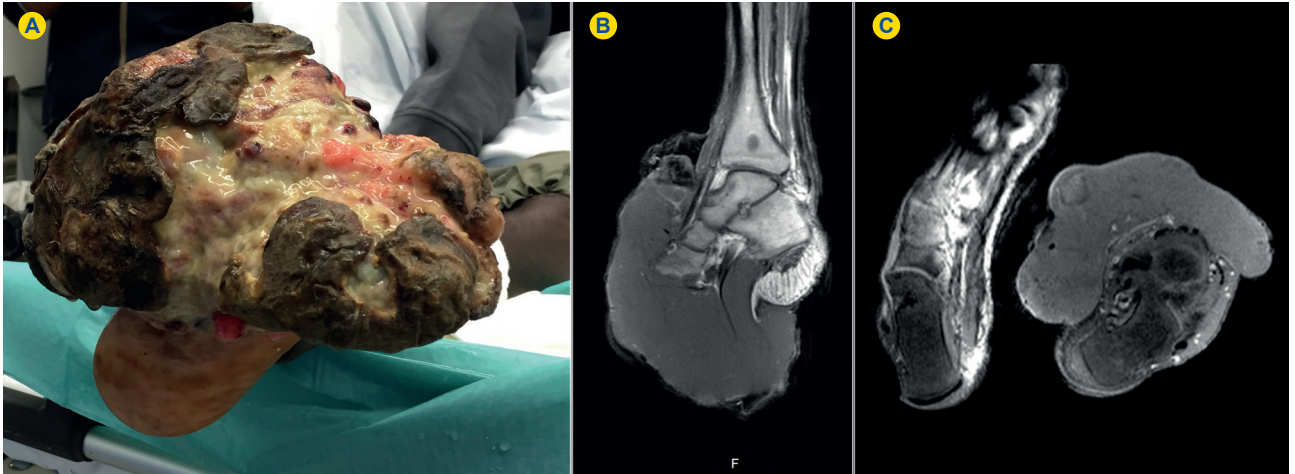


Figure 1 - Ulcerated giant tumoral mass of the left foot (A); Sagittal and coronal MRI studies (B, C).

A 28-year-old black man arrived to our emergency department with a giant ulcerated tumoral mass in the left foot (Fig. 1). The patient had also several tumoral lesions affecting the lower limbs, upper limbs and head. The x-ray, CT-scan and MRI (Fig. 2) showed a large aggressive tumoral mass involving the foot with metastasis in other localizations, including the head and thorax. Due to the impossibility of limb salvage surgery, the patient suffered a leg amputation. The pathology of the surgical excised tumor revealed a malignant peripheral nerve sheath

tumor (MPNST). After surgery the patient was transferred to another department to start chemotherapy, which is still ongoing. MPNST are sarcomas, which originate from peripheral nerves or associated cells with potential to metastasize.¹⁻³ Because of the multiple cell origin, histologic diagnosis and classification is often difficult.¹⁻³ Up to 50% of MPNST occur in patients with Neurofibromatosis type 1 and usually presents as an enlarging palpable mass.^{3,4} Nevertheless, this exuberant clinical presentation is unusual.

REFERENCES

1. Farid M, Demicco EG, Garcia R, Ahn L, Merola PR, Cioffi A, et al. Malignant peripheral nerve sheath tumors. *Oncologist*. 2014;19:193-201.
2. Anghileri M, Miceli R, Fiore M, Mariani L, Ferrari A, Mussi C, et al. Malignant peripheral nerve sheath tumors. *Cancer*. 2006;107:1065-74.
3. Geller D, Gebbhardt M. Malignant peripheral nerve sheath tumors (MPNSTs). *Electronic Sarcoma Update Newsletter*. 2006;3:3.
4. Evans DG, Baser ME, McGaughran J, Sharif S, Howard E, Moran A. Malignant peripheral nerve sheath tumours in neurofibromatosis 1. *J Med Genet*. 2002;39:311-4.

1. Serviço de Ortopedia e Traumatologia. Hospital de Santa Maria. Centro Hospitalar Lisboa Norte. Lisboa. Portugal.

✉ Autor correspondente: Joaquim Soares do Brito. joaquimsoaresdobrito@gmail.com

Recebido: 13 de agosto de 2015 - Aceite: 11 de novembro de 2015 | Copyright © Ordem dos Médicos 2016

