

# Hepatic Angiosarcoma Masquerading as Hemangioma: A Challenging Differential Diagnosis

## Angiosarcoma Hepático e Hemangioma: Um Diagnóstico Diferencial Desafiante



Ana Rita GARCIA✉<sup>1</sup>, João RIBEIRO<sup>1</sup>, Helena GERVÁSIO<sup>1</sup>, Francisco Castro e SOUSA<sup>2,3</sup>  
Acta Med Port 2017 Oct;30(10):750-753 • <https://doi.org/10.20344/amp.8593>

### ABSTRACT

Hemangiomas are usually diagnosed based on ultrasound findings. The presence of symptoms, rapid growth or atypical imagiological findings should make us consider other diagnoses, including malignant tumors such as angiosarcomas. We describe the case of a previously healthy 46-year-old female without a history of exposure to carcinogens who presented with abdominal pain for two months. Diagnostic work-up revealed elevated gamma-glutamyl transferase and lactate dehydrogenase levels. Abdominal ultrasound described a large nodular lesion in the right lobe of the liver described as a hemangioma. One month later, a computed tomography-scan was made and revealed the same lesion, which had grown from 13.5 to 20 cm, maintaining typical imaging characteristics of a hemangioma. A right hepatectomy was performed and pathology revealed an angiosarcoma. After surgery, a positron emission tomography-computed tomography scan showed hepatic and bone metastasis. The patient started taxane-based chemotherapy and lumbar palliative radiotherapy, but died 10 months after surgery. This case shows how difficult it is to diagnose hepatic angiosarcoma relying only on imaging findings. Two abdominal computed tomography -scans were performed and none suggested this diagnosis. Angiosarcoma is a very aggressive tumour with an adverse prognosis. Surgery is the only curative treatment available. However, it is rarely feasible due to unresectable disease or distant metastasis.

**Keywords:** Hemangioma, Cavernous/diagnosis; Hemangiosarcoma/diagnosis; Liver Neoplasms/diagnosis

### RESUMO

Apesar do diagnóstico de hemangioma ser habitualmente simples e baseado na ecografia, a presença de sintomas, o crescimento rápido ou a presença de atipias imagiológicas devem-nos fazer considerar a hipótese de outras entidades, algumas delas malignas como o angiossarcoma. É descrito o caso de doente do sexo feminino de 46 anos, previamente saudável sem exposição a carcinogénicos, refere queixas de dor abdominal durante dois meses. O estudo analítico revelou elevação da gama glutamyl transferase e lactato desidrogenase e a ecografia abdominal evidenciou uma lesão nodular de grandes dimensões no lobo direito do fígado, descrita como hemangioma. Um mês mais tarde, realizou uma tomografia computadorizada abdominal que revelou aumento das dimensões da lesão (13,5 para 20 cm), mantendo características imagiológicas de hemangioma. A doente foi submetida a hepatectomia direita e a histologia revelou a presença de angiossarcoma. Após cirurgia, uma tomografia por emissão de positrões-tomografia computadorizada evidenciou metastização hepática e óssea. A doente foi submetida a radioterapia e quimioterapia paliativa com paclitaxel, tendo falecido 10 meses após a cirurgia. Este caso exemplifica a dificuldade do diagnóstico do angiossarcoma baseado apenas nos exames de imagem. Foram realizadas duas tomografias computadorizadas abdominais e nenhuma sugeriu o diagnóstico. Os angiossarcomas são tumores muito agressivos com prognóstico reservado, sendo a cirurgia o único tratamento curativo. No entanto, raramente é realizada devido a doença irresssecável ou disseminação à distância.

**Palavras-chave:** Hemangioma Cavernoso/diagnóstico; Hemangiossarcoma/diagnóstico; Neoplasias Hepáticas/diagnóstico

### INTRODUCTION

Hepatic angiosarcomas represent 2% of primary hepatic tumours,<sup>1,4</sup> are more frequent in male patients between the ages of 50 and 70 and risk factors may include chemical carcinogens (thorium dioxide, vinyl chloride and arsenic).<sup>1,2</sup> Nevertheless, it is the most common malignant mesenchymal tumour of the liver, and is more frequent than fibrosarcoma, malignant fibrohistiocyoma and leiomyosarcoma.<sup>5</sup> Clinical manifestations are nonspecific, with abdominal pain, fatigue and weight loss occurring more frequently. Due to low incidence and insidious course, diagnosis is often delayed. Radiological findings may include hepatic lesions similar to cavernous hemangiomas, atypical hepatocellular cancer, hypervascular metastases and hepatic epithelioid hemangioendothelioma, leading to a challenging differential diagnosis.<sup>3,6</sup> Hepatic angiosarcomas

exhibit rapid progression and poor prognosis (median overall survival of six months without treatment and 12 months with treatment).<sup>2,3,7</sup> Surgery is the treatment of choice for non-metastatic disease if there is adequate hepatic reserve and limited to one lobe. It cannot be performed in metastatic disease.<sup>1,3</sup>

### CASE PRESENTATION

A healthy 46-year-old female presented with a severe right upper quadrant pain for over two months, without fatigue, weight loss, jaundice or abdominal distension. There was no medication history of oral contraceptive pills, anabolic steroids, as well as no alcohol or tobacco consumption. She was not exposed to any known carcinogens.

Physical examination revealed an ECOG-Performance

1. Serviço de Oncologia Médica. Instituto Português de Oncologia de Coimbra. Coimbra. Portugal.

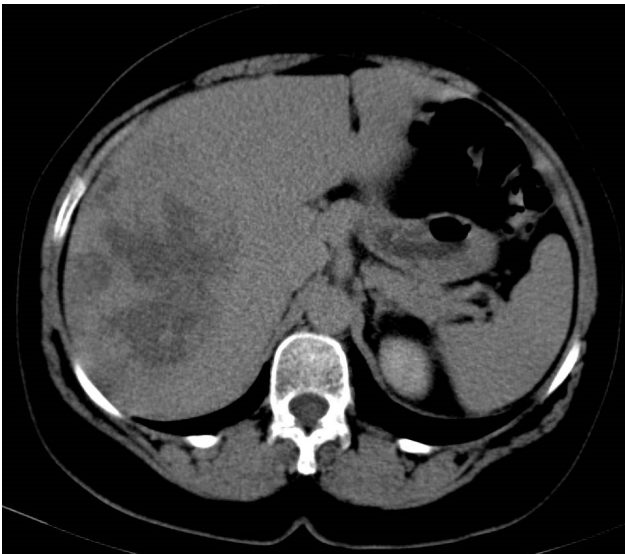
2. Serviço de Cirurgia A. Centro Hospitalar e Universitário de Coimbra. Coimbra. Portugal.

3. Departamento de Cirurgia. Faculdade de Medicina. Universidade de Coimbra. Coimbra. Portugal.

✉ Autor correspondente: Ana Rita Garcia. [aritamgarcia@hotmail.com](mailto:aritamgarcia@hotmail.com)

Recebido: 23 de dezembro de 2016 - Aceite: 03 de maio de 2017 | Copyright © Ordem dos Médicos 2017





**Figure 1** – Abdominal CT scan (before contrast administration) - heterogeneous hepatic mass in the right lobe of the liver, with areas of higher density interspersed with hypodense areas

Status of 0, pain rated at 5 (0 - 10, verbal analog pain scale), normal cardiopulmonary exam and upper right quadrant and epigastric tenderness, without irradiation or antalgic position, and partial relief with nonsteroidal anti-inflammatory drugs. There were no palpable masses or signs of portal hypertension.

Blood tests revealed a normal blood count and clotting tests. Bilirubin, transaminases and alkaline phosphatase levels were normal. Gamma-glutamyl transferase (GGT) and lactate dehydrogenase (LDH) levels were elevated (5 x upper limit of normal (ULN) and 4xULN, respectively). Tumour markers were normal (carcinoembryonic antigen (CEA), carbohydrate antigen (CA) 19-9 and alpha-fetoprotein). Human immunodeficiency virus (HIV), hepatitis B and C virus were negative.

An ultrasound revealed a heterogeneous, bulky and

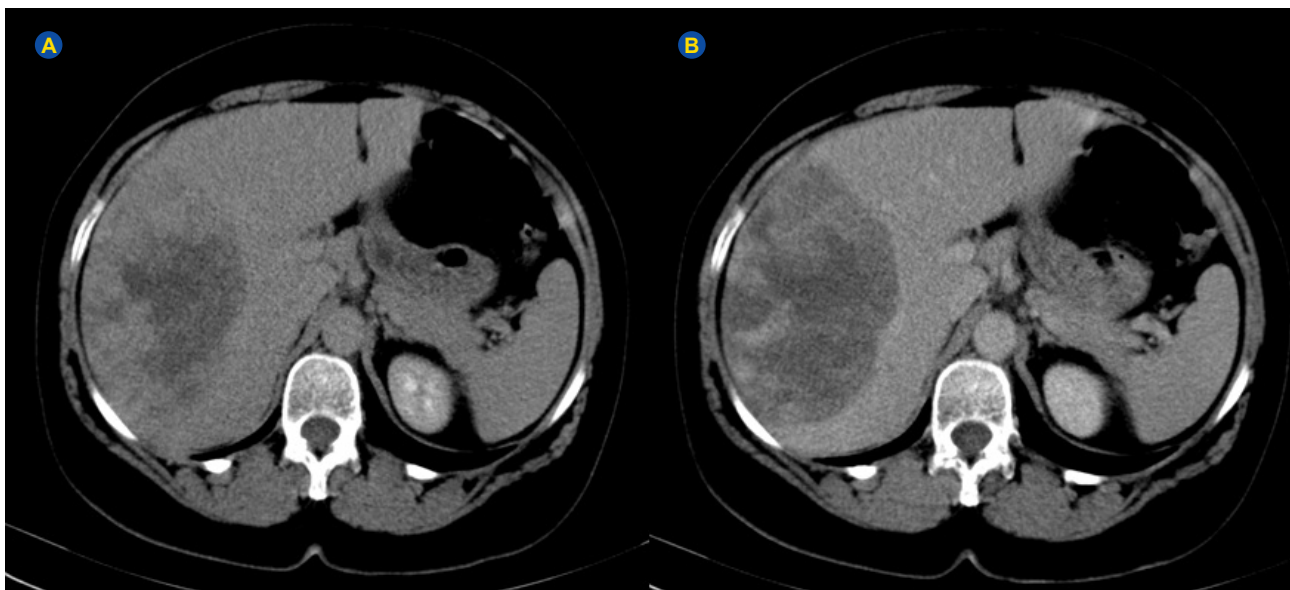
hyperechoic mass, 13.5 cm wide, in the right lobe of the liver, described as a hemangioma, with no signs of steatosis or chronic liver disease. An abdominal triphasic computed tomography (CT) scan with contrast injection was performed to further assess this lesion, with arterial, portal and late phases (Figs 1, 2).

One month later, due to worsening abdominal pain, another CT-scan was performed and the same nodular lesion was identified, 20 cm, and considered a hepatic hemangioma (Fig. 3). Due to this significant growth and the patient's abdominal pain, a right hepatectomy was performed. The surgical specimen showed a hepatic angiosarcoma with free surgical margins, consisting of hepatic pleomorphic cells, with more than 20 atypical mitosis, positivity to CD31 and CD34 and negativity to HMB 45 and pancytokeratins AE1/AE3.

A positron emission tomography (PET)-CT performed two months after surgery described three hepatic metastatic lesions and lytic lesion in the first thoracic vertebrae. Palliative radiotherapy was started (20 Gy / 5 fr / 1 week, from C6 to T3). After radiotherapy, the patient started palliative chemotherapy with paclitaxel 175 mg/m<sup>2</sup> every three weeks (seven cycles), with stable disease on CT-scan. Toxicities included grade 2 alopecia and anaemia, grade 1 neutropenia and grade 1 neuropathy. Two months later, following complaints of lower back pain, a lumbar CT-scan revealed a pathological fracture in the first lumbar vertebrae. Bisphosphonates, calcium and vitamin D, opioid analgesic medication and antalgic radiotherapy (20 Gy / 5 fr / 1 week, from T11 to L4) were started. Unfortunately, the patient died after 10 months initial diagnosis.

## DISCUSSION

Liver angiosarcoma is a rare form of hepatic cancer, especially in a young female patient such as ours. There are no pathognomonic signs or symptoms, but it is important to be suspicious of hepatic angiosarcoma if a patient has



**Figure 2** – CT scan with progressive centripetal enhancement during portal phase (A) and late phase (B)

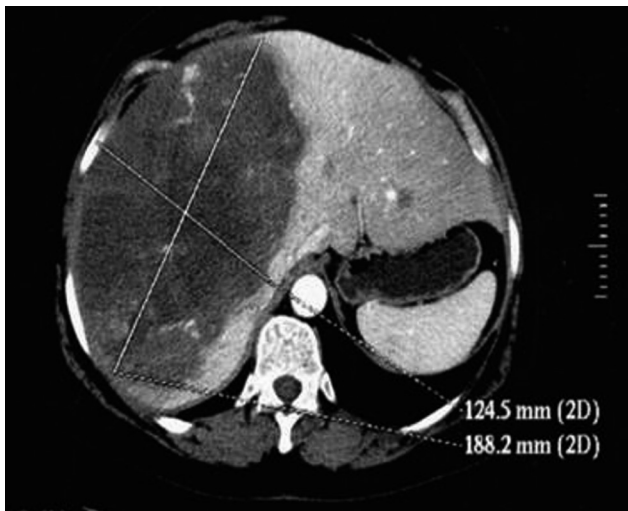


Figure 3 – CT scan with early arterial enhancement

rapidly worsening symptoms, even with normal liver function test and normal tumor markers.<sup>7</sup>

The ultrasound revealed a hyperechoic mass in the liver and a presumptive diagnosis of hemangioma was made. Most hemangiomas are diagnosed by ultrasound if they are small (< 3 cm) and occur in a healthy liver, according to recent EASL guidelines on benign liver tumors.<sup>8</sup> Our patient had no history of chronic liver disease, but the significant size of the lesion led a CT-scan being performed. This exam described this lesion again as a hemangioma. With multiphase CT-scan imaging, misdiagnosis of hemangioma and angiosarcoma is not as common as before the introduction of this technique. Unfortunately, this was not the case with our patient. Worsening symptoms and rapid growth of the lesion led to a right hepatectomy.

It can be speculated whether a magnetic resonance imaging (MRI) could have been useful. If angiosarcoma was suspected in an MRI, the patient could have been diagnosed with metastatic disease (or not), knowing now that they were there two months later, and she would have not been subjected to surgery.

Our case is an example of the pitfalls of the differential diagnosis of focal hepatic lesions. Despite advances in CT technology, distinction between cavernous hemangioma and hepatic angiosarcoma is sometimes difficult when based only in imaging findings. Hepatic hemangiomas can present as large solitary masses with heterogeneous appearance, intratumoral haemorrhage and areas of necrosis, which can be confused with malignant tumours.

## REFERENCES

- Hur CJ, Min BR, Lee YJ, Jang BK, Hwang JS, Kim ES, et al. Clinical courses of primary hepatic angiosarcoma: retrospective analysis of eight cases. *Korean J Gastroenterol.* 2015;65:229-35.
- Zheng YW, Zhang XW, Zhang JL, Hui ZZ, Du WJ, Li RM, et al. Primary hepatic angiosarcoma and potential treatment options. *J Gastroenterol Hepatol.* 2014;29:906–11.
- Okano A, Sonoyama H, Masano Y, Taniguchi T, Ohana M, Kusumi F, et al. The natural history of a hepatic angiosarcoma that was difficult to differentiate from cavernous hemangioma. *Intern Med.* 2012;51:2899-904.
- Chin-Ying C, Cheng-cheng H, Chun-nan Y, Huang-yang C, Jui-Teng W, Chan-Siu C, et al. Liver angiosarcoma, a rare liver malignancy, presented with intra-abdominal bleeding due to rupture - a case report. *World J Surg Oncol.* 2012;10:23
- Buetow PC, Buck JL, Ros PR. Malignant vascular tumors of the liver: radiologic-pathologic correlation. *Radiographics.* 1994;14:153-66.
- Shalini T, Archana R, Arvind A, Sarin S. Angiosarcoma of the liver: imaging of a rare salient entity. *J Radiol Case Rep.* 2014;8:24-32.

Typically, they demonstrate early arterial enhancement followed by progressive wash in of contrast, without wash out – a distinctive feature when compared to hepatocellular carcinoma.<sup>6,9</sup>

The diagnosis can be difficult even with biopsy. Misdiagnosis by fine-needle aspiration biopsy may occur due to the heterogeneity of malignant vascular tumours and the presence of necrotic zones, leading to high rate of inconclusive histological/cytological results. According to some authors, this should not be used due to the risk of bleeding and biopsy-induced metastases.<sup>2,10,11</sup> Open liver biopsies or laparoscopy may be more accurate and safe.<sup>2</sup> However, in case series, percutaneous biopsy was described as a safe procedure.<sup>9</sup> Therefore, the role of histological sampling for angiosarcoma is still controversial.

Because surgery is rarely possible, systemic treatment can be an alternative. However, there are currently no recommended chemotherapy regimens.<sup>1,2,7</sup> We chose taxanes because they are widely used and highly efficacious in vascular-derived tumours. Different schemes may be used and a progression-free survival (PFS) of 7.6 months was obtained recently.<sup>12</sup> Our patient was treated with seven cycles of paclitaxel with tolerable toxicity and stable disease on CT-scan, despite worsening of clinical condition.

Angiosarcoma is radioresistant and radiotherapy is not recommended, except for symptom control.<sup>1,4,13</sup> Liver transplantation is not recommended due to high recurrence rate and poor results.<sup>2,4,13</sup>

## PROTECTION OF HUMANS AND ANIMALS

The authors declare that the procedures were followed according to the regulations established by the Clinical Research and Ethics Committee and to the Helsinki Declaration of the World Medical Association.

## DATA CONFIDENTIALITY

The authors declare having followed the protocols in use at their working center regarding patients' data publication. Informed consent was duly obtained from the patient.

## CONFLICTS OF INTEREST

All authors report no conflict of interest.

## FUNDING SOURCES

This research received no specific grant from any funding agency in the public, commercial, or not-for-profit sectors.

7. Kim HR, Rha SY, Cheon SH, Roh JK, Park YN, Yoo NC. Clinical features and treatment outcomes of advanced stage primary hepatic angiosarcoma. *Ann Oncol.* 2009;20:780-7.
8. European Association for the Study of the Liver (EASL). EASL Clinical Practice Guidelines on the management of benign liver tumours. *J Hepatol.* 2016;65:386-98.
9. Koyama T, Fletcher JG, Johnson CD, Kuo MS, Notohara K, Burgart LJ. Primary hepatic angiosarcoma: findings at CT and MR imaging. *Radiology.* 2002;222:667-73.
10. Shigeaki H, Joji K, Takehiro H, Kurooka H, Oe A, Kotani J, et al. A case of cavernous hemangioma in which malignancy was preoperatively excluded by FDG-PET. *Ann Nucl Med.* 2008;22:327-30.
11. Peterson MS, Baron RL, Rankin SC. Hepatic angiosarcoma: findings on multiphasic contrast-enhanced helical CT do not mimic hepatic hemangioma. *AJR Am J Roentgenol.* 2000;175:165-70.
12. Penel N, Italiano A, Ray-Coquard I, Chaigneau L, Delcambre C, Robin YM, et al. Metastatic angiosarcomas: doxorubicin-based regimens, weekly paclitaxel and metastasectomy significantly improve the outcome. *Ann Oncol.* 2012;23:517-23.
13. Zhou YM, Li B, Yin ZF, Xu F, Wang B, Xu W, et al. Results of hepatic resection for primary hepatic angiosarcoma in adults. *Med Sci Monit.* 2010;16:61-6.

## Methemoglobinemia After Paracetamol Ingestion: A Case Report

## Metemoglobinemia Após Ingestão de Paracetamol: Um Caso Clínico



Catarina QUEIRÓS\*<sup>1</sup>, Pedro SALVADOR\*<sup>2</sup>, Ana VENTURA<sup>3</sup>, Daniela LOPES<sup>3</sup>  
 Acta Med Port 2017 Oct;30(10):753-756 • <https://doi.org/10.20344/amp.8772>

### ABSTRACT

Methemoglobinemia is a potentially fatal condition, mainly acquired after intoxication by certain drugs. To this date, only three cases associated with paracetamol have been reported. This case report describes a patient with autosomal dominant polycystic kidney disease undergoing hemodialysis who was self-medicated with acetaminophen for seven days (at a daily dose of 3 g); the patient went to the hospital after noticing the appearance of a diffuse brownish skin tone, without other symptoms. Arterial blood analysis revealed an increase in methemoglobin levels, with biochemistry showing an increase in total bilirubin and alanine aminotransferase. Paracetamol was discontinued and on reassessment nine days after the onset of symptoms the patient had a clear improvement in her skin color, with normalization of methemoglobin levels.

**Keywords:** Acetaminophen/adverse effects; Methemoglobinemia

### RESUMO

A metemoglobinemia é uma condição potencialmente fatal, maioritariamente adquirida após intoxicação por determinados fármacos; até à data estão relatados apenas três casos associados à toma de paracetamol. Este caso clínico descreve uma doente com doença renal poliquística autossómica dominante, sob hemodiálise, que se automedicou com paracetamol durante sete dias (numa dose diária de 3 g); a doente recorreu ao hospital após ter notado o aparecimento de uma tonalidade cutânea difusamente acastanhada, sem outros sintomas. A análise de sangue arterial revelou aumento da metemoglobina, tendo a bioquímica apresentado um aumento da bilirrubina total e da aminotransferase da alanina. A toma de paracetamol foi suspensa, e na reavaliação nove dias após o início dos sintomas a doente apresentava uma clara melhoria da cor da pele, com normalização dos valores de metemoglobina.

**Palavras-chave:** Acetaminofeno/efeitos adversos; Metemoglobinemia

### INTRODUCTION

Methemoglobin refers to hemoglobin with its iron in the oxidized state, which means it cannot reversibly bind oxygen. The normal range of methemoglobin is 0% - 1% of the total hemoglobin level<sup>1</sup> with any increase above this value being called methemoglobinemia.

The vast majority of methemoglobinemias are acquired,<sup>2</sup> usually resulting from excessive doses of drugs or other substances. Among these, the most frequently associated are dapsone, local anesthetics, sulfonamides, nitrites and aniline or its derivatives.

Paracetamol is currently the only aniline-derivate analgesic still marketed in Portugal. The most common consequences of paracetamol intoxication are well described including: gastrointestinal symptoms and

hepatotoxicity; acute kidney injury; acute myocardial necrosis; pericarditis and hypoglycemia.<sup>3</sup> Here we report a case of methemoglobinemia resulting from paracetamol ingestion, a rare but potentially serious complication of this drug.

### CLINICAL CASE

Our patient was a 78-year-old woman with a history of autosomal dominant polycystic kidney disease on hemodialysis for 30 months as well as a mild cognitive impairment due to vascular dementia. She was chronically medicated with acetylsalicylic acid, calcium acetate/magnesium carbonate, quetiapine and hydroxyzine.

Our patient came to the hospital due to the appearance

\* Co-primeiros autores.

1. Serviço de Dermatologia. Hospital de Santa Maria. Centro Hospitalar Lisboa Norte. Lisboa, Portugal.

2. Serviço de Medicina Interna. Centro Hospitalar de Vila Nova de Gaia-Espinho. Vila Nova de Gaia, Portugal.

3. Serviço de Nefrologia. Centro Hospitalar de Vila Nova de Gaia-Espinho. Vila Nova de Gaia, Portugal.

✉ Autor correspondente: Catarina Queirós. [catarina.squeiros@gmail.com](mailto:catarina.squeiros@gmail.com)

Recebido: 22 de janeiro de 2017 - Aceite: 27 de março de 2017 | Copyright © Ordem dos Médicos 2017

