

Negative β hCG and Molar Pregnancy: The Hook Effect

β hCG Negativa e Gravidez Molar: A Propósito do Efeito Hook



Isabel LOBO ANTUNES¹, Joana CURADO¹, Ana QUINTAS¹, Alcides PEREIRA¹
Acta Med Port 2017 Sep;30(9):656-658 • <https://doi.org/10.20344/amp.8603>

ABSTRACT

Molar pregnancy, included in gestational trophoblastic disease, is a benign pathology with ability to metastasize, usually occurring with excessively high β hCG levels. Clinical scenario is usually a woman in extremes of reproductive age presenting with amenorrhoea, pain and vaginal blood loss; signs derived from high β hCG levels may be present (hyperthyroidism, hyperemesis). Diagnosis is based on a positive pregnancy test – usually a qualitative urinary test. The limitation of this test results from its inability to become positive in presence of markedly high levels of β hCG, saturating the antigens used – known as the ‘hook effect’. With the widespread use of gynaecological ultrasound cases of molar pregnancy have been diagnosed in timely fashion. We describe a case referred as a degenerating fibroid, with a negative urinary pregnancy test. Transvaginal ultrasound was highly suggestive of molar pregnancy, which was confirmed with a quantitative β hCG test, allowing for timely treatment. The importance of a high index of suspicion for this pathology is tremendous to avoid the devastating consequences of a delayed diagnosis.

Keywords: Chorionic Gonadotropin, beta Subunit, Human; Hydatidiform mole

RESUMO

A gravidez molar, incluída na doença gestacional do trofoblasto, é uma patologia benigna com capacidade de metastização, cursando com níveis excessivamente elevados de β hCG. O quadro clínico traduz-se por amenorreia, dor e perda de sangue vaginal numa mulher frequentemente no extremo da idade reprodutiva, podendo estar presentes sinais decorrentes dos níveis de β hCG (hipertiroidismo, hiperemese). O diagnóstico é histológico, e suspeitado por um teste de gravidez positivo, sendo normalmente realizado um teste urinário qualitativo. A limitação deste advém da incapacidade de se tornar positivo na presença de níveis exageradamente altos de β hCG, que satura os antígenos utilizados – ‘efeito hook’. Com a ecografia ginecológica os casos de gravidez molar têm sido diagnosticados mais atempadamente. Descrevemos um caso referenciado como um mioma degenerescente, com teste de gravidez urinário negativo. A ecografia transvaginal realizada foi altamente sugestiva de gravidez molar, confirmada com um teste quantitativo de β hCG e permitindo tratamento atempado. A importância de um elevado índice de suspeição para esta patologia é fulcral para evitar as consequências devastadoras de um diagnóstico tardio.

Palavras-chave: Gonadotropina Coriônica Humana Subunidade beta; Mola Hidatiforme

INTRODUCTION

Hydatidiform mole, or molar pregnancy, is included in the spectrum of gestational trophoblastic disease. Because of their ability to persist, locally invade the uterus and metastasize, molar pregnancies (which can be complete or partial) are regarded as premalignant and warrant a high index of suspicion, despite being uncommon. They usually present with vaginal bleeding and a large-for-dates uterus, as well as features derived from the characteristically extremely high levels of β hCG produced by the trophoblastic tissue, such as hyperemesis, hyperthyroidism and theca lutein ovarian cysts.^{1,2}

Evaluation of a patient with a suspected molar pregnancy includes a complete physical and pelvic examination, as well as a complete blood count, blood chemistry (with renal, hepatic and thyroid function tests), chest X-ray (to evaluate for metastatic disease), pelvic ultrasound and a β hCG pregnancy assay – an essential test for diagnosis. Unfortunately, urinary qualitative β hCG assays (which are sandwich chromatographic immunoassays) may yield false-negative results when there is an exceedingly high level of antigen – a phenomenon termed the ‘high-dose hook effect’.³

We describe the case of a 40-year-old woman presenting to the emergency department with vomiting, bloating and abdominal discomfort, who had a negative urinary β hCG and was initially diagnosed with a degenerating fibroid but was subsequently found to have a molar pregnancy.

CASE REPORT

A 40-year-old woman, *grávida 2 para 1*, with a history of a spontaneous vaginal delivery 20 years prior, presented to the Emergency Department with a 20-day history of post-prandial vomiting, abdominal bloating and discomfort on the right inferior quadrant. On further questioning she admitted vaginal bleeding for the previous four days but denied fever, diarrhoea or urinary symptoms. She was sexually active with oral contraceptive use and regular menstruating periods, the previous one having been 10 days prior to admission. Past medical history included diabetes mellitus type 2 for which she took metformin, and pulmonary Langerhans cell histiocytosis. On examination she was pale with a heart rate of 102 ppm and a blood pressure of 104/75 mmHg. Her abdomen was tender in the lower quadrants, but with no guarding or rebound. At this point a pelvic examination was

1. Gynaecology and Obstetrics Department. Hospital Garcia de Orta. Almada. Portugal.

✉ Autor correspondente: Isabel Lobo Antunes. iloboantunes@gmail.com

Recebido: 26 de dezembro de 2016 - Aceite: 09 de junho de 2017 | Copyright © Ordem dos Médicos 2017



not performed. Her haemoglobin was 10.7 g/dL, with no increased white count, and normal renal and hepatic tests. Urinary β hCG was negative. The abdominal ultrasound revealed “marked heterogeneity of the myometrium with solid and cystic degenerative changes forming a nodular mass with 83 x 84 x 70 mm” and was at this point referred to the Obstetrics and Gynaecology emergency unit, assuming fibroid degeneration as the cause of her pain. Pelvic examination revealed a boggy cervix with a closed external os and slight vaginal bleeding, and an enlarged 12-week uterus that was soft and tender. Transvaginal ultrasound revealed an enlarged uterus with the endometrial cavity completely filled with a complex echogenic cystic mass with 94.8 mm x 68.5 mm consistent with a hydatidiform mole (Fig. 1). Ovaries were normal. Because of the ultrasonographic suspicion of a molar pregnancy, a serum β hCG was requested which was 561 378 IU/L. Chest X-ray showed no evidence of metastatic spread.

The patient underwent uterine evacuation under general anaesthesia the following day, with histological examination revealing “first trimester irregular large villosities, with oedema and cistern formation. There is trophoblastic proliferation with focal atypia. These findings are consistent with complete hydatidiform mole”.

She was discharged the next day, referred to outpatient follow-up with serial serum β hCG measurements.

DISCUSSION

The hydatidiform mole, or molar pregnancy, is a form of gestational trophoblastic disease – a non-malignant tumour with an ability to metastasize, that arises from abnormal development of the trophoblast early in gestation after an embryo fails to develop,² producing excessively high levels of β hCG. It has an incidence of approximately 1 in 1000 pregnancies,¹ and is more common in women in the extremes of reproductive age.

Clinical decision-making concerning women of childbearing age presenting with amenorrhoea, abdominal pain and vaginal bleeding is often dictated by pregnancy testing, specifically urinary qualitative hCG assays.⁴ These assays use antibodies directed against β hCG, allowing for immunological identification. The majority of them are chromatographic sandwich immunoassays in which two antibodies directed against part of the beta chain are used and the resultant ‘sandwich’ they form around the antigen is detected and interpreted as positive.⁵ If the β hCG levels are markedly elevated the antibodies saturate and the signal response decreases, overwhelming the assay and blocking the formation of ‘sandwiches’ between the two antibodies, yielding a false-negative result – this is known as the ‘high-dose hook effect’.^{5,6} The implication of this is tremendous as it may delay diagnosis of a potentially life-threatening pathology. The advent of transvaginal ultrasound has reduced the room for error, presenting a positive predictive

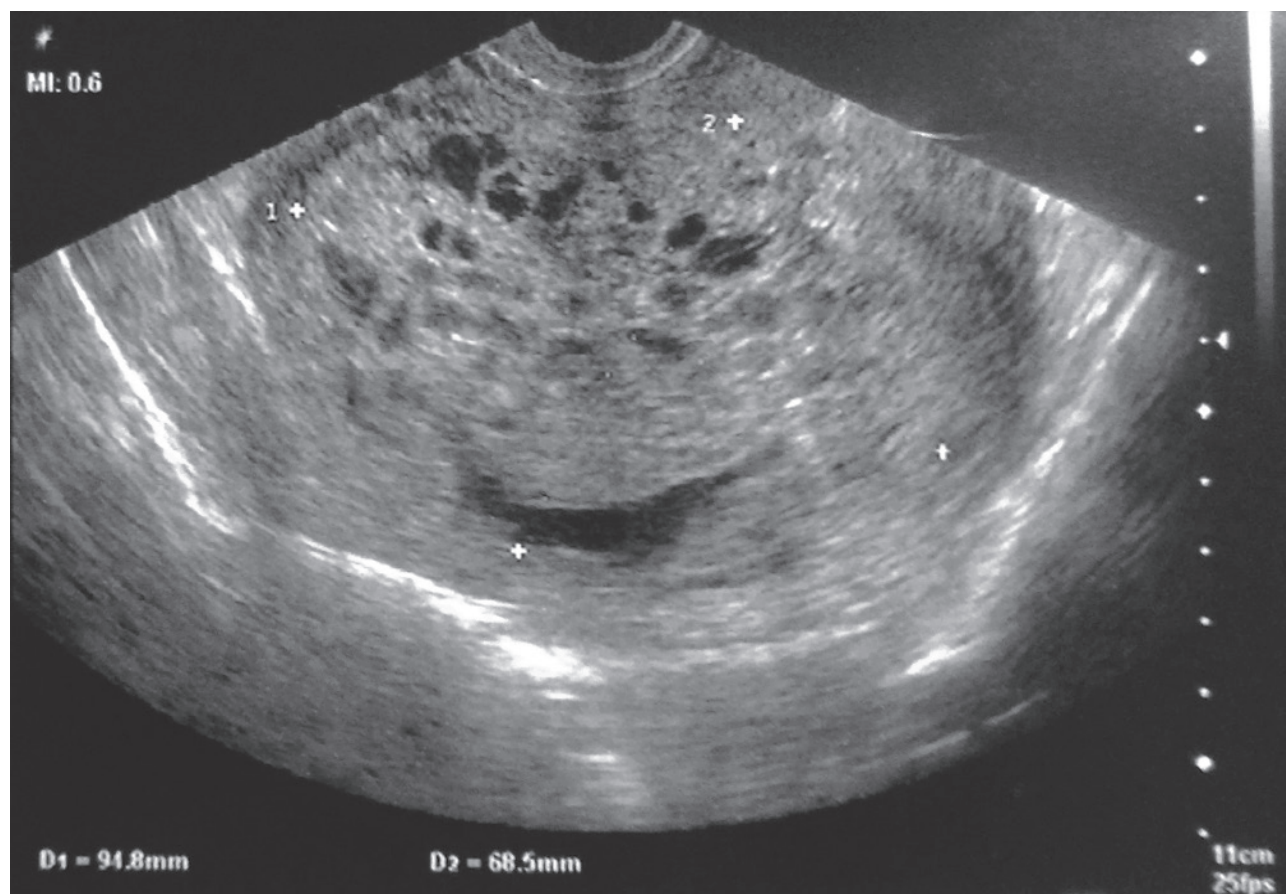


Figure 1 – Ultrasonography revealing the typical bunch of grapes sign

value for molar pregnancy of 100%.⁷ Nonetheless, this procedure is often delayed or not considered when an alternative diagnosis is contemplated.

In our case, the patient was referred from the Emergency Department to the Obstetrics and Gynaecology Emergency Unit due to pain originating in what was considered to be, by abdominal ultrasound, a degenerating fibroid. Clinical suspicion was high due to history and physical findings, and despite a negative urinary β hCG test a readily available transvaginal ultrasound was performed which strongly suggested a hydatidiform mole. For this reason, a quantitative serum β hCG was ordered which revealed the elevated value.

It is important for clinicians in the emergency department to be aware of the 'high-dose Hook effect' and to have a high index of suspicion for the diagnosis of molar pregnancy, in order to avoid the catastrophic consequences of delaying patient care.

REFERENCES

- Altieri A, Franceschi S, Ferlay J, Smith J, La Vecchia C. Epidemiology and aetiology of gestational trophoblastic diseases. *Lancet Oncol.* 2003;4:670.
- Berkowitz RS, Goldstein DP. Gestational trophoblastic disease. In: Berek JS editor. *Berek and Novak's gynecology*. 14th ed. Philadelphia: Lippincott, Williams, and Wilkins; 2007. p. 1581-603.
- O'Reilly SM, Rustin GJ. Mismanagement of choriocarcinoma due to false low HCG measurement. *Int J Gynecol Cancer.* 1993;3:186-8.
- Hunter CL, Ladde J. Molar pregnancy with false negative β hCG urine in the emergency department. *West J Emerg Med.* 2011;2:213-5.
- Salvi A, Mital P, Shekhawat U, Batar A, Makkar P, KumarSoni P. Molar pregnancy with false negative urine β hCG: Hook effect in molar pregnancy. *Int J Pharm Med Res.* 2014;2:134-5.
- Er TK, Tsai LY, Ginds RM. Quantitative human chorionic gonadotrophin measurement in urine using the access immunoassay. *Am J Emerg Med.* 2008;26:103-4
- Coukos G, Makrigiannakis A, Chung J, Randall TC, Rubin SC, Benjamin I. Complete hydatidiform mole. A disease with a changing profile. *J Reprod Med.* 1999;44:698-704.

PROTECTION OF HUMANS AND ANIMALS

The authors declare that the procedures were followed according to the regulations established by the Clinical Research and Ethics Committee and to the Helsinki Declaration of the World Medical Association.

DATA CONFIDENTIALITY

The authors declare having followed the protocols in use at their working center regarding patients' data publication. Informed consent was duly obtained from the patient.

CONFLICTS OF INTEREST

All authors report no conflict of interest.

FUNDING SOURCES

This research received no specific grant from any funding agency in the public, commercial, or not-for-profit sectors.

Tratamento Endovascular de Rotura de Pseudoaneurisma da Artéria Gastroduodenal após Acidente de Viação

Endovascular Treatment of a Gastroduodenal Artery Pseudoaneurysm Rupture after a Car Accident



Sofia DUTRA^{1,2}, Filipe Veloso GOMES², Tiago BILHIM^{2,3}, Élia COIMBRA²
 Acta Med Port 2017 Sep;30(9):658-661 • <https://doi.org/10.20344/amp.8561>

RESUMO

Os autores apresentam o caso de um homem de 39 anos de idade, com antecedentes de pancreatite crónica alcoólica, que foi admitido no serviço de Urgência na sequência de um acidente de viação. À entrada apresentava-se pálido, com dor abdominal, e hemodinamicamente instável, com necessidade de transfusões de sangue. Realizou angio-tomografia computadorizada abdomino-pélvica, que mostrou um pseudoaneurisma da artéria gastroduodenal e hemoperitонеu. Foi referenciado à unidade de Radiologia de Intervenção do nosso centro hospitalar e submetido a tratamento endovascular, que consistiu na embolização 'backdoor' e 'frontdoor' da artéria gastroduodenal e do colo do pseudoaneurisma com coils, obtendo-se exclusão total nas angiografias de controlo. Com a descrição deste caso pretende-se destacar a raridade das roturas de pseudoaneurismas da artéria gastroduodenal e enfatizar a importância da radiologia de intervenção, que desempenhou um papel fundamental no tratamento endovascular, em contexto de urgência, permitindo o controlo da lesão.

Palavras-chave: Acidentes de Trânsito; Artérias; Duodeno; Estômago; Falso Aneurisma; Procedimentos Endovasculares; Ruptura Espontânea

ABSTRACT

The authors present a case of a 39-year-old man with alcoholic chronic pancreatitis that was admitted in the emergency department after a car accident, complaining of abdominal pain and looking pale. The patient was hemodynamically unstable, requiring blood

1. Serviço de Imagiologia. Hospital do Divino Espírito Santo de Ponta Delgada. Açores. Portugal.
 2. Unidade de Radiologia de Intervenção. Centro Hepato-Bilio-Pancreático e de Transplantação. Hospital Curry Cabral. Centro Hospitalar de Lisboa Central. Lisboa. Portugal.
 3. Departamento de Radiologia. Faculdade de Ciências Médicas. Universidade NOVA de Lisboa. Lisboa. Portugal.
 ✉ Autor correspondente: Sofia Dutra. Sofiadutra@hotmail.com

Recebido: 11 de dezembro de 2016 - Aceite: 11 de julho de 2017 | Copyright © Ordem dos Médicos 2017

