

# Foreign Bodies in Pediatrics: A Case to Say “Hello Kitty”

## Corpos Estranhos em Pediatria: Um Caso para Dizer “Hello Kitty”



Marlene RODRIGUES<sup>✉1</sup>, Liliana ABREU<sup>1</sup>  
Acta Med Port 2017 Sep;30(9):663-663 • <https://doi.org/10.20344/amp.9189>

**Keywords:** Accidents; Child; Foreign bodies

**Palavras-chave:** Acidentes; Corpos Estranhos; Criança

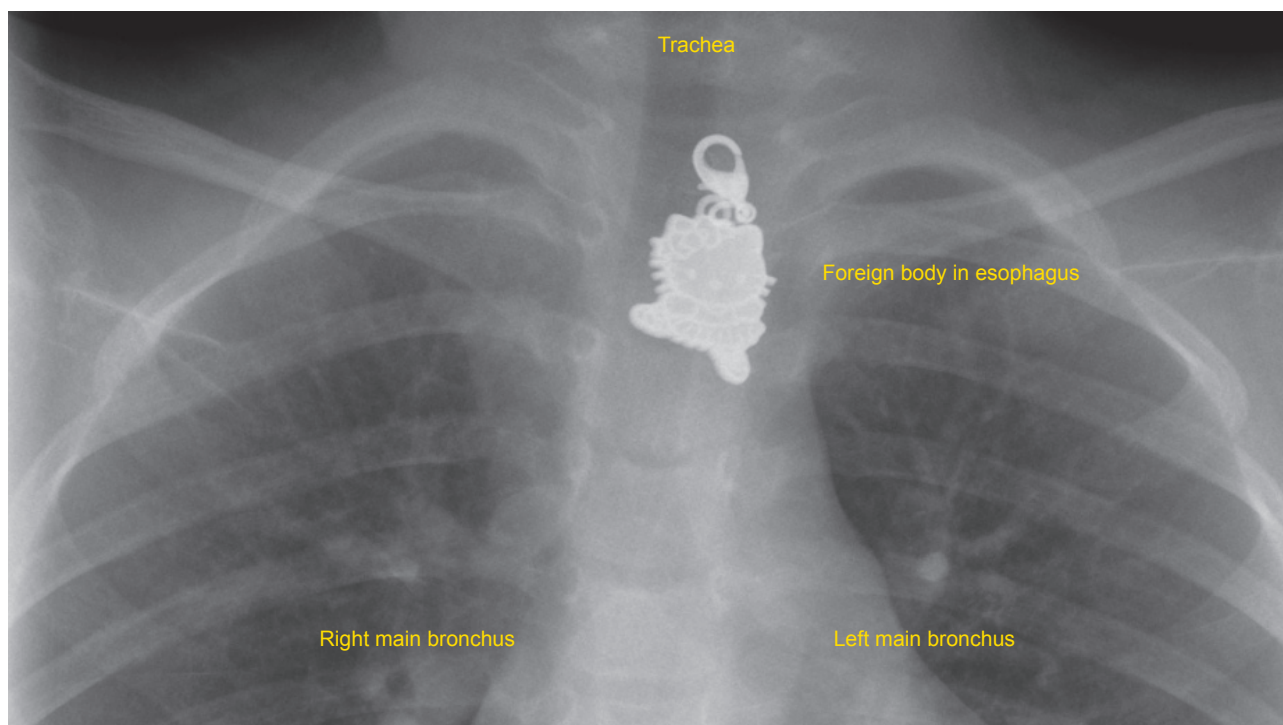


Figure 1 – Thorax plain-film radiography showing pendant necklace in the upper third of esophagus

A 7-year-old Chinese girl was admitted to our emergency department with dysphagia, sialorrhea and paroxysmal cough after ingestion of a foreign body. On physical examination she was thermodynamically stable, with no signs of respiratory distress and an oxygen saturation of 100%. A plain-film radiography of the thorax was performed, and a ‘Hello Kitty’ pendant necklace was recognised in the upper third of her esophagus. Removal of the foreign body was performed endoscopically, without intercurrents. The girl presented full recovery with no sequels.

Foreign body ingestion and aspiration is a frequent cause of pediatric accidents and requires immediate recognition as well as early treatment to minimize potentially

serious consequences.<sup>1-3</sup> More commitment and dedication is needed to ensure adequate prevention by caregivers, which requires parent educational programs in order to prevent habits that predispose to accidents. Prevention is a key element in reducing the morbidity and mortality associated with these cases.<sup>1-3</sup>

### DATA CONFIDENTIALITY

Informed consent was duly obtained from the patient.

### CONFLICTS OF INTEREST

All authors report no conflict of interest.

### REFERENCES

1. Uyemura MC. Foreign body ingestion in children. *Am Fam Physician*. 2005;72:287-91.
2. Rebelo J, Campos TA, Gonçalves A, Trindade E, Dias JA. Onde está o corpo estranho? Dois casos clínicos. *Acta Pediatr Port*. 2012;43:21-3.
3. Dereci S, Koca T, Serdaroğlu F, Akçam M. Foreign body ingestion in children. *Turk Pediatri Ars*. 2015;50:234-40.

1. Pediatrics Department. Hospital de Braga. Braga. Portugal.

✉ Autor correspondente: Marlene Rodrigues. [rodrigues.f.marlene@gmail.com](mailto:rodrigues.f.marlene@gmail.com)

Recebido: 13 de maio de 2017 - Aceite: 14 de agosto de 2017 | Copyright © Ordem dos Médicos 2017

